

Enfermedad de Crohn vs TBC: un eterno dilema

William Otero R MD, FAGA, FACP

Profesor Titular de Medicina

Universidad Nacional de Colombia

Hospital Universitario Nacional de Colombia



E.Crohn vs TBC

```
graph TD; A[E.Crohn vs TBC] --> B[Problema clínic desafiante]; B --> C[Países TBC endèmica]; B --> D[Países con aumento Incidencia EC];
```

Problema clínic desafiante

Países TBC endèmica

**Países con aumento
Incidencia EC**

**Enfermedad de Crohn
Tuberculosis intestinal
Granulomatosas**

Similitud

```
graph TD; A[Similitud] --> B[Clínica]; A --> C[Rx]; A --> D[Histología]; A --> E[Endoscopia];
```

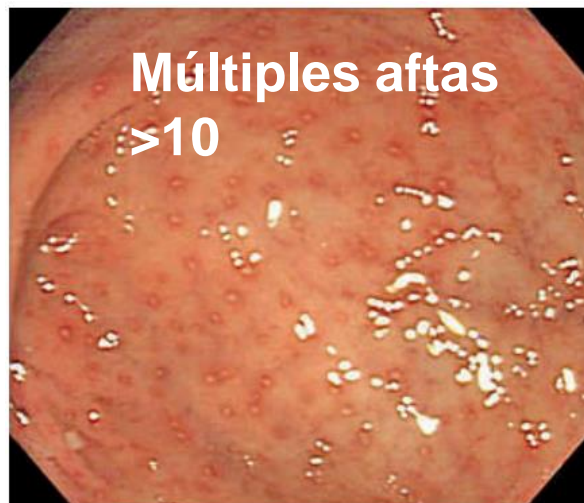
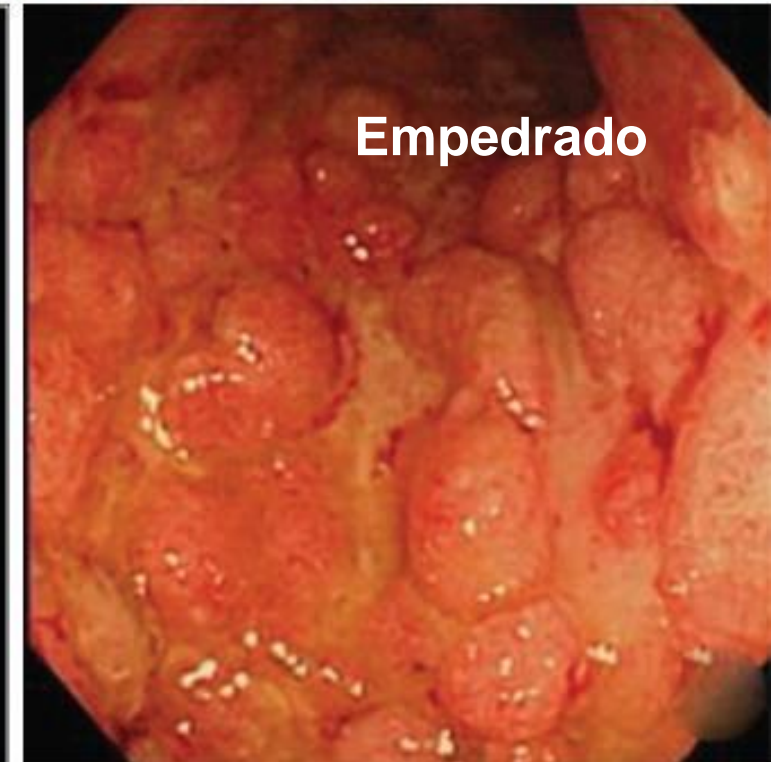
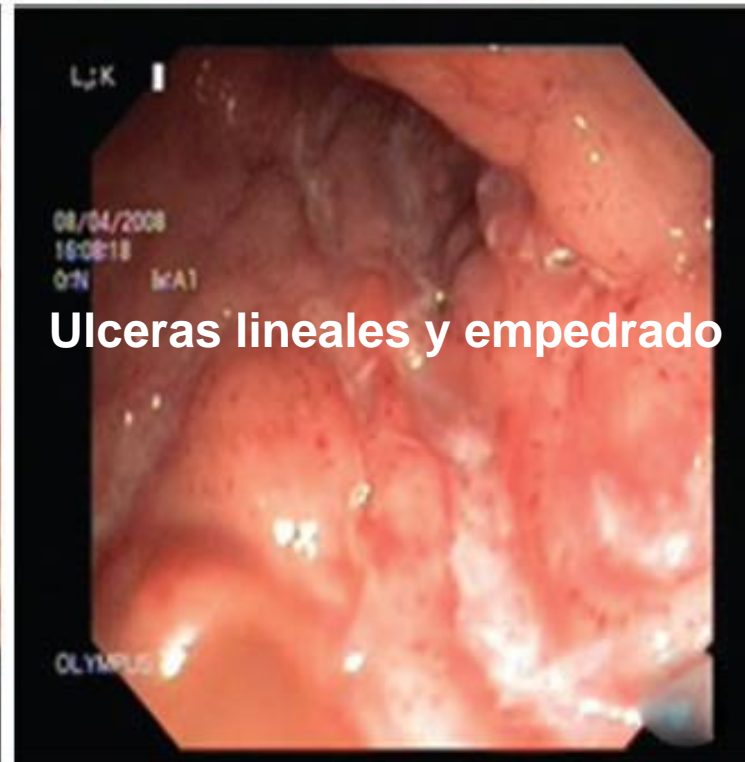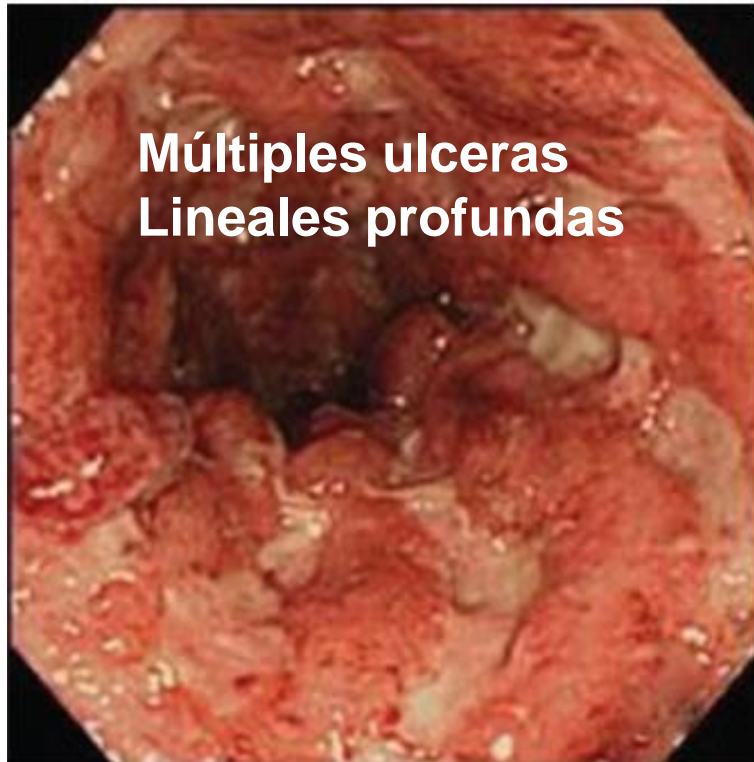Clínica

Rx

Histología

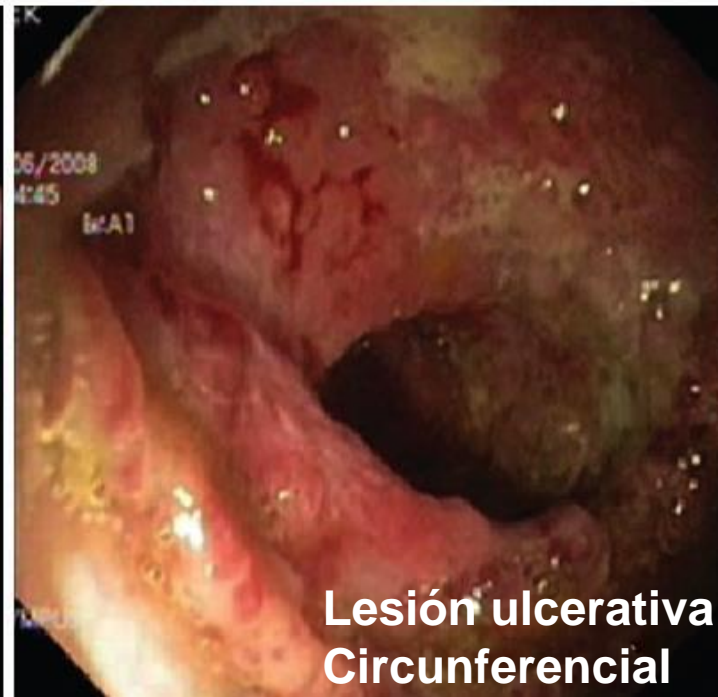
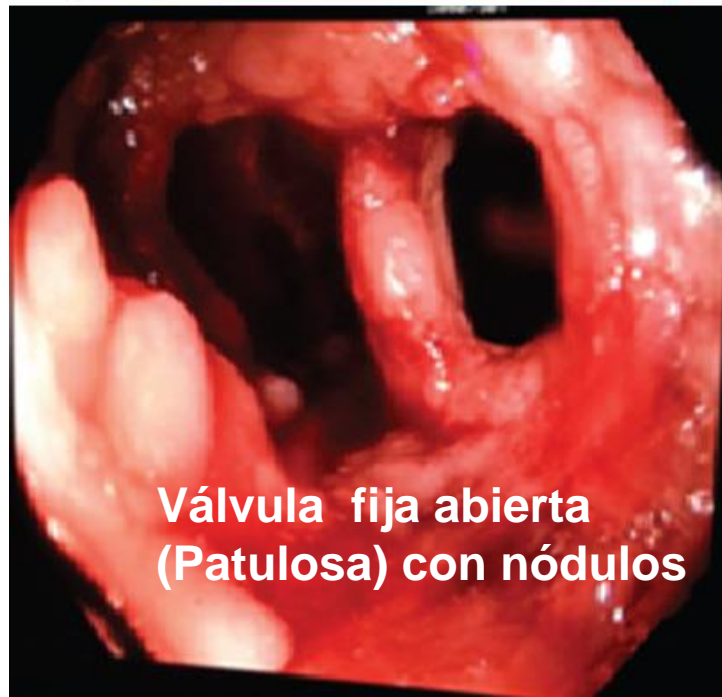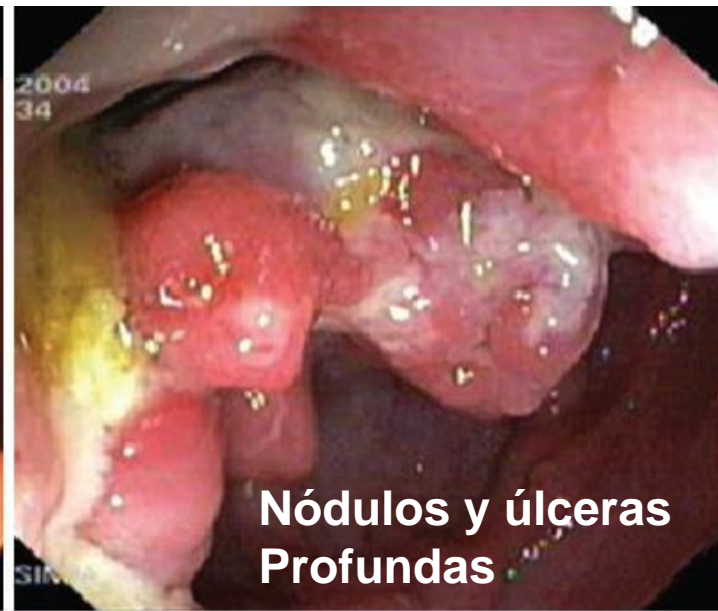
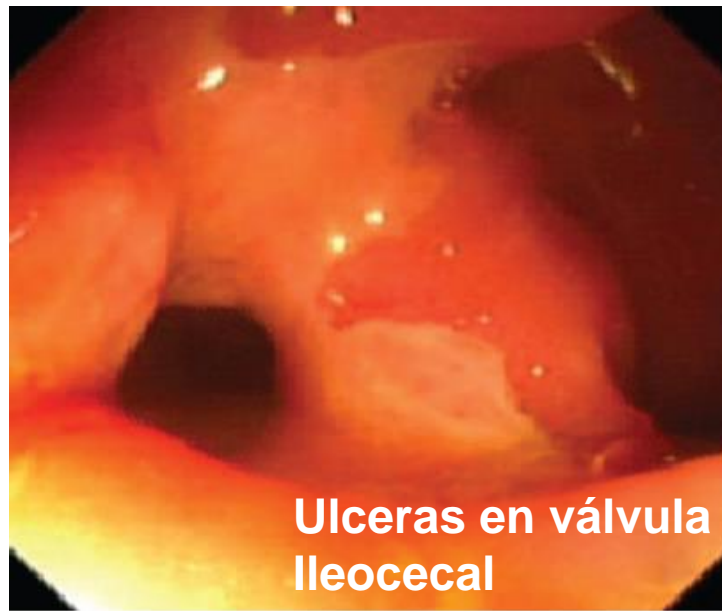Endoscopia

E de Crohn

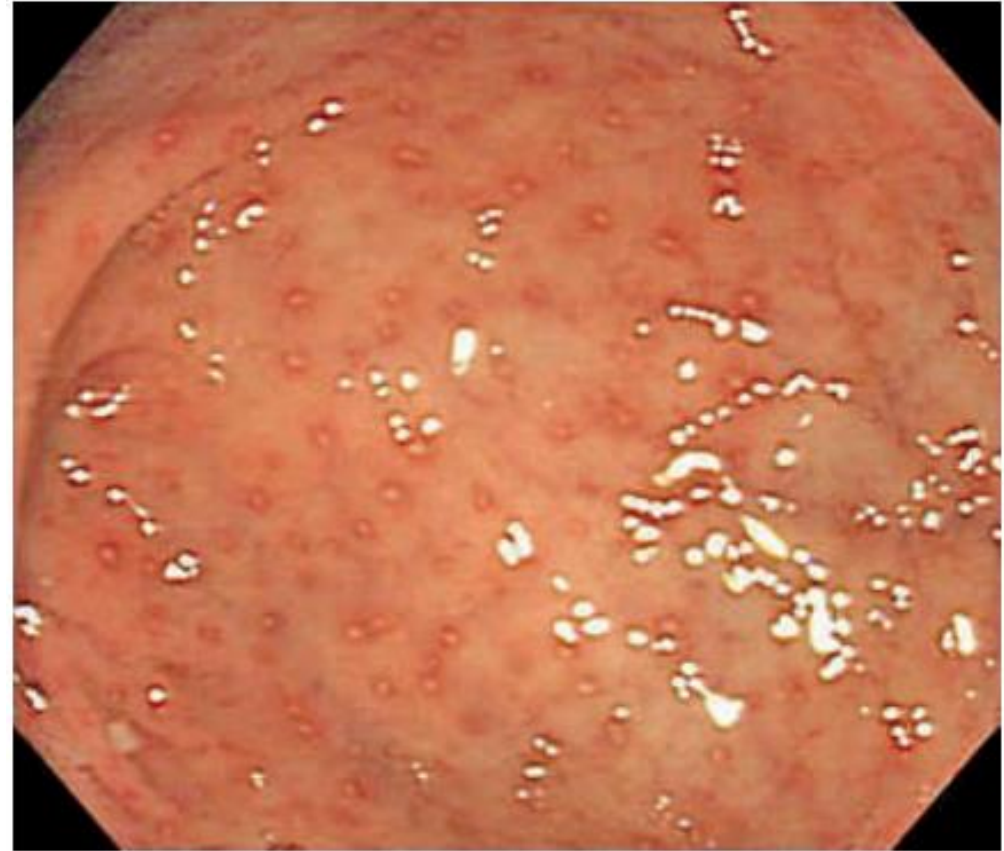
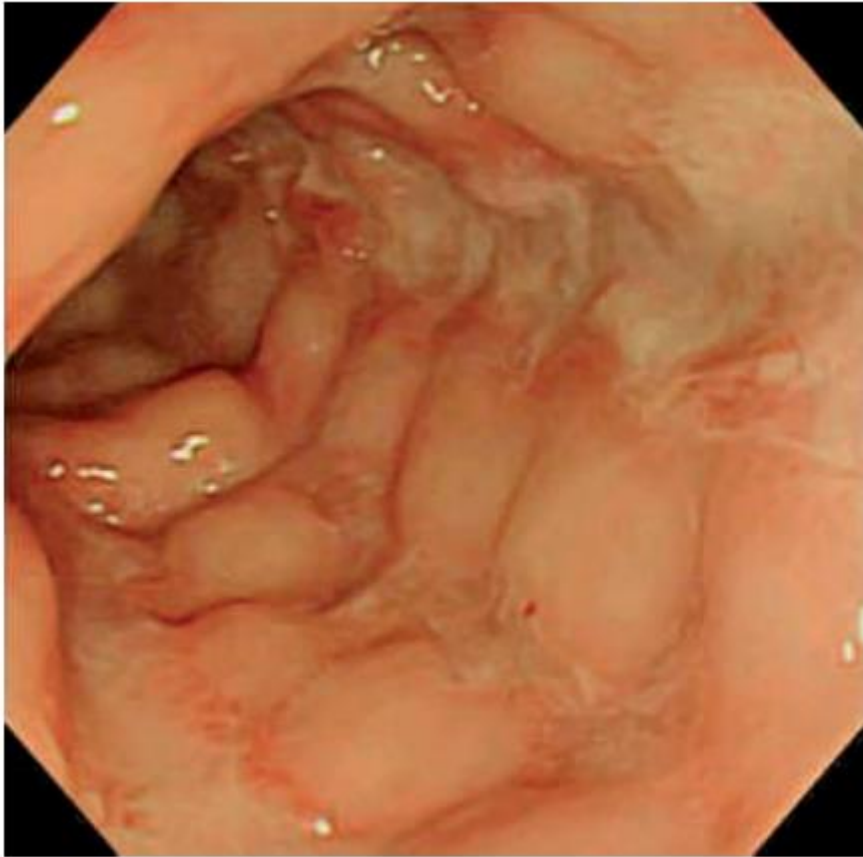
Moka P, J Dig Endosc 2017;8:1-11.

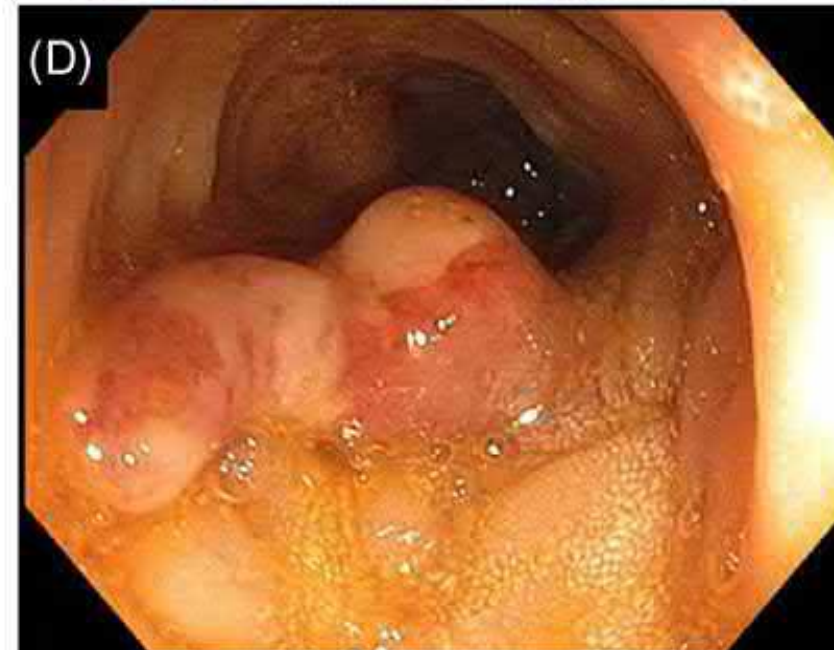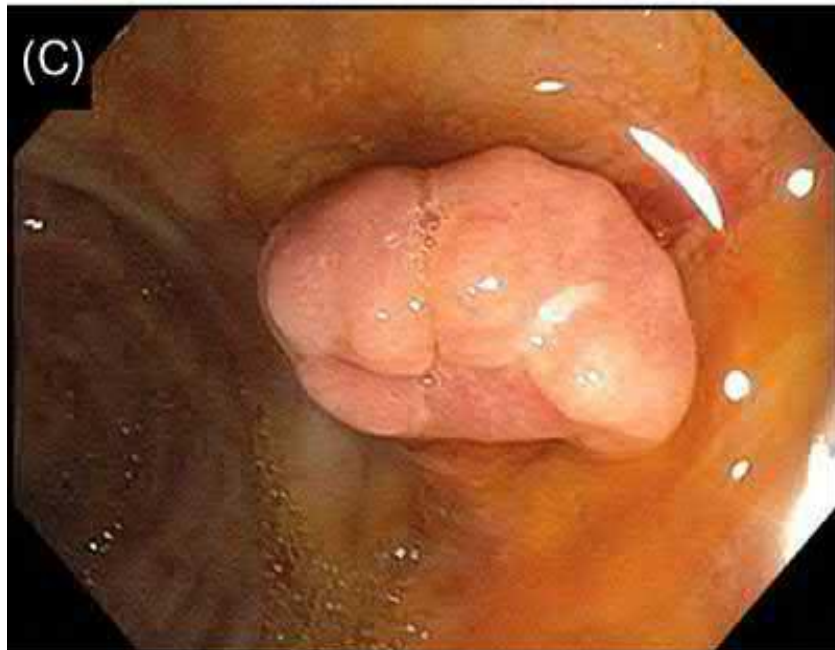
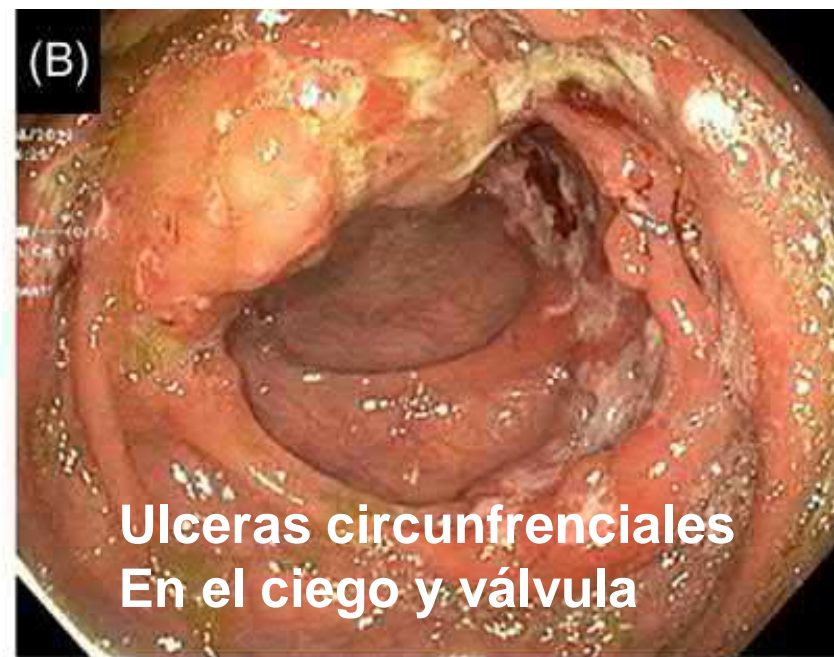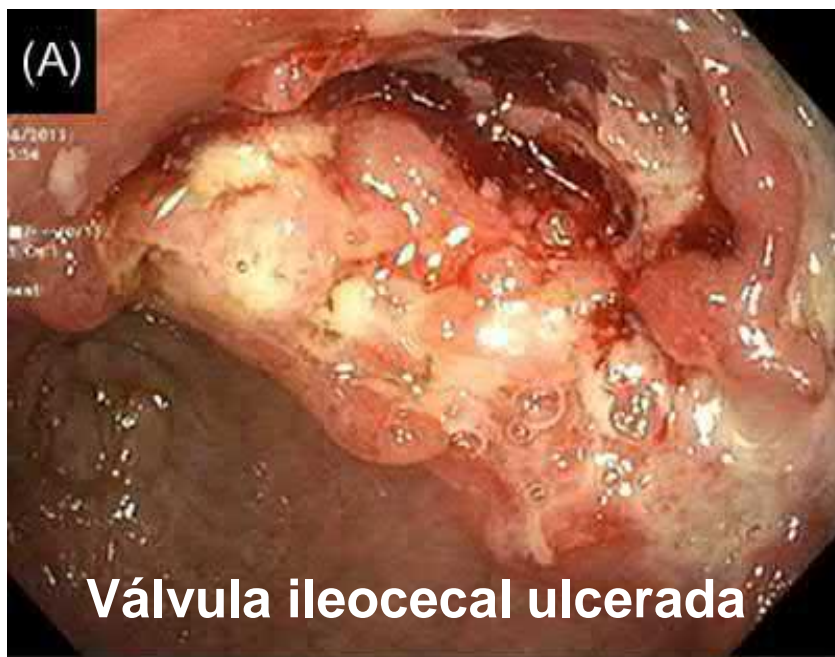TBC



E de Crohn lo más típico

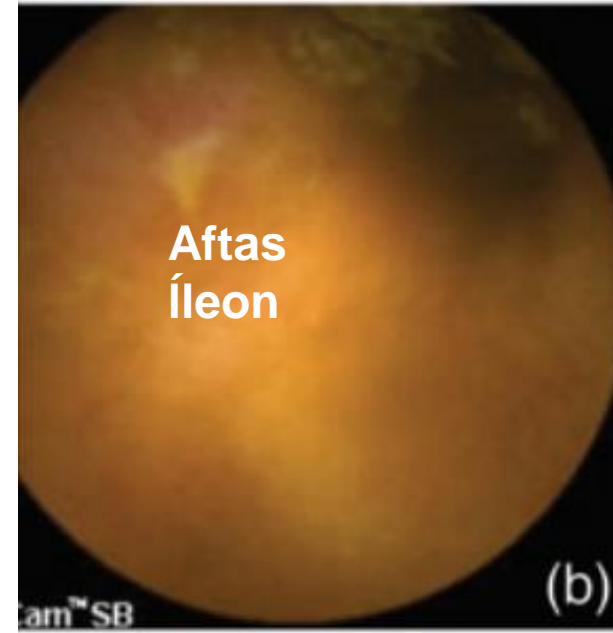
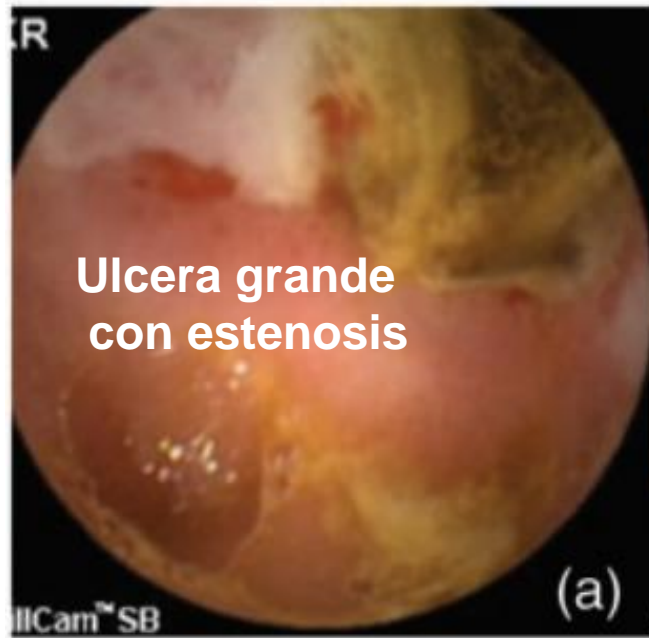

TBC

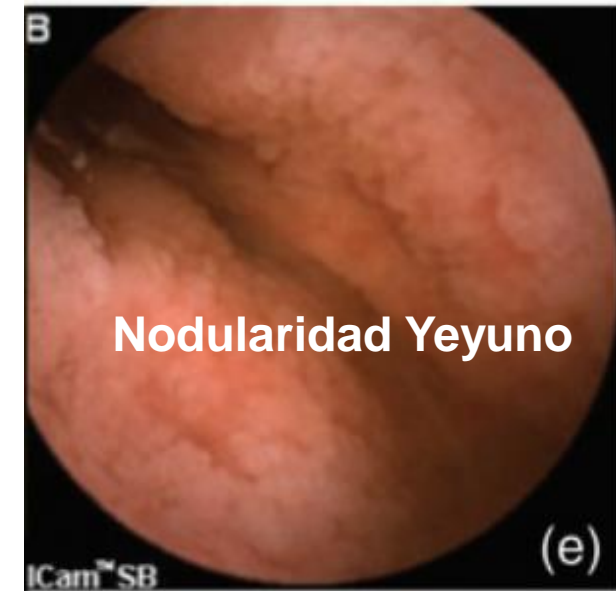
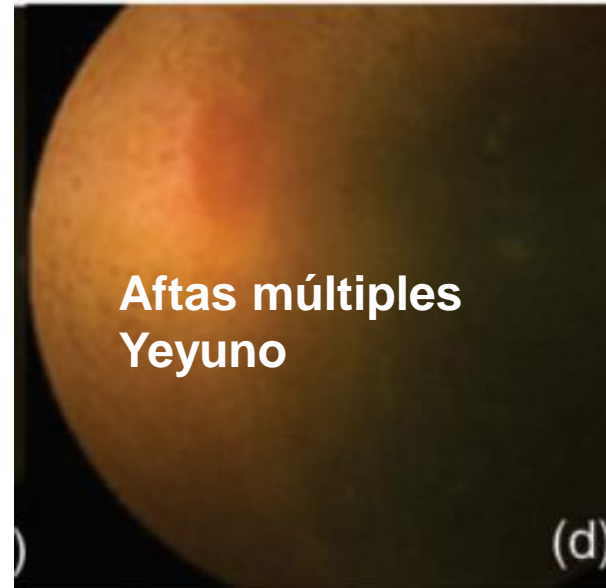
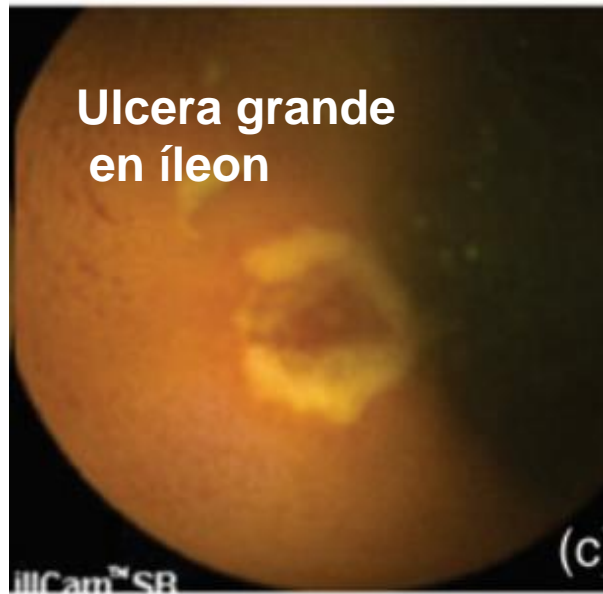

Videocápsula

TBC-ID



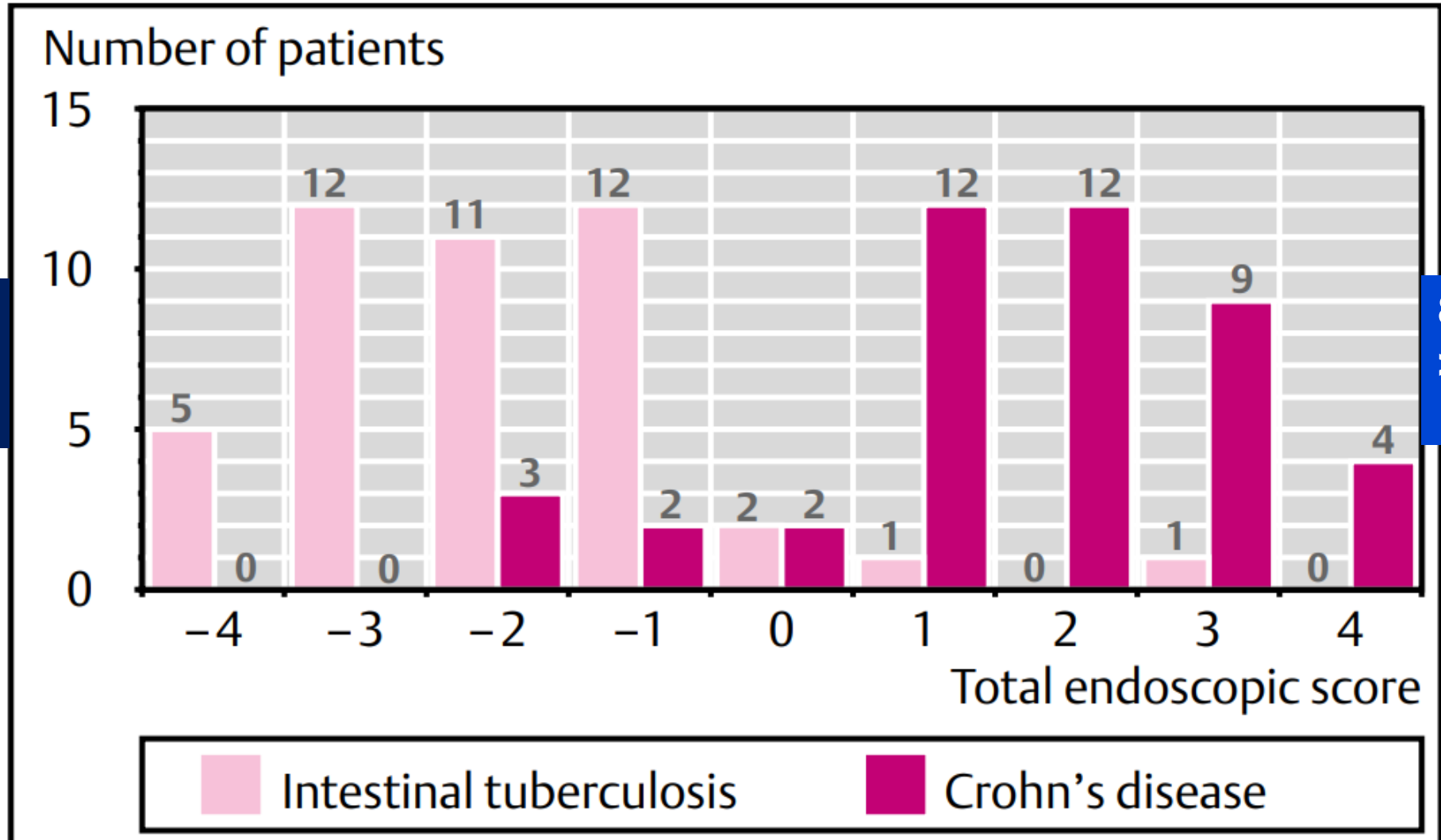
EC



(-1) (cada parámetro de TBC):
Compromiso y Válvula abierta, cicatrices
ulceras transversales, pseudopólipos





+ 1 (cada parámetros de Crohn):
lesiones anorrectales, úlceras longitudinales,
aftas, empedrado

**8 parámetros
< 0 VPP
TBC 89%**

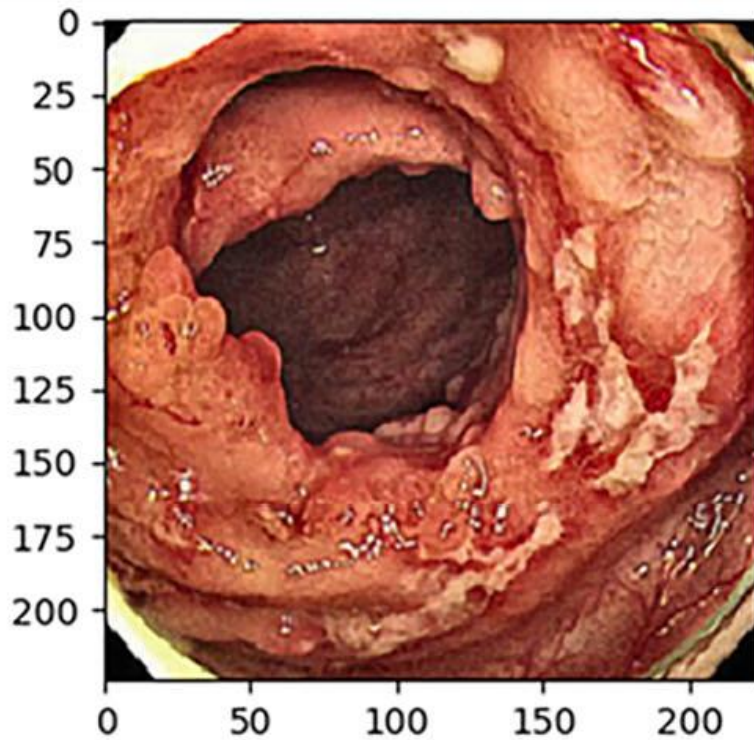


**8 parámetros
> 0 VPP
Crohn 95%**

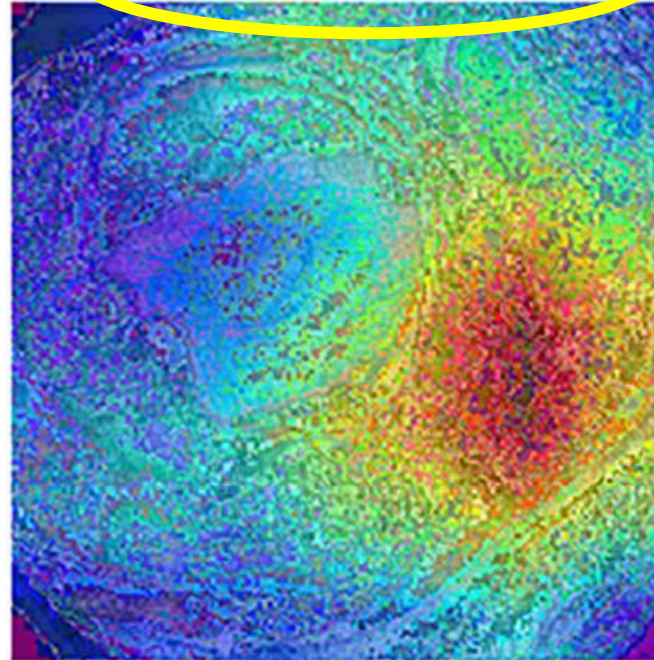
Deep-learning system for real-time differentiation between Crohn's disease, intestinal Behçet's disease, and intestinal tuberculosis

Jung Min Kim,*  Jun Gu Kang,*  Sungwon Kim[†]  and Jae Hee Cheon*^{,‡} 


(c)







tuberculosis: 99.9%



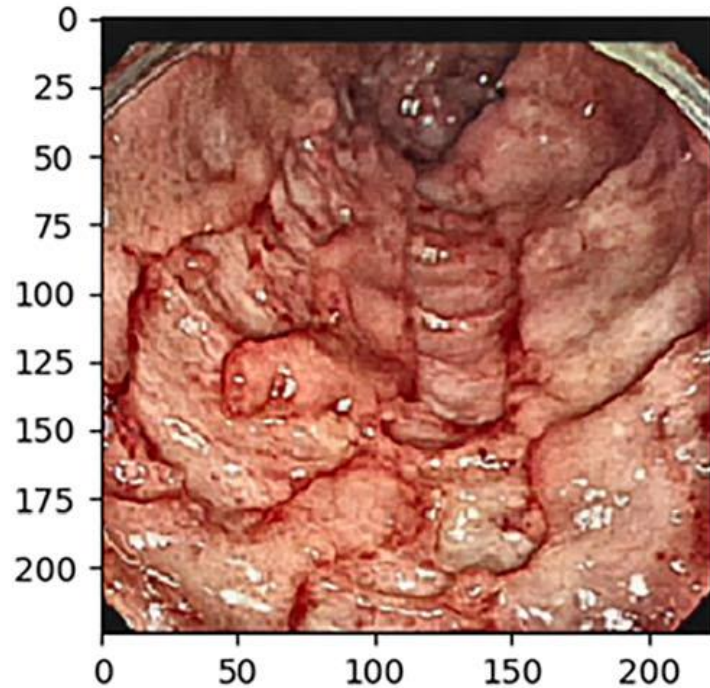
behçet: 0.1%



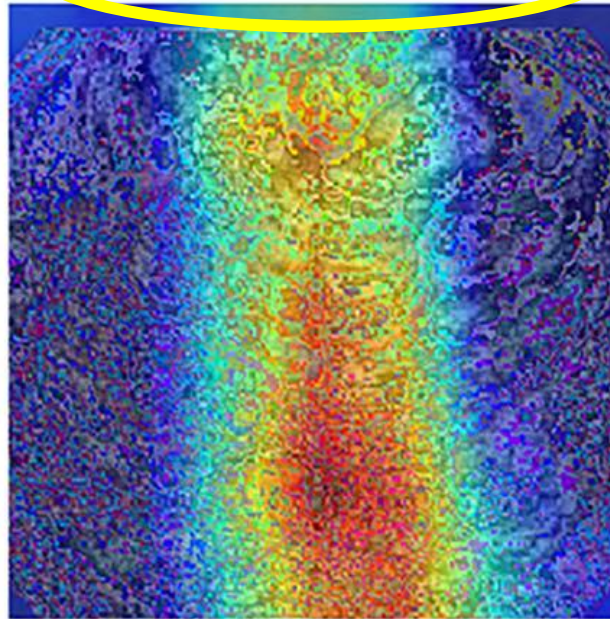
Deep-learning system for real-time differentiation between Crohn's disease, intestinal Behçet's disease, and intestinal tuberculosis

Jung Min Kim,*  Jun Gu Kang,*  Sungwon Kim[†]  and Jae Hee Cheon^{*,‡} 

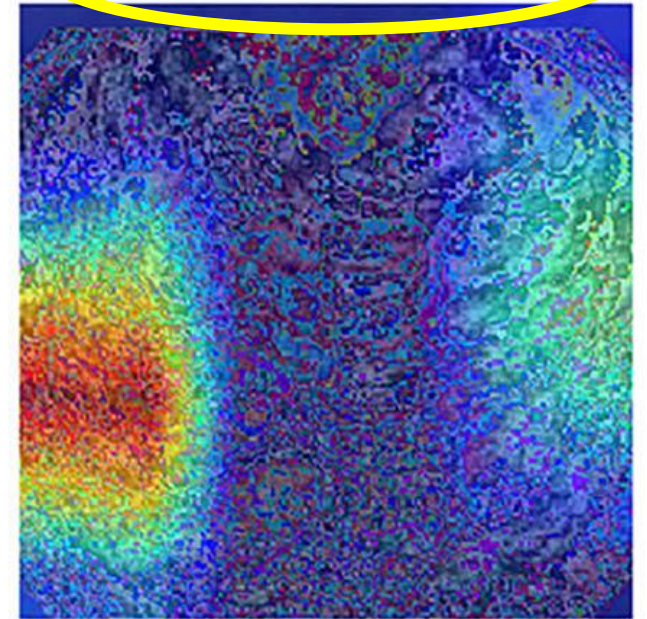
(d)



crohn: 69.2%



tuberculosis: 30.8%



Observational Study

Temporal trends in the misdiagnosis rates between Crohn's disease and intestinal tuberculosis

Hyungil Seo, Seohyun Lee, Hoonsub So, Donghoi Kim, Seon-Ok Kim, Jae Seung Soh, Jung Ho Bae, Sun-Ho Lee, Sung Wook Hwang, Sang Hyoung Park, Dong-Hoon Yang, Kyung-Jo Kim, Jeong-Sik Byeon, Seung-Jae Myung, Suk-Kyun Yang, Byong Duk Ye

18% EC**11% TBC****Diagnosticados inicialmente TBC****Diagnosticados inicialmente EC****Mal tratamiento de TBC****Inmunosupresión: esteroides, Anti TNF****Empeoramiento****Diseminación TBC****Mal tratamiento EC****Progresión****Formación estenosis****Hepatotoxicidad**

TBC vs E Crohn



Modelos predictivos


Clinica

Endoscopia

Patologia

Radiología

Laboratorio



Sensibilidad

Especificidad

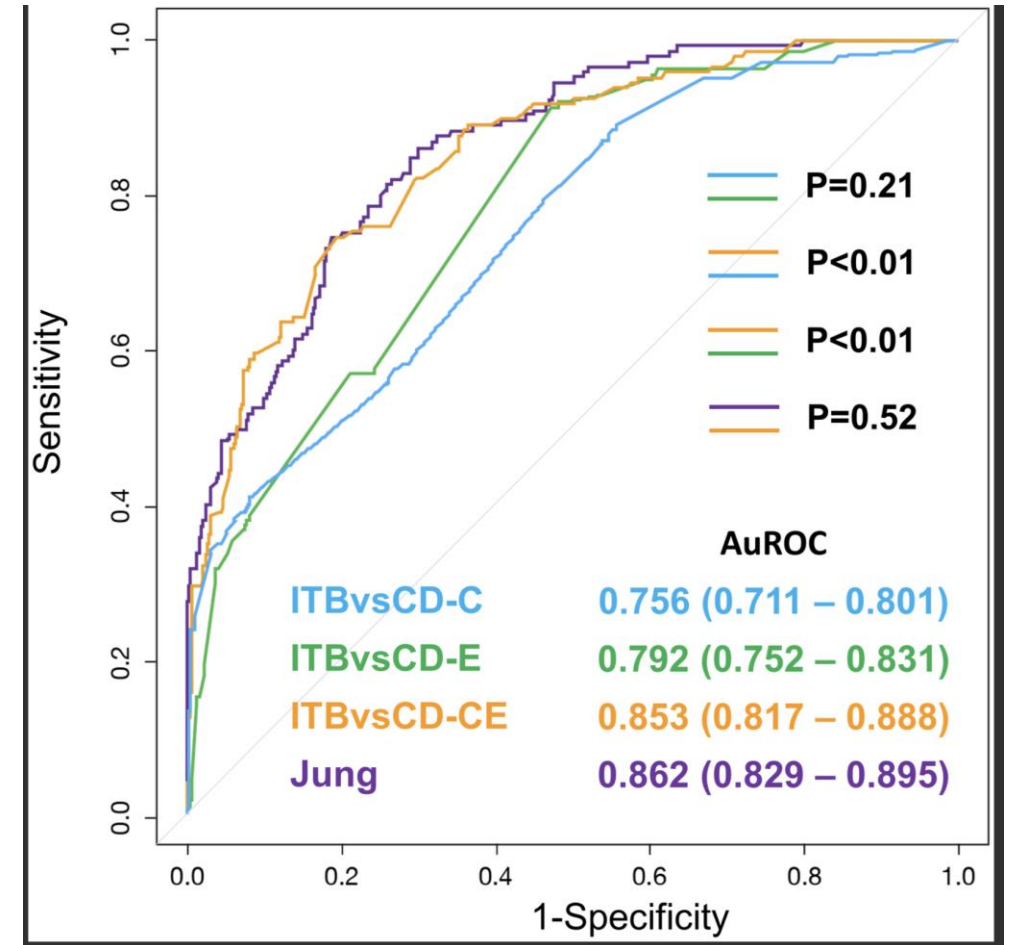
AUROC

RESEARCH ARTICLE

Validation of models using basic parameters to differentiate intestinal tuberculosis from Crohn's disease: A multicenter study from Asia

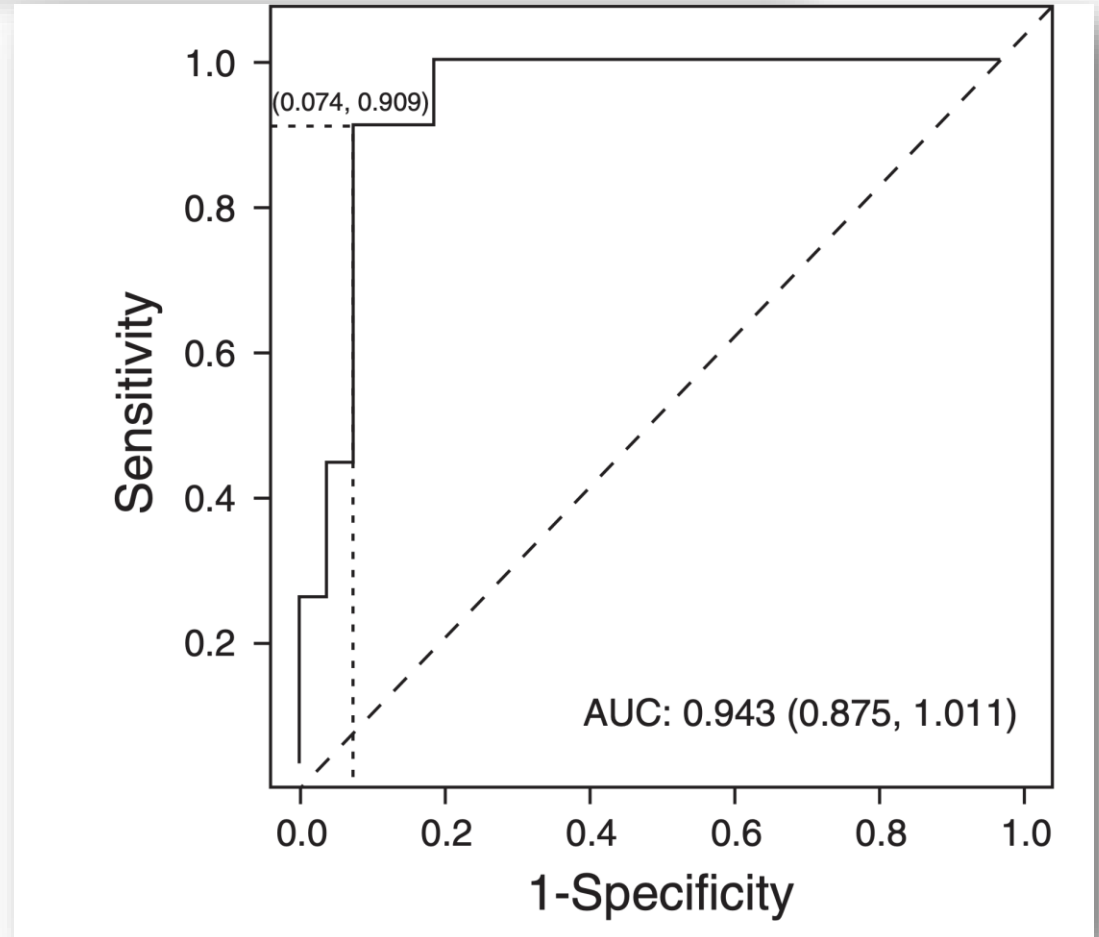
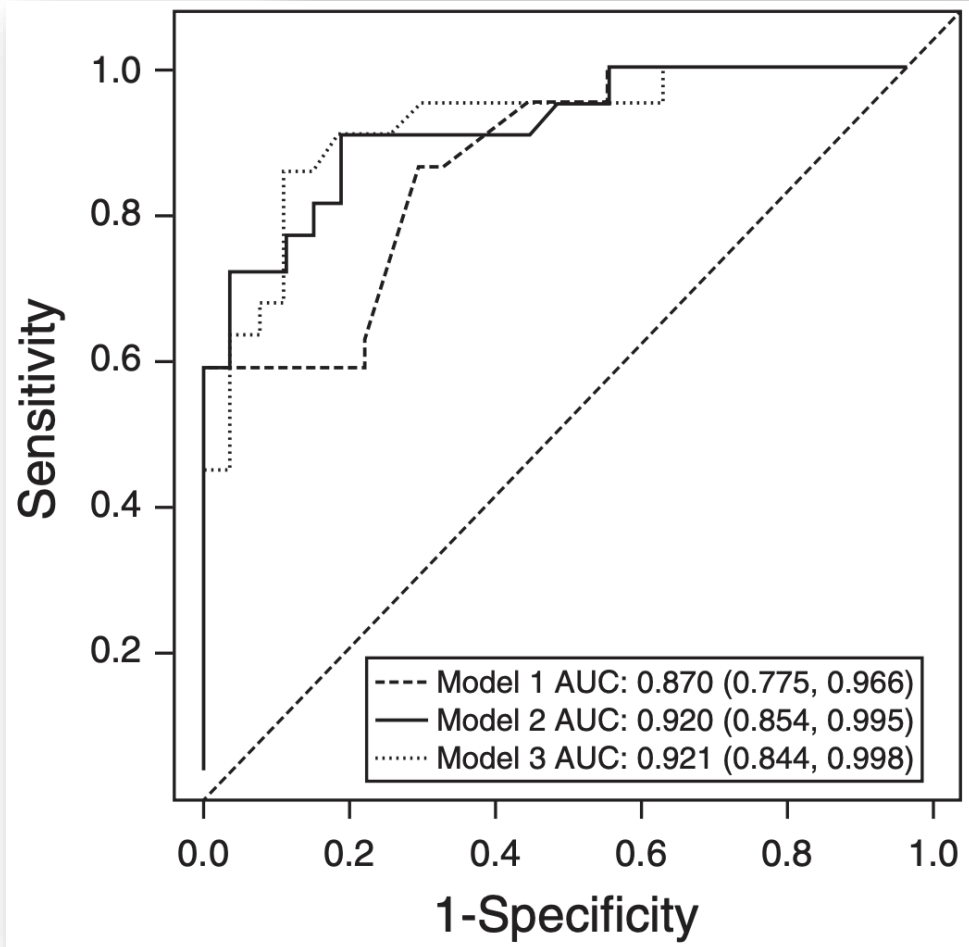
Julajak Limsrivilai^{1,2}, Choon Kin Lee³, Piyapan Prueksapanich⁴, Kamin Harinwan⁵, Asawin Sudcharoen¹, Natcha Cheewasereechon⁶, Satimai Aniwat⁴, Pimsiri Sripongpan⁶, Panu Wetwittayakhleng⁶, Ananya Pongpaibul⁷, Anapat Sanpavat⁸, Nonthalee Pausawasdi¹, Phunchai Charatcharoenwitthaya¹, Peter D. R. Higgins², Siew Chien Ng^{3*}

PLoS One. 2020;15:e0242879.



Meta-Analytic Bayesian Model For Differentiating Intestinal Tuberculosis from Crohn's Disease

Julajak Limsrivilai, MD^{1,2}, Andrew B. Shreiner, MD, PhD¹, Ananya Pongpaibul, MD³, Charlie Laohapand, MD², Rewat Boonanuwat, MD², Nonthalee Pausawasdi, MD², Supot Pongprasobchai, MD², Sathaporn Manatsathit, MD² and Peter D.R. Higgins, MD, PhD, MSc¹



Enfermedad de Crohn Tuberculosis intestinal

Microbiología

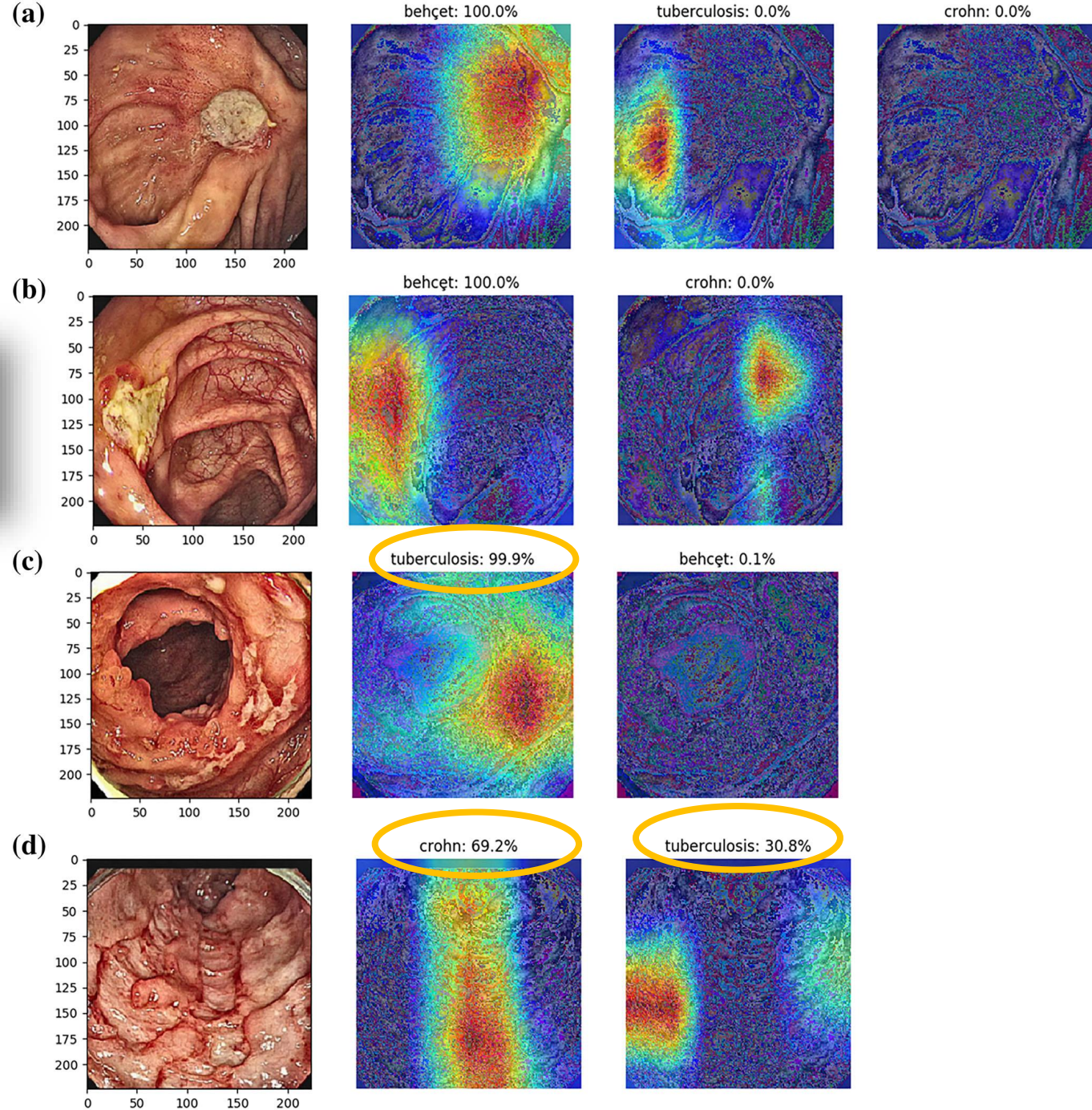
**Pruebas Serológicas,
inmunológicas**

Prueba Terapéutica

Deep-learning system for real-time differentiation between Crohn's disease, intestinal Behçet's disease, and intestinal tuberculosis

Jung Min Kim,*  Jun Gu Kang,*  Sungwon Kim†  and Jae Hee Cheon*[‡] 

Kim JM, J Gastroenterol Hepatol 2021 Feb 7.



Conclusión

Endoscopia, Ulceras

TBC

Circunferenciales
Transversales
Válvula ileocecal abierta
Ciego-Ileon

E. Crohn

Lineales
Aftosas numerosas
Colon izquierdo
Alteración parches
Empedrado

Goyal P, Expert Rev Gastroenterol Hepatol 2019;13:995-1007
Seo H, World J Gastroenterol 2017;23:6306-14
Limsrivilai J, Am J Gastroenterol 2017;112:415-27

Muchas gracias!