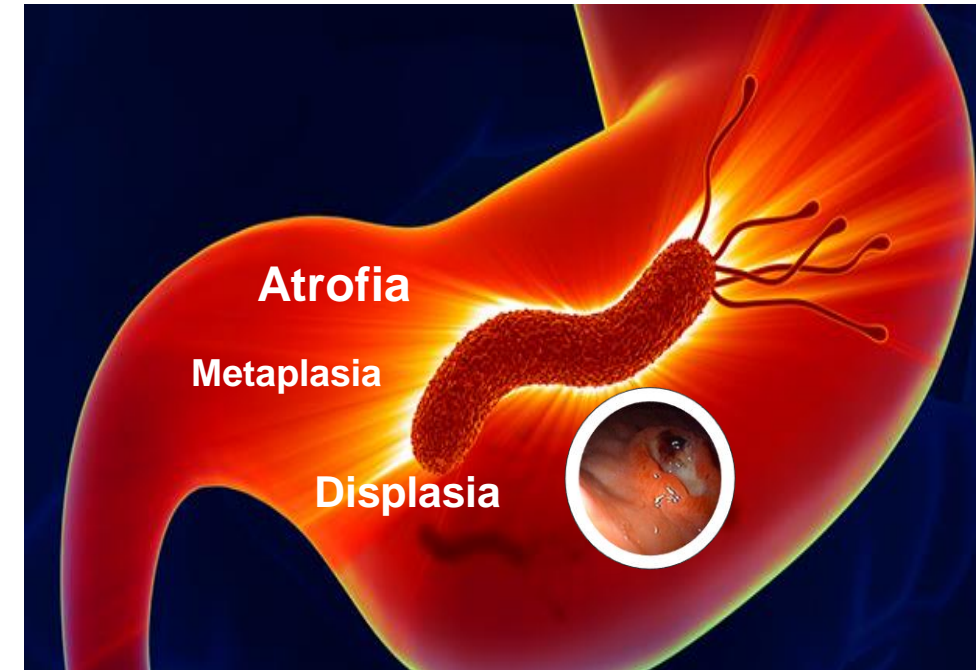

“No *Hpylori* No cáncer”

Atrofia y metaplasia intestinal Condiciones precursoras de cáncer gástrico: qué ¿hacer ?



William Otero MD, FAGA, FASGE, FACP
Profesor Titular de Medicina
Unidad de Gastroenterología
Universidad Nacional de Colombia
Hospital Universitario Nacional de Colombia



Conflicto de intereses
Conferencista, Bristol
Takeda, Abbott, Tecnoquimica
Tecnofarma, Menarini, Procaps

Esta actividad es asuspiciada por
Tecnofarma sin injerencia en su contenido

1938. Profecía de Konjetzny:

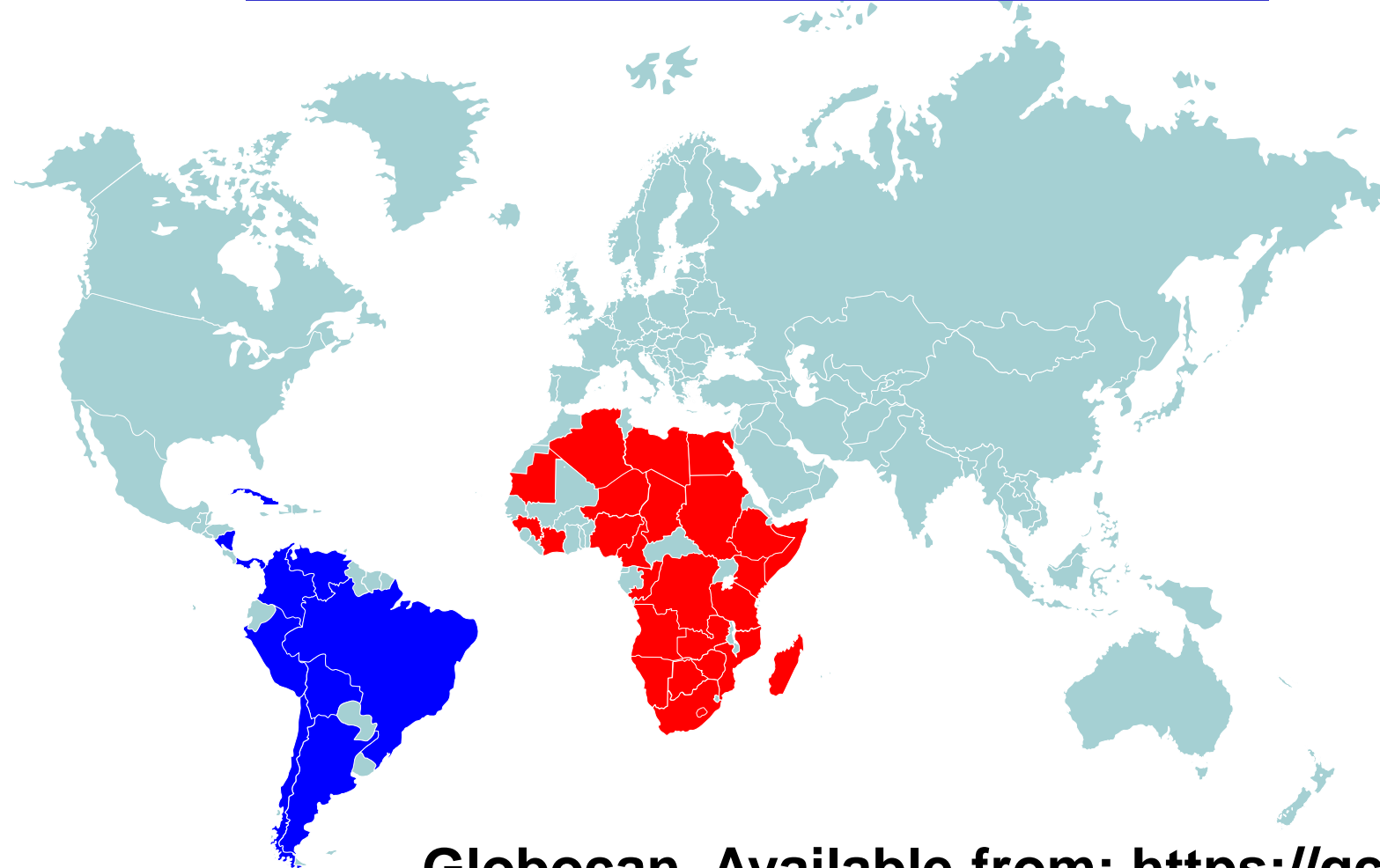**Cirujano alemán pionero de la hipótesis
Actual sobre la etiología del cáncer gástrico**

**“ La ulcera y cáncer gástrico se desarrollan
a través de inflamación silente de la mucosa
y no sabemos cuál gastritis será benigna
y cuál dará cáncer”.**

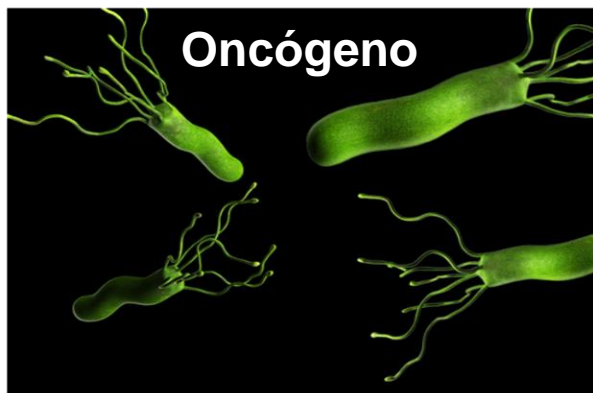
**“Cuando seamos capaces de prevenir o tratar la
gastritis, podremos prevenir la úlcera y el cáncer
gástrico: “la profilaxis contra la gastritis es la
profilaxis contra la ulcera y el cáncer gástrico”**

Cáncer Gástrico

**5^o cáncer más común
3^a causa muerte por cáncer
Llegan avanzados**



Globocan. Available from: <https://gco.iarc.fr/>. 2018



H.pylori
OMS IARC1994/2009
Carcinógeno tipo I

60% mundo
Tiene *H.pylori*

1.220.000 casos
2017
800.000 muertes

1-3%

Riesgo atribuible
Global 85-90%
Japón Korea 90-95%

Graham DY, Gastroenterology 2015;148:719-31
Tsuda M, Helicobacter 2017;e12415

Lancet Gastroenterol Hepatol 2020;5:42-54
Global Burden Disease. JAMA Oncol 2017;3:524-41

Cáncer Gástrico modelo Pelayo Correa

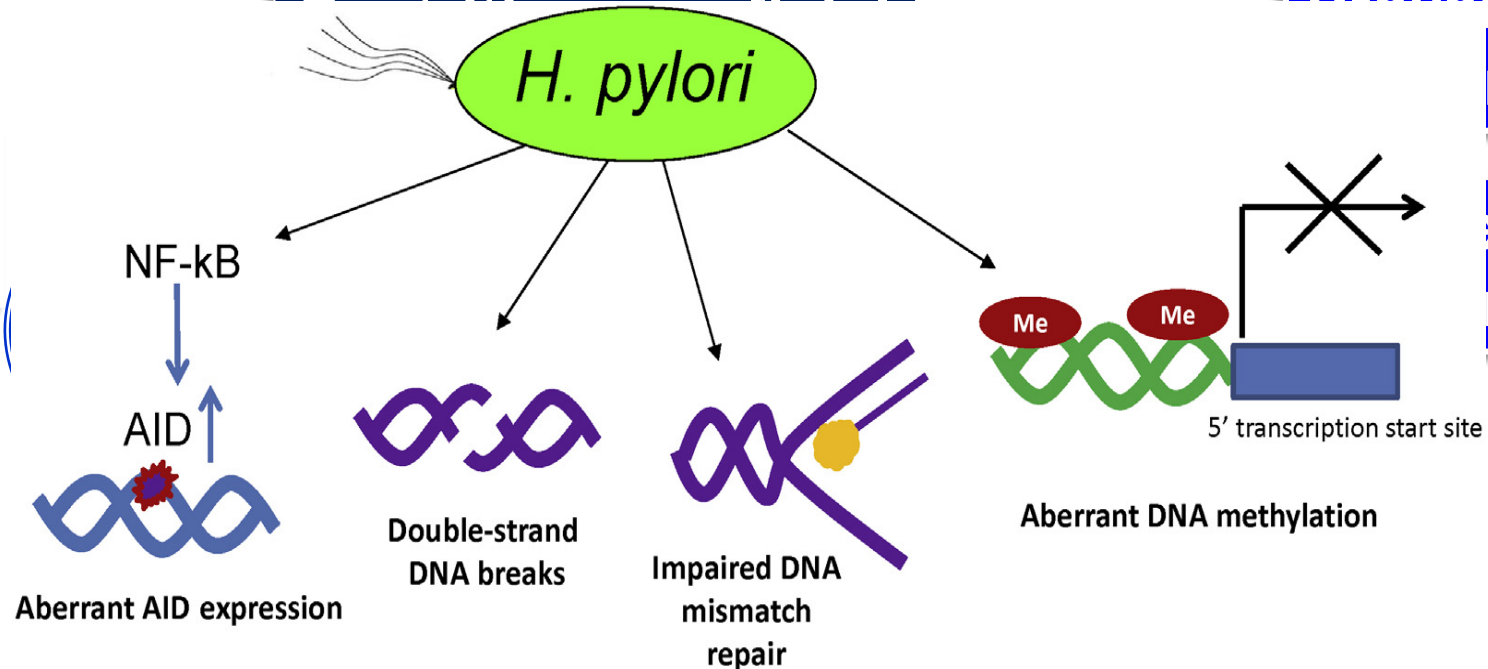


Mucosa sana

~~Helicobacter pylori~~

Prevencción
ria

esis
robada



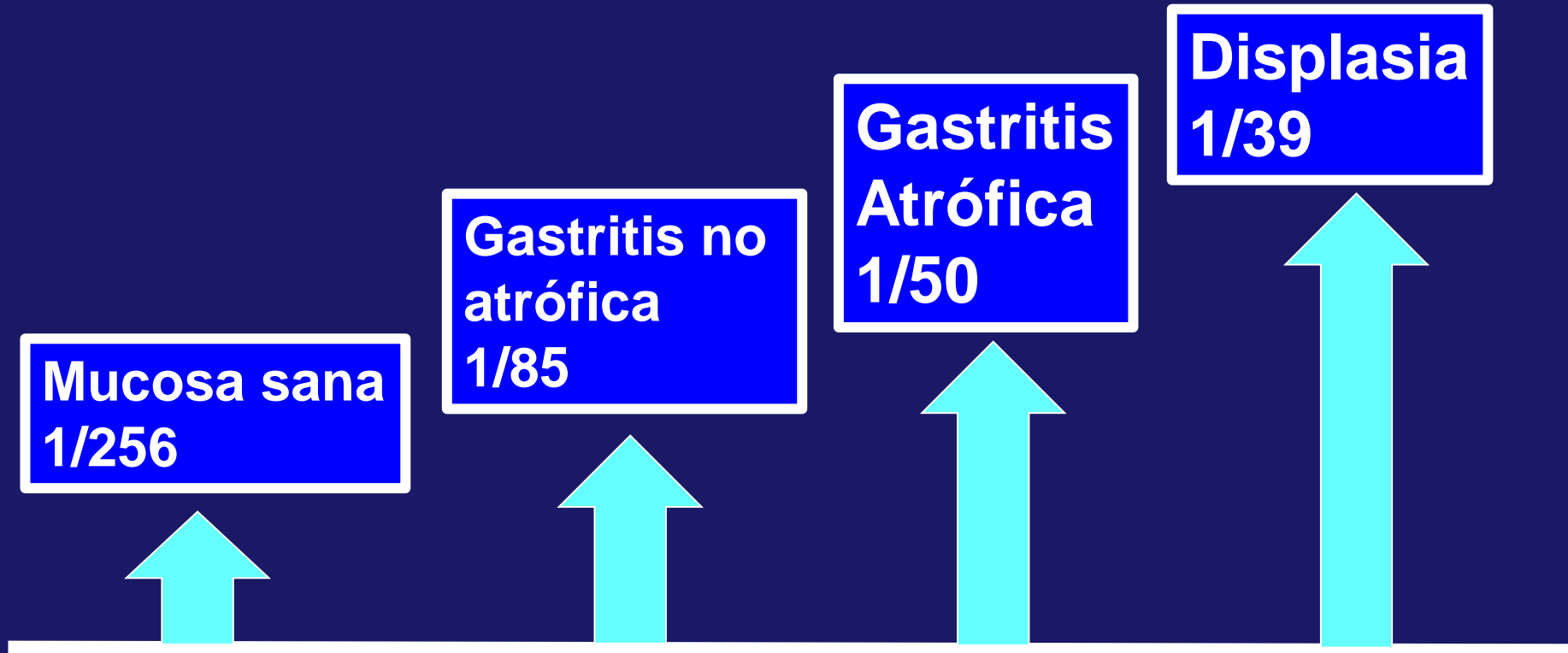
Estratificando
severidad

Vigilancia
Prevencción
Secundaria

Cáncer gástrico

Correa P. Cancer Res 1992; 52:6735–6740
 Correa P. J Dig Dis 2012;13:2-9
 Chen HN, Gastric Cancer 2016;19:166-7

Gastritis crónica-cáncer



Enfoque actual prevenir cáncer gástrico

Endoscopia de rutina

Investigar y erradicar *Helicobacter pylori*

Estratificar el riesgo para cáncer Gástrico

Endoscopios
avanzados

NBI, BLI, CLI
EGGIM

Experiencia del
Endoscopista

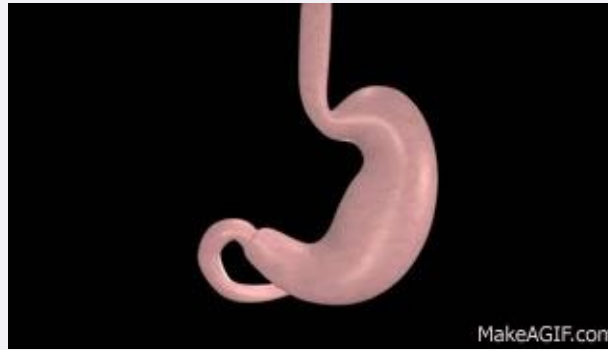Biopsias
Múltiples Sídney

OLGA

OLGIM

Sugano K, Consenso Kyoto Gut. 2015;64:1353-67
Mafertheiner P, Maastricht V. Gut 2017;66:6-30.
Pimentel-Nunes P, Endoscopy 2019;51:365-88

**Condiciones precursoras
De cáncer gástrico**



Biomarcadores

Estómago "premaligno"

"Gastropanel"
PG I, I/II
Anti *Hpylori*



genes



Review

MicroRNA Changes in Gastric Carcinogenesis: Differential Dysregulation during *Helicobacter pylori* and EBV Infection

Christian Prinz ^{1,2,*}, Kemal Mese ^{2,3} and David Weber ^{1,2}

Genes 2021;12:597.

The usefulness of microRNA in urine and saliva as a biomarker of gastroenterological cancer

Isamu Hoshino¹

La ciencia básica de hoy, es
la práctica clínica de mañana

Tadataka Yamada

Argonautes2 (Ago2)-
miRNA complex

Artery

Inteligencia artificial



ELSEVIER

Contents lists available at [ScienceDirect](#)

Digestive and Liver Disease

journal homepage: www.elsevier.com/locate/dld



Digestive Endoscopy

Diagnosing chronic atrophic gastritis by gastroscopy using artificial intelligence

Yaqiong Zhang^{a,1}, Fengxia Li^{b,*}, Fuqiang Yuan^c, Kai Zhang^d, Lijuan Huo^e, Zichen Dong^d, Yiming Lang^d, Yapeng Zhang^f, Meihong Wang^a, Zenghui Gao^a, Zhenzhen Qin^a, Leixue Shen^d



ELSEVIER

Contents lists available at [ScienceDirect](#)

Best Practice & Research Clinical Gastroenterology

journal homepage: <https://ees.elsevier.com/ybega/default.asp>



Artificial intelligence: Thinking outside the box

Gian Eugenio Tontini^{a,b}, Helmut Neumann^{c,*}

^a Gastroenterology and Endoscopy Unit, Fondazione IRCCS Ca' Granda Ospedale Maggiore Policlinico, Milan, Italy

^b Department of Pathophysiology and Transplantation, University of Milan, Milan, Italy

^c Department of Interdisciplinary Endoscopy, University Hospital Mainz, Mainz, Germany

Prevención secundaria

**Mundo
Real**



**Identificar y vigilar
Condiciones precursoras de CG
Atrofia –Metaplasia-Displasia**

Gastritis crónica

1990: Sidney

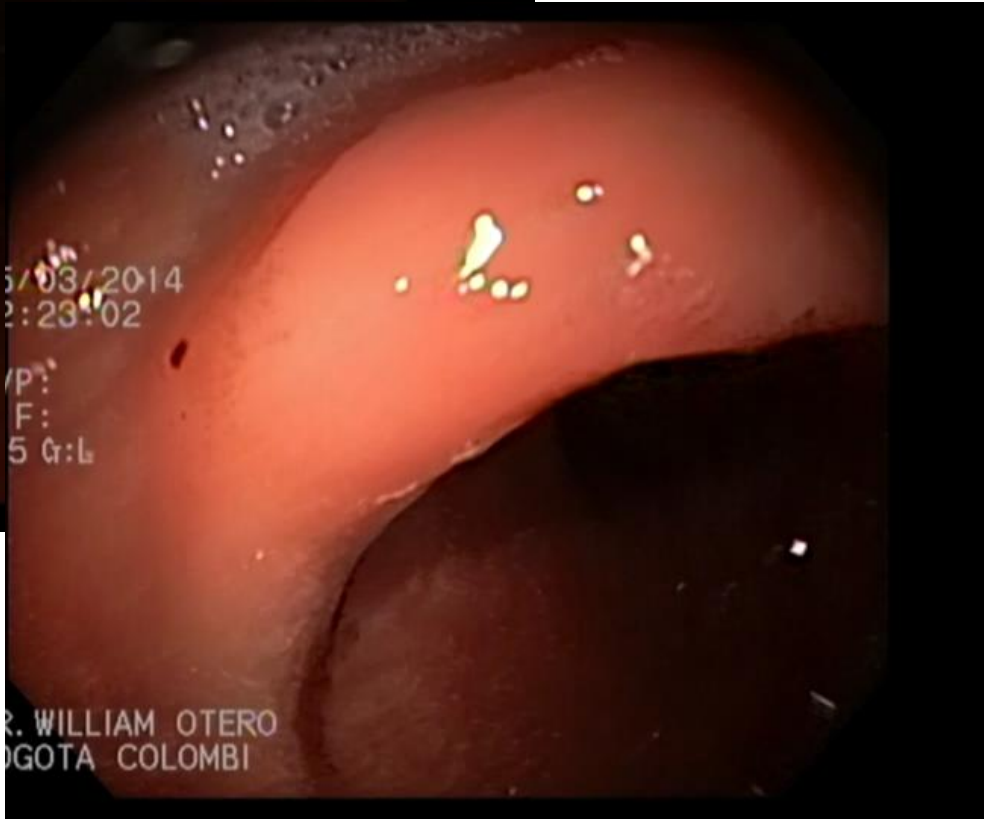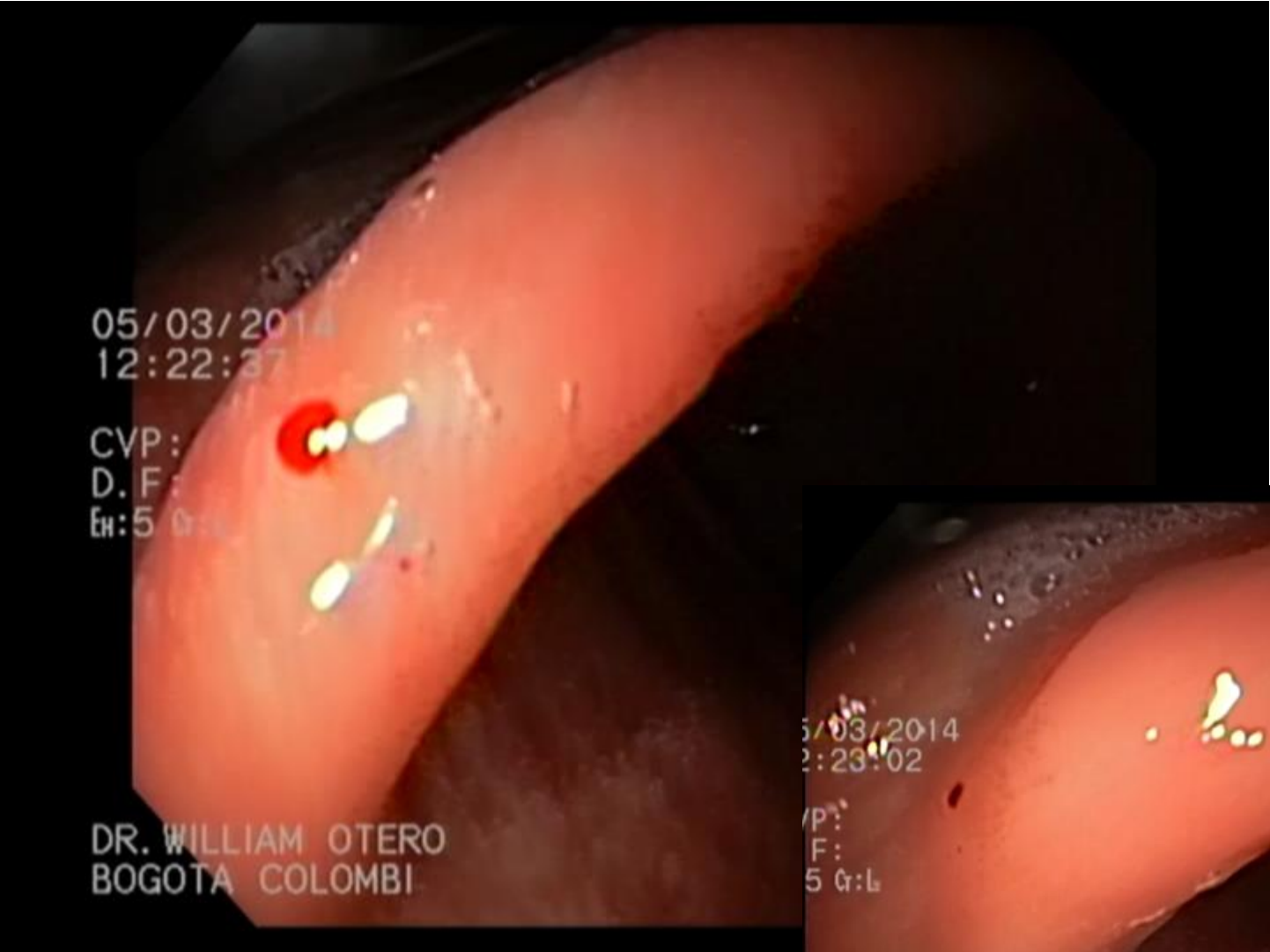1997: Sídney actualizado, **biopsia de la incisura**



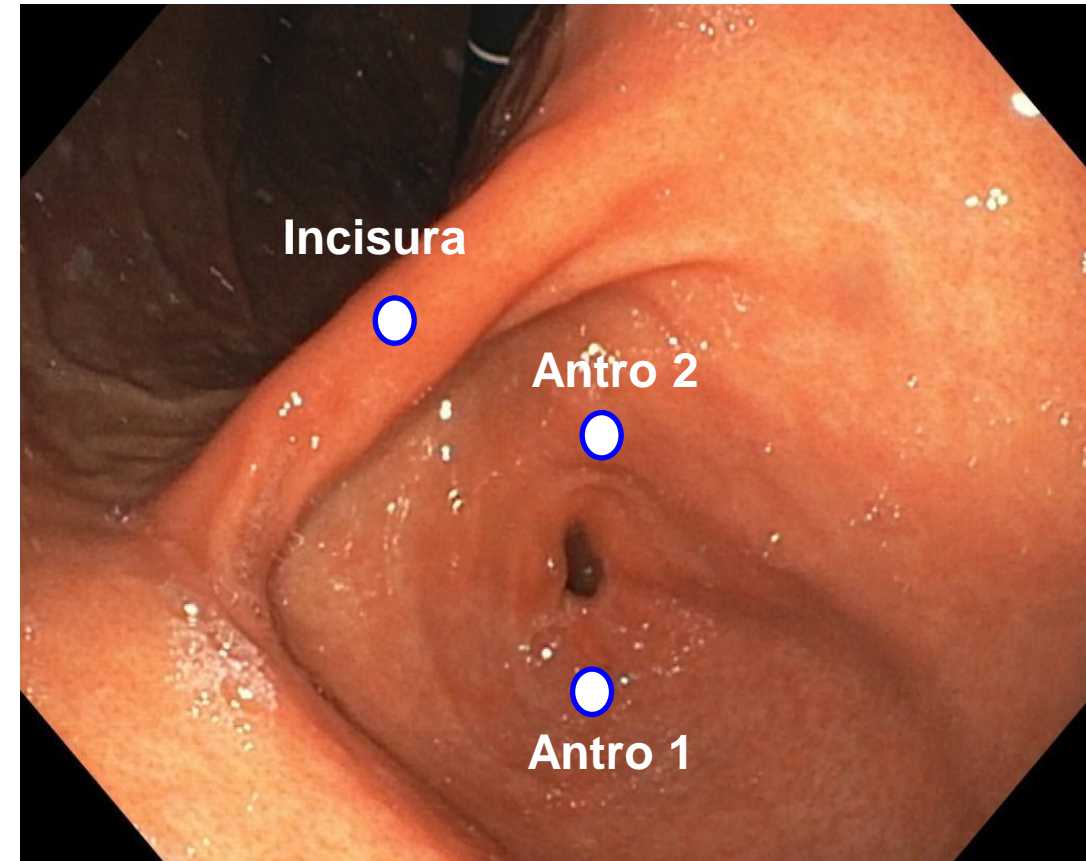
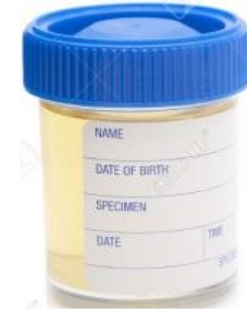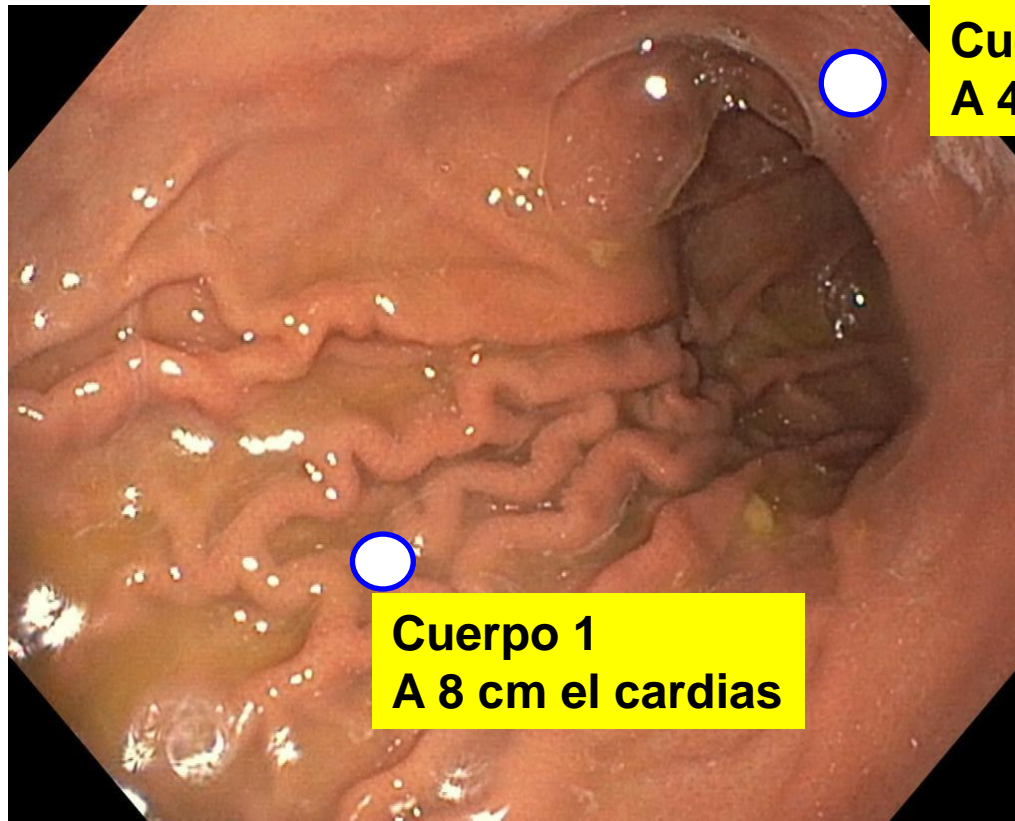
**No informa sobre
el riesgo de cáncer**



OLGA (2007) , OLGIM (2010)



Sídney



Kyoto 2015
Maastricht 2022

The effect of incisura angularis biopsy sampling on the assessment of gastritis stage

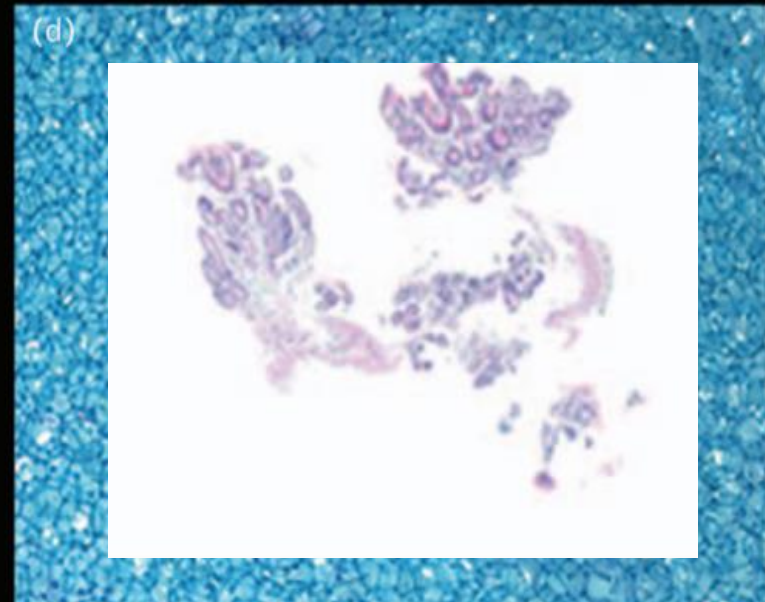
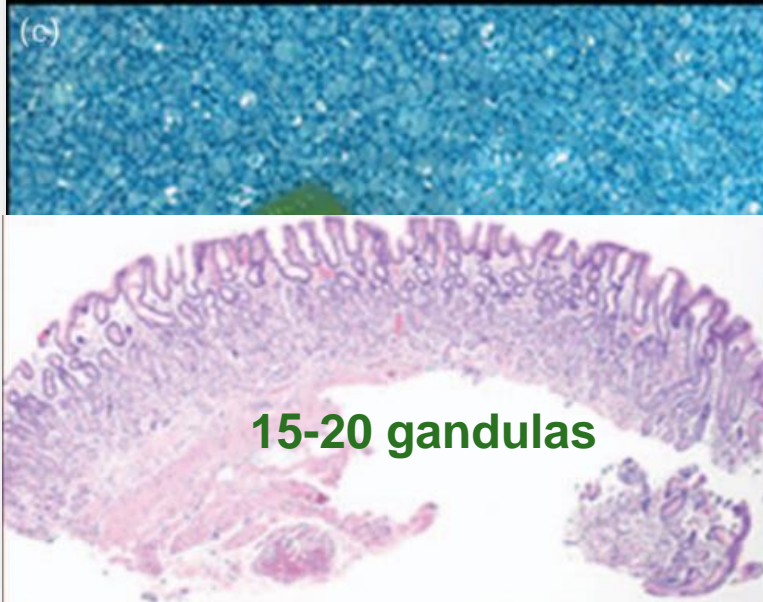
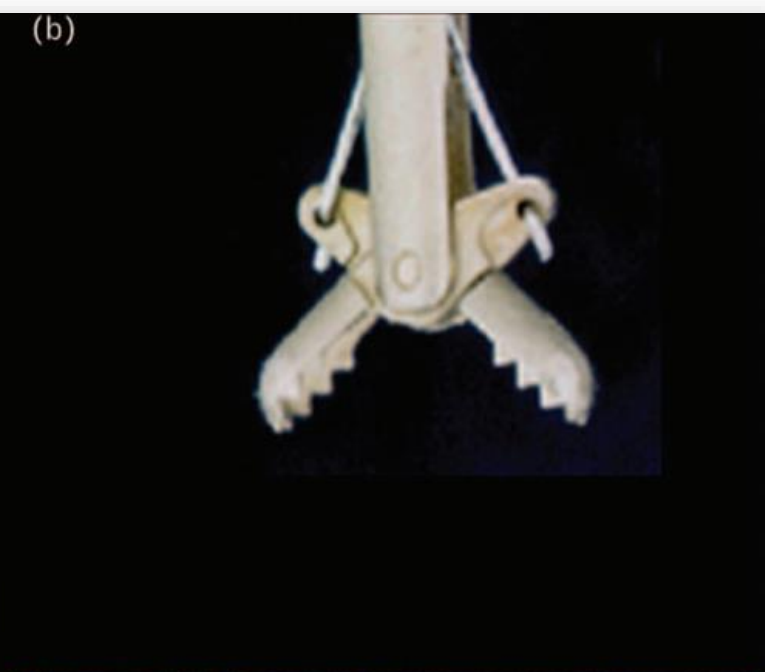
Sergejs Isajevs^{a,b,d}, Inta Liepniece-Karele^{a,b,d}, Dainius Janciauskas^e,
Georgijs Moisejevs^{a,b}, Konrads Funka^{a,b}, Ilze Kikuste^c, Aigars Vanags^c,
Ivars Tolmanis^c and Marcis Leja^{a,b,c}

Eur J Gastroenterol Hepatol 2014;26:510-3

835 pacientes

	Antrum	Incisura angularis	Corpus
<i>(A) Atrophy score</i>			
0	663	690	745*
1	133	94	58*
2	38	45	32
3	4	9 ^{*, ≠}	4
<i>(B) Intestinal metaplasia (IM) score</i>			
0	671	711	757
1	126	75*	47
2	37	44	21
3	4	9 ^{*, ≠}	4
<i>(C) Acute inflammation score</i>			
0	362	384	424
1	112	119	126
2	288	249	219
3	75	85	60
<i>(D) Chronic inflammation score</i>			
0	192	157	199
1	431	430	503
2	209	225	134
3	7	27 ^{*, ≠}	3

Sin biopsia de incisura
OLGA alto riesgo < 30%
OLGIM alto riesgo < 35%



Staging Gastritis: An International Proposal

		CORPUS			
		No Atrophy (score 0)	Mild Atrophy (score 1)	Moderate Atrophy (score 2)	Severe Atrophy (score 3)
A N T R U M	No Atrophy (score 0) (including <i>incisura angularis</i>)	STAGE 0	STAGE I	STAGE II	STAGE II
	Mild Atrophy (score 1) (including <i>incisura angularis</i>)	STAGE I	STAGE I	STAGE II	STAGE III
	Moderate Atrophy (score 2) (including <i>incisura angularis</i>)	STAGE II	STAGE II	STAGE III	STAGE IV
	Severe Atrophy (score 3) (including <i>incisura angularis</i>)	STAGE III	STAGE III	STAGE IV	STAGE IV

Rugge M, Genta RM, OLGA-Group.
Gastroenterology 2005;129:1807–8.

Current topics

Staging and grading of chronic gastritis

Massimo Rugge MD, Robert M. Genta MD*

Staging and grading of chronic gastritis

		CORPUS			
		No Inflammation (G0)	Mild Inflammation (G1)	Moderate Inflammation (G2)	Severe Inflammation (G3)
A N T R U M	No Inflammation (G0)	GRADE 0	GRADE I	GRADE II	GRADE II
	Mild Inflammation (G1)	GRADE I	GRADE II	GRADE II	GRADE III
	Moderate Inflammation (G2)	GRADE II	GRADE II	GRADE III	GRADE IV
	Severe Inflammation (G3)	GRADE II	GRADE III	GRADE IV	GRADE IV

Rugge M, Human Pathology 2005;36:228 -33

ORIGINAL ARTICLE: Clinical Endoscopy

The staging of gastritis with the OLGA system by using intestinal metaplasia as an accurate alternative for atrophic gastritis

Lisette G. Capelle, MD, Annemarie C. de Vries, MD, PhD, Jelle Haringsma, MD, Frank Ter Borg, MD, PhD, Richard A. de Vries, MD, PhD, Marco J. Bruno, MD, PhD, Herman van Dekken, MD, PhD, Jos Meijer, MD, Nicole C. T. van Grieken, MD, PhD, Ernst J. Kuipers, MD, PhD

Capelle LG, Gastrointest Endosc 2010;71.1150-8

TABLE 5. Interobserver agreement (kappa values) for different stages of the OLGA and OLGIM staging systems

Stage(s)	OLGA	OLGIM
0-IV	0.38	0.58
0	0.56	0.88
I	0.19	0.48
II	0.29	0.31
III	0.36	0.48
IV	0.48	0.59
III-IV	0.48	0.61

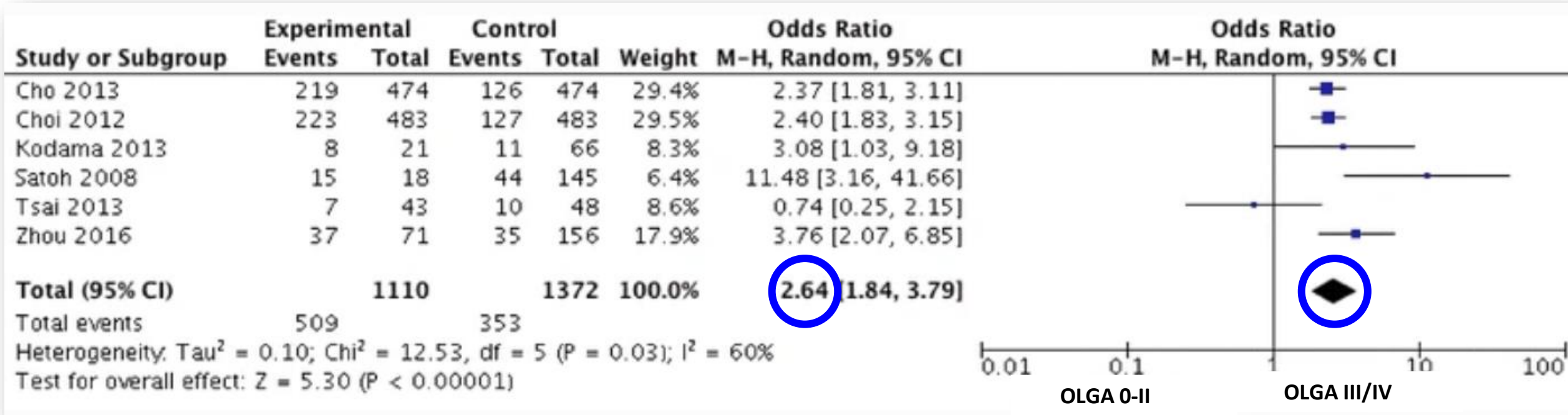
OLGA, operative link on gastritis assessment; *OLGIM*, operative link on gastric intestinal metaplasia assessment.

The significance of OLGA and OLGIM staging systems in the risk assessment of gastric cancer: a systematic review and meta-analysis



Hu Yue^{1,2} · Liu Shan¹ · Lv Bin^{1,2}

OLGA III/IV Casos y controles

Cáncer gástrico

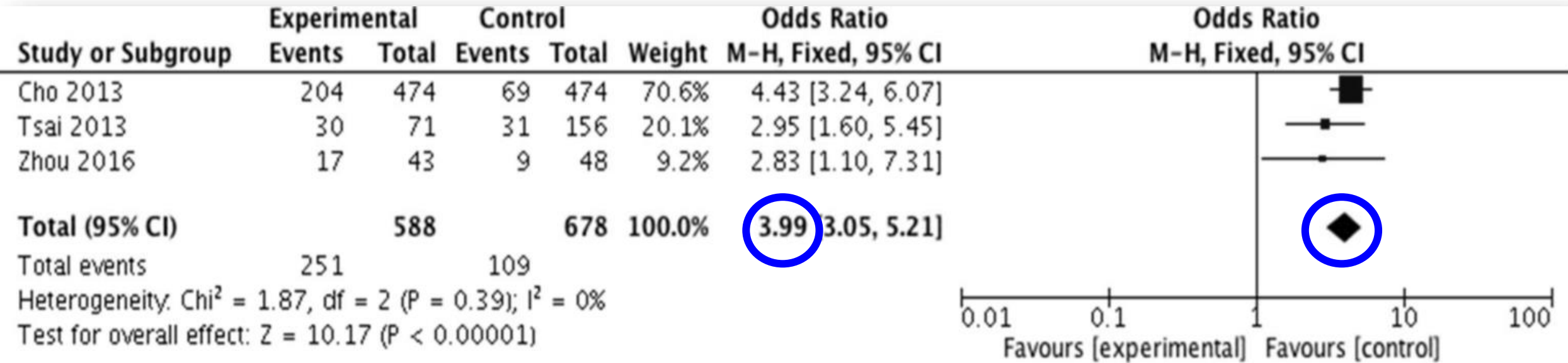


The significance of OLGA and OLGIM staging systems in the risk assessment of gastric cancer: a systematic review and meta-analysis

Hu Yue^{1,2}  · Liu Shan¹ · Lv Bin^{1,2} 


OLGIM III/IV, Casos y controles

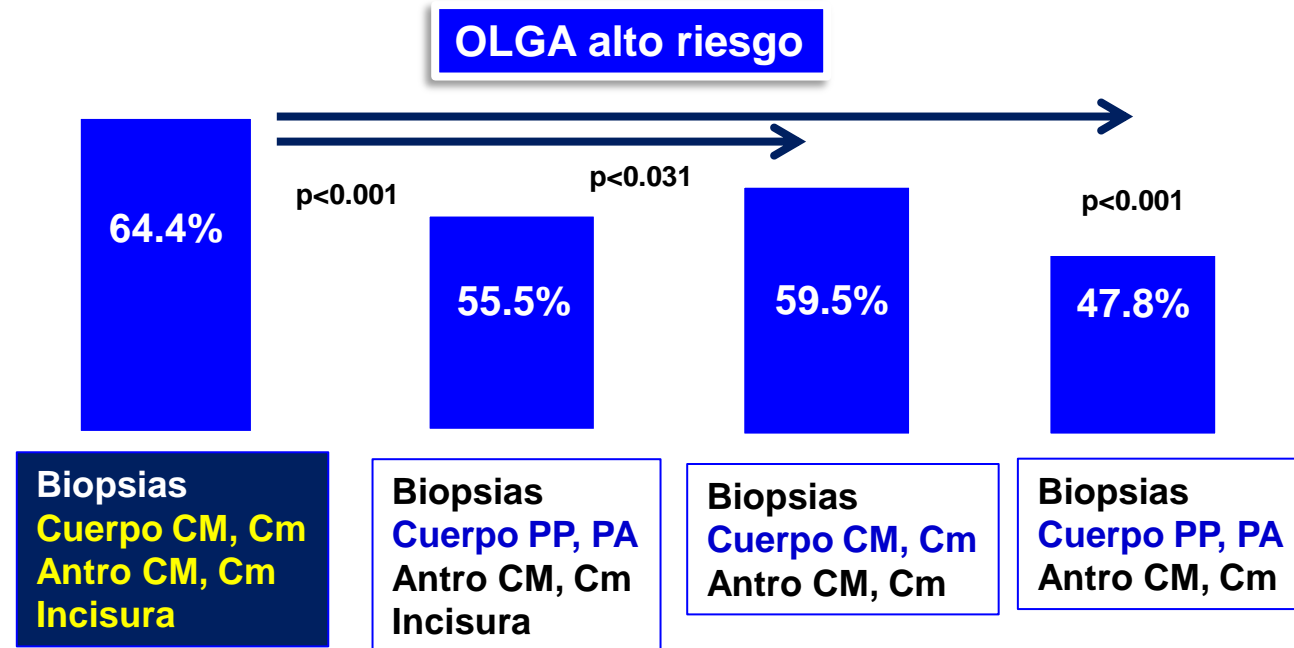
Cáncer gástrico



Yue H, et al. Gastric Cancer 2018;21: 579–87


Effect of biopsy site on detection of gastric cancer high-risk groups by OLGA and OLGIM stages

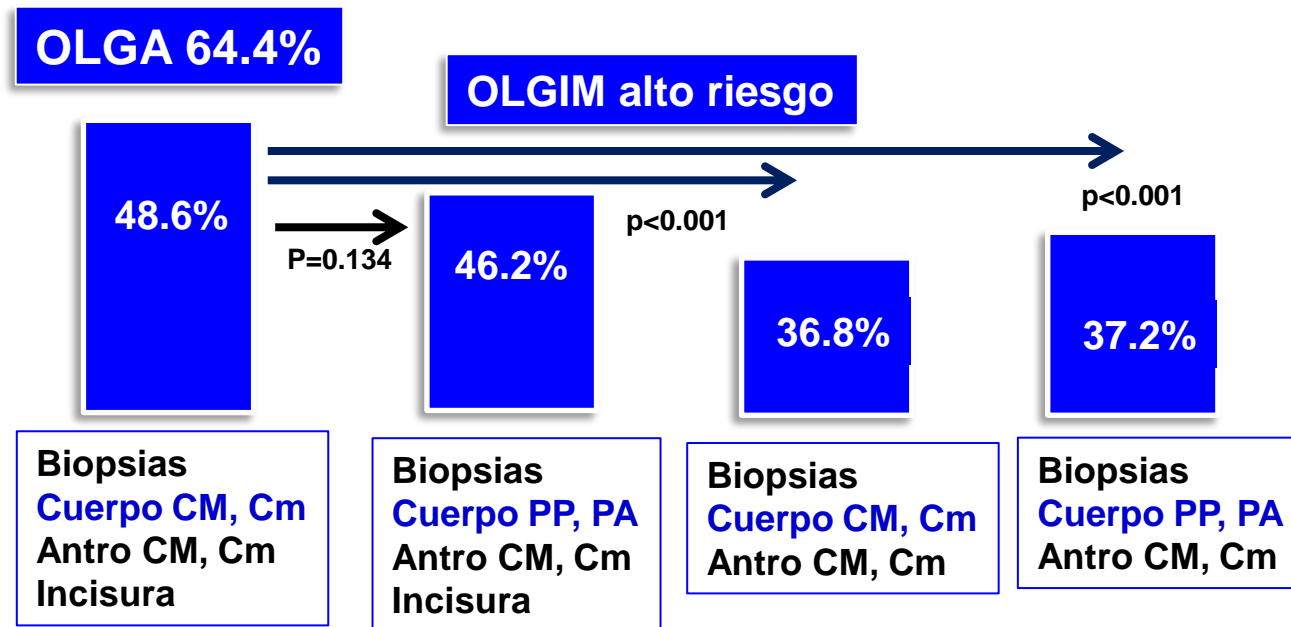
Young-Il Kim¹ | Myeong-Cherl Kook¹ | Soo-Jeong Cho¹ | Jong Yeul Lee¹ |
Chan Gyoo Kim¹ | Jungnam Joo² | Il Ju Choi¹ 



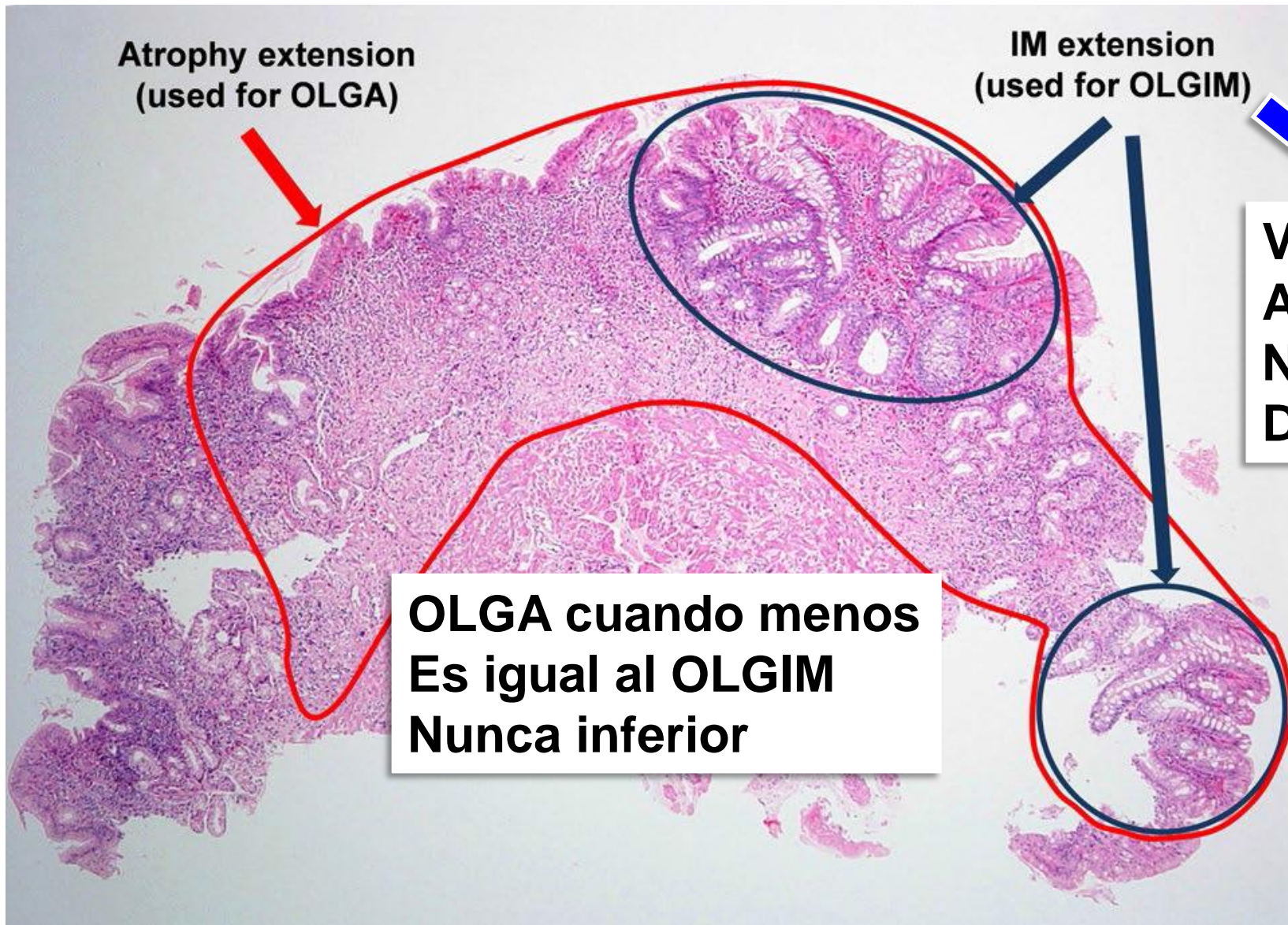
Kim YII, Helicobacter 2017;22:DOI: 10.1111/hel.12442

Effect of biopsy site on detection of gastric cancer high-risk groups by OLGA and OLGIM stages

Young-Il Kim¹ | Myeong-Cherl Kook¹ | Soo-Jeong Cho¹ | Jong Yeul Lee¹ |
Chan Gyoo Kim¹ | Jungnam Joo² | Il Ju Choi¹ 



Kim YII, Helicobacter 2017;22:DOI: 10.1111/hel.12442



Atrophy extension
(used for OLGA)

IM extension
(used for OLGIM)

Variante de
Atrofia
No entidad
Diferente

OLGA cuando menos
Es igual al OLGIM
Nunca inferior

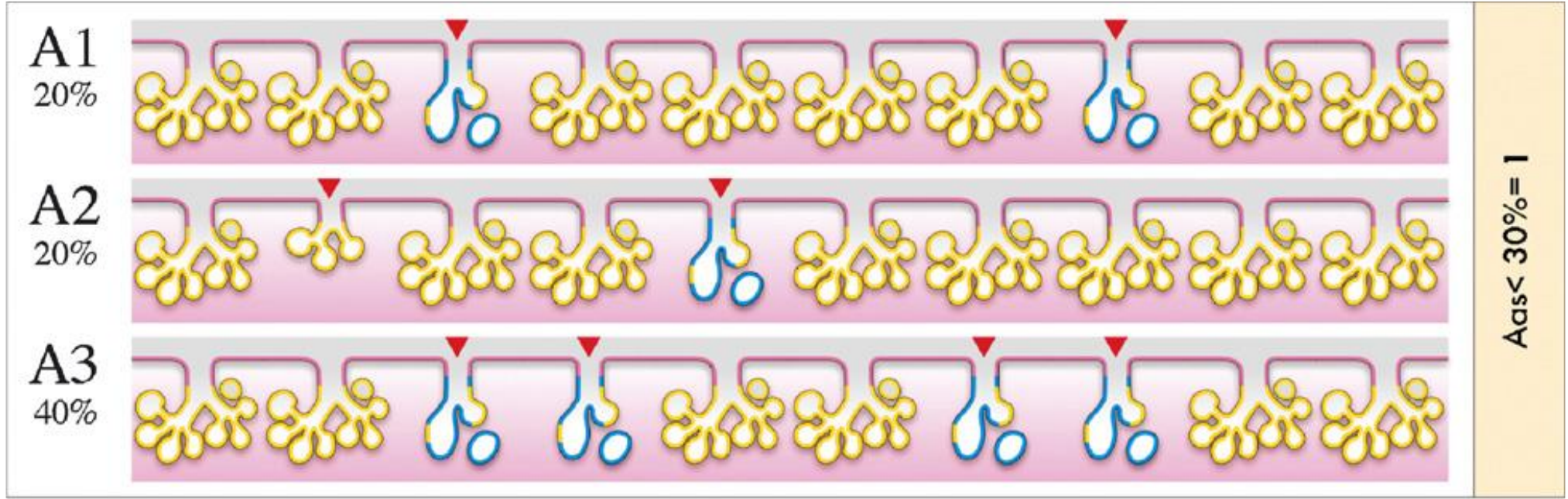
Matysiak-Budnik T, Dig Dis Sci 2020, abril 20
Rugge M, Gastrointest Endosc. 2011;73:411-2.

OLGA identifica todos Los tipos de atrofia

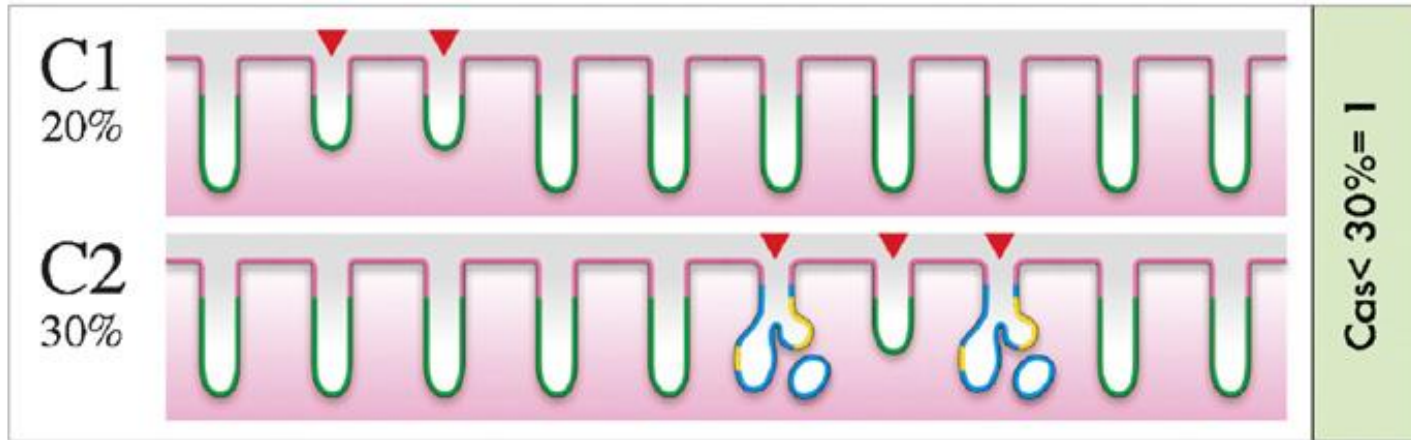
Malfertheiner P, Gut 2022 Online agosto 15

OLGA I

80/3
↓
27%



50/2
↓
25%



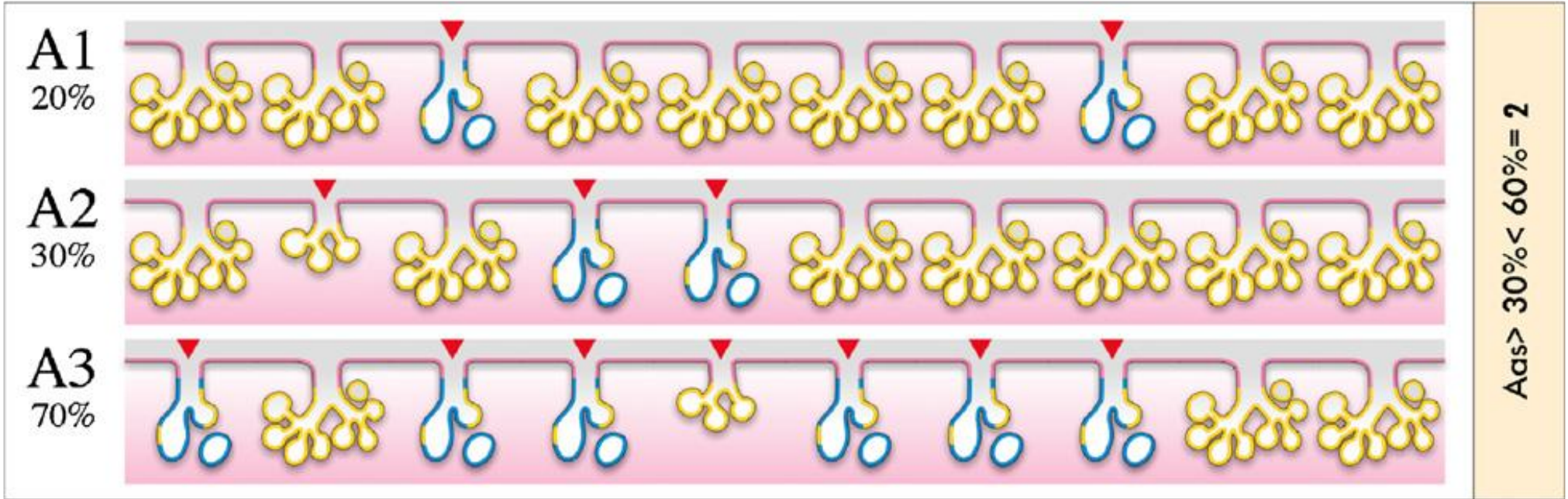
	Cas0	Cas1	Cas2	Cas3
Aas0	Stage 0	Stage I	Stage II	Stage II
Aas1	Stage I	Stage I	Stage II	Stage III
Aas2	Stage II	Stage II	Stage III	Stage IV
Aas3	Stage III	Stage III	Stage IV	Stage IV

OLGA II

120/3



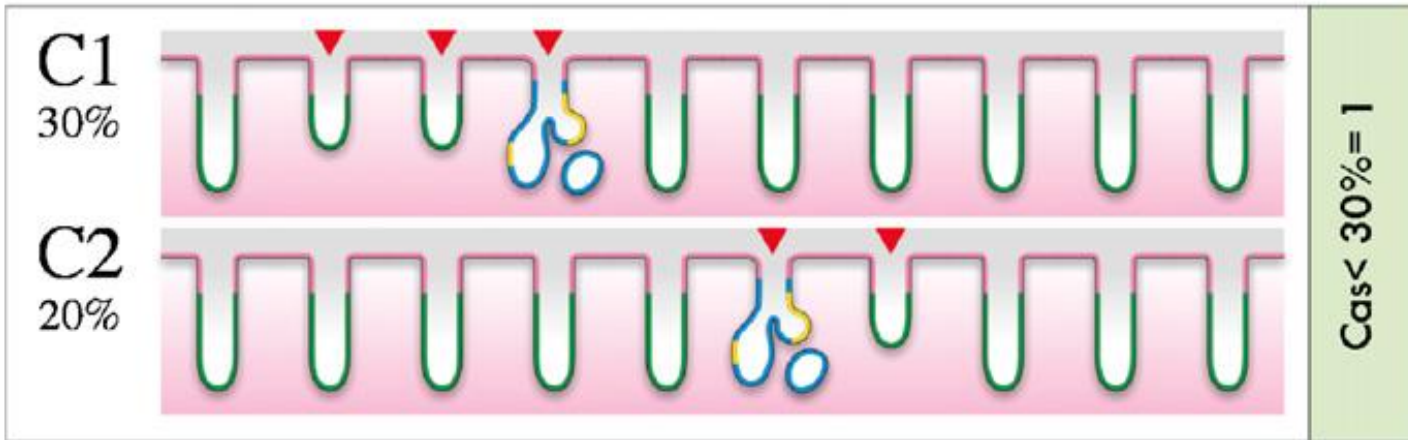
40%



50/2



25%



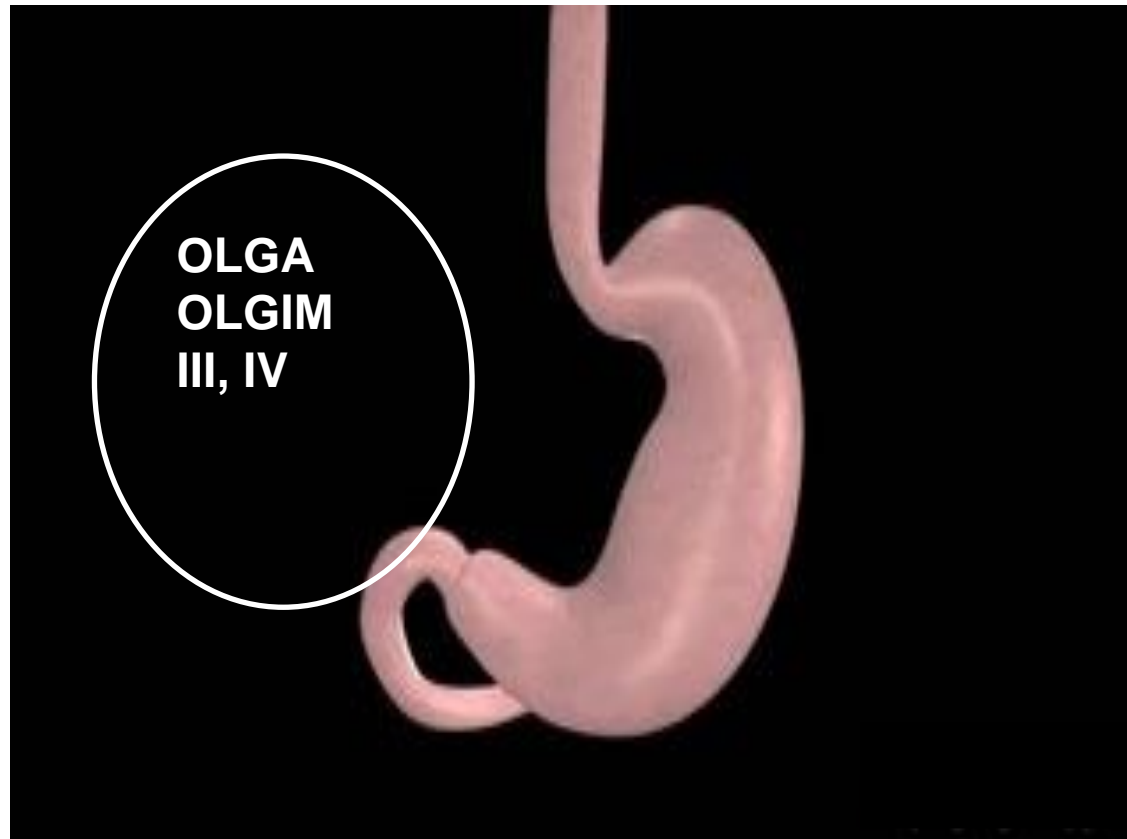
	Cas0	Cas1	Cas2	Cas3
Aas0	Stage 0	Stage I	Stage II	Stage II
Aas1	Stage I	Stage I	Stage II	Stage III
Aas2	Stage I	Stage II	Stage III	Stage IV
Aas3	Stage III	Stage III	Stage IV	Stage IV

Estadiaoje de OLGA

Atrophy Score		Corpus			
		No Atrophy (score 0)	Mild Atrophy (score 1)	Moderate Atrophy (score 2)	Severe Atrophy (score 3)
A n t r u m	No Atrophy (score 0) (including <i>incisura angularis</i>)	STAGE 0	STAGE I	STAGE II	STAGE II
	Mild Atrophy (score 1) (including <i>incisura angularis</i>)	STAGE I	STAGE I	STAGE II	STAGE III
	Moderate Atrophy (score 2) (including <i>incisura angularis</i>)	STAGE II	STAGE II	STAGE III	STAGE IV
	Severe Atrophy (score 3) (including <i>incisura angularis</i>)	STAGE III	STAGE III	STAGE IV	STAGE IV

Estratificación de la atrofia o MI Biopsias

Identificar el “Estómago premaligno”

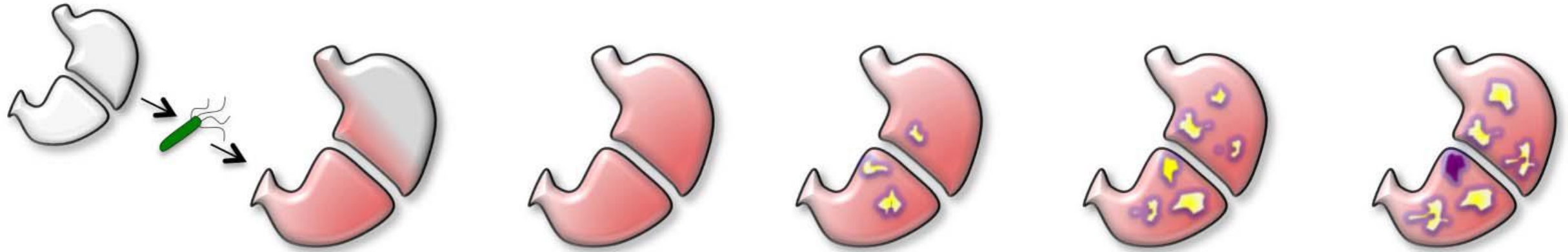


Sugano K, Gut 2015;64:1353-67

Take S, J Gastroenterol 2020;55:281-8

Malfertheiner P, Maastricht VI. Gut 2022 Online agosto 15

Tiempo



Estado 0

Estado 0

Estado I-II

Estado III-IV

Estado III-IV

Gastritis no atrófica
Predominante antro

Gastritis no atrófica
Pangastritis

Gastritis atrófica
Predominante antro

Pangastritis atrófica
Multifocal

Lesión precancerosa
Avanzada (Neoplasia
Intraepitelial)
Pangastritis atrófica

Riesgo de cáncer extremadamente bajo

**Alto Riesgo de
Cáncer alto**

OLGA OLGIM

Guideline
65-88



Authors
Pedro Pimentel-Nunes¹,
Gianluca Esposito⁷, Mon
Jean-Marc Dumonceau¹⁶,
Ernst J. Kuipers¹⁶, Mario

Annibale⁷,
Hoofst¹⁵,

Guidelines

Chronic atrophic gastritis: Natural history, diagnosis and therapeutic management. A position paper by the Italian Society of Hospital Gastroenterologists and Digestive Endoscopists [AIGO], the Italian Society of Digestive Endoscopy [SIED], the Italian Society of Gastroenterology [SIGE], and the Italian Society of Internal Medicine [SIMI]

Edith Lahner^{a,*}, Rocco Maurizio Zagari^b, Angelo Zullo^c, Antonio Di Sabatino^d, Alberto Meggio^e, Paola Cesaro^f, Marco Vincenzo Lenti^d, Bruno Annibale^a, Gino Roberto Corazza^d

Lahner E, et al. Dig Liver Dis 2019;51:1621-32

British Society of Gastroenterology guidelines on the diagnosis and management of patients at risk of gastric adenocarcinoma

Matthew Banks,^{1,2} David Graham,^{1,3} Marnix Jansen,⁴ Takuji Gotoda,⁵ Sergio Coda,⁶ Massimiliano di Pietro,^{7,8} Noriya Uedo,⁹ Pradeep Bhandari,¹⁰ D Mark Pritchard,¹¹ Ernst J Kuipers,¹² Manuel Rodriguez-Justo,⁴ Marco R Novelli,⁴ Krish Rangunath,¹³ Neil Shepherd,¹⁴ Mario Dinis-Ribeiro¹⁵

Banks M, et al. Gut 2019;68:1545-75

Kyoto global consensus report on *Helicobacter pylori* gastritis

Sugano K, et al. Gut 2015;64:1353-1367

Kentaro Sugano,¹ Jan Tack,² Ernst J Kuipers,³ David Y Graham,⁴ Emad M El-Omar,⁵ Soichiro Miura,⁶ Ken Haruma,⁷ Masahiro Asaka,⁸ Naomi Uemura,⁹ Peter Malfertheiner,¹⁰ on behalf of faculty members of Kyoto Global Consensus

Management of *Helicobacter pylori* infection: the Maastricht VI/Florence consensus report

Peter Malfertheiner^{1,2}, Francis Megraud³, Theodore Rokkas^{4,5}, Javier P Gisbert^{6,7}, Jyh-Ming Liou⁸, Christian Schulz^{1,9}, Antonio Gasbarrini,¹⁰ Richard H Hunt,^{11,12} Marcis Leja^{13,14}, Colm O'Morain,¹⁵ Massimo Rugge^{16,17}, Sebastian Suerbaum,^{9,18} Herbert Tilg¹⁹, Kentaro Sugano²⁰, Emad M El-Omar^{21,22} On behalf of the European Helicobacter and Microbiota Study group

Malfertheiner P, Gut 2022 Online agosto 15

British Society of Gastroenterology guidelines on the diagnosis and management of patients at risk of gastric adenocarcinoma

Matthew Banks,^{1,2} David Graham,^{1,3} Marnix Jansen,⁴ Takuji Gotoda,⁵ Sergio Coda,⁶ Massimiliano di Pietro,^{7,8} Noriya Uedo,⁹ Pradeep Bhandari,¹⁰ D Mark Pritchard,¹¹ Ernst J Kuipers,¹² Manuel Rodriguez-Justo,⁴ Marco R Novelli,⁴ Krish Ragunath,¹³ Neil Shepherd,¹⁴ Mario Dinis-Ribeiro¹⁵

13. *We recommend endoscopic surveillance every 3 years should be offered to patients diagnosed with extensive GA or GIM, defined as that affecting the antrum and body (evidence level: low quality; grade of recommendation: strong; level of agreement: 100%).*

Management of epithelial precancerous conditions and lesions in the stomach (MAPS II): European Society of Gastrointestinal Endoscopy (ESGE), European *Helicobacter* and Microbiota Study Group (EHMSG), European Society of Pathology (ESP), and Sociedade Portuguesa de Endoscopia Digestiva (SPED) guideline update 2019














Authors

Pedro Pimentel-Nunes^{1,2,3}, Diogo Libânio^{1,2}, Ricardo Marcos-Pinto^{2,4}, Miguel Areia^{2,5}, Marcis Leja⁶, Gianluca Esposito⁷, Monica Garrido⁴, Ilze Kikuste⁶, Francis Megraud⁸, Tamara Matysiak-Budnik⁹, Bruno Annibale⁷, Jean-Marc Dumonceau¹⁰, Rita Barros^{11,12}, Jean-François Fléjou¹³, Fátima Carneiro^{11,12,14}, Jeanin E. van Hooft¹⁵, Ernst J. Kuipers¹⁶, Mario Dinis-Ribeiro^{1,2}

17 Patients with advanced stages of atrophic gastritis (severe atrophic changes or intestinal metaplasia in both antrum and corpus, OLGA/OLGIM III/IV) should be followed up with a high quality endoscopy every 3 years (low quality evidence, strong recommendation)

Management of *Helicobacter pylori* infection: the Maastricht VI/Florence consensus report

Peter Malfertheiner ,^{1,2} Francis Megraud ,³ Theodore Rokkas ,^{4,5}
Javier P Gisbert ,^{6,7} Jyh-Ming Liou ,⁸ Christian Schulz ,^{1,9}
Antonio Gasbarrini,¹⁰ Richard H Hunt,^{11,12} Marcis Leja ,^{13,14} Colm O'Morain,¹⁵
Massimo Rugge ,^{16,17} Sebastian Suerbaum,^{9,18} Herbert Tilg ,¹⁹
Kentaro Sugano ,²⁰ Emad M El-Omar ,^{21,22} On behalf of the European
Helicobacter and Microbiota Study group

***Statement 20:* Follow-up at regular intervals, and by use of endoscopic biopsy protocols, is mandatory in patients with severe atrophic gastritis (OLGA III/IV or OLGIM III/IV).**

Agreement 97%

Grade B1

Malfertheiner P, Gut 2022 Online agosto 15

Vigilancia

RECOMMENDATION

17 Patients with advanced stages of atrophic gastritis (severe atrophic changes or IM in both antrum and corpus, OLGA/OLGIM III/IV) should be followed up with a high quality endoscopy every 3 years.

Low quality evidence, strong recommendation (100% agree [94% strongly or moderately agree]).

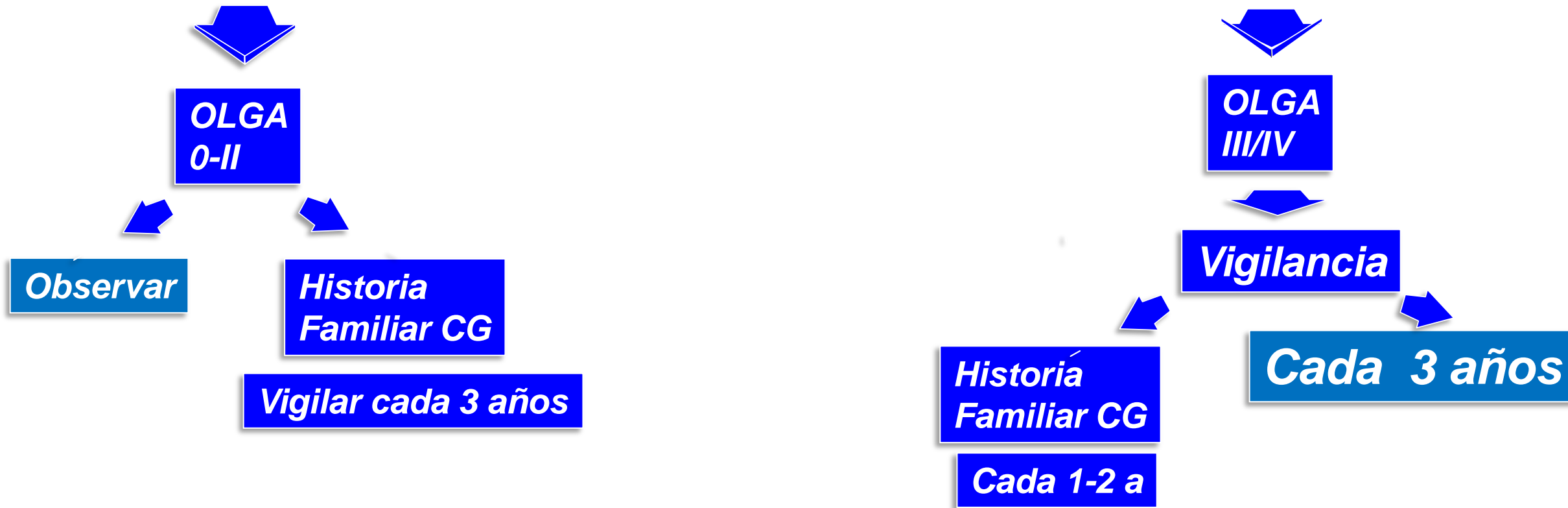
Maastricht VI

by these means.⁴⁰⁰ Eradication therapy should be offered to all *H. pylori* positive patients² combined with upper GI endoscopy for all patients with positive serologic biopsy (pepsinogen I/II < 3 and/or pepsinogen I < 30 µg/L). Regular endoscopic surveillance should be offered to those with OLGA/OLGIM II-IV stage as recommended by MAPPS II guidelines.⁸⁹

Malfertheiner P, Gut 2022 Online agosto 15

Vigilancia de Gastritis Crónica

5 Biopsias: cuerpo (2), Antro (2), Incisura (1)



Sugano K, Kyoto Consensus. Gut 2015; 64:1353-67

Zagari RM, Dig Liver Dis 2015;903-12

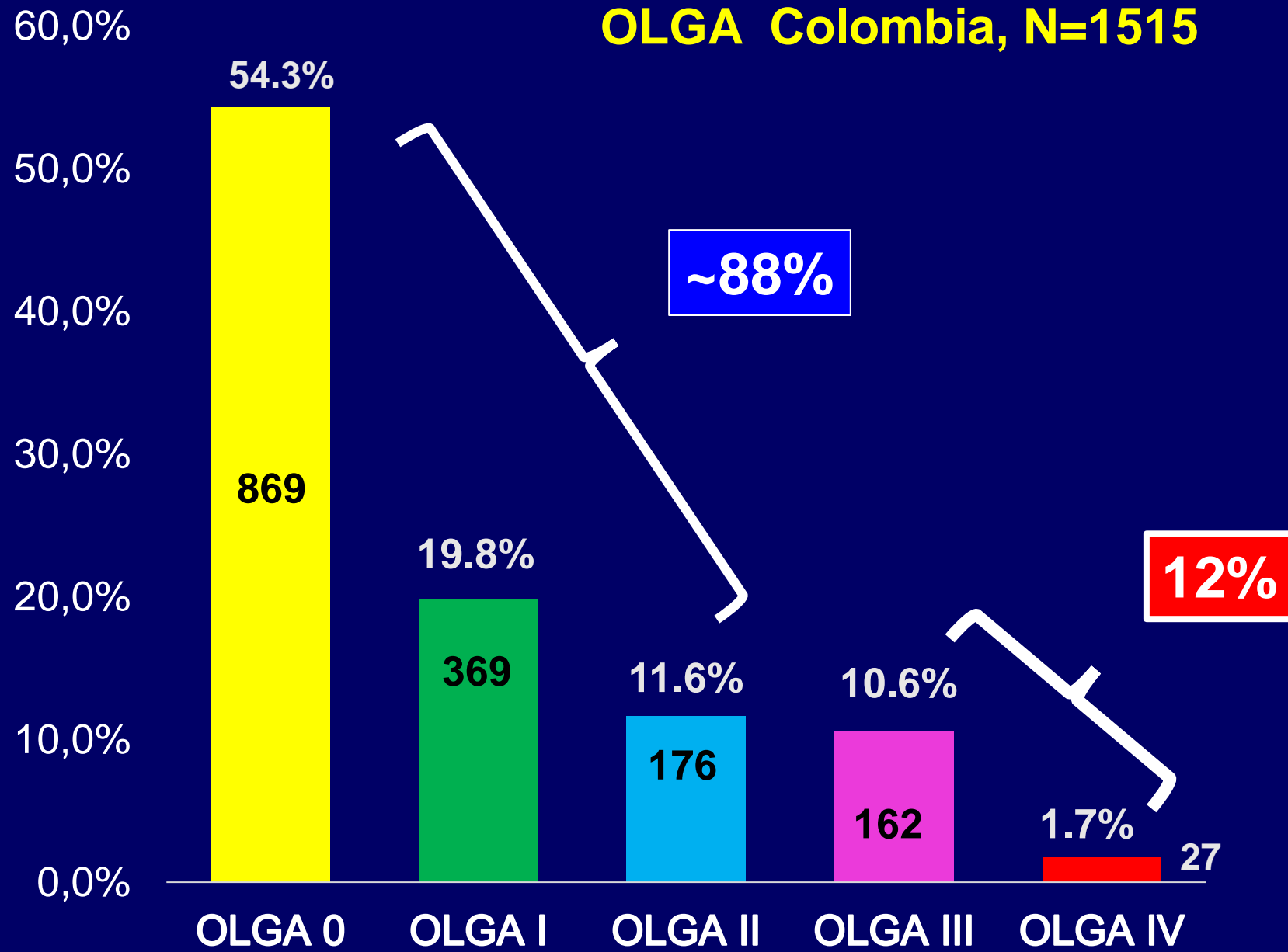
Rollán A, Rev Med Chile 2014;142:1181-92

Yue H, Gastric Cancer 2018;21:579-87

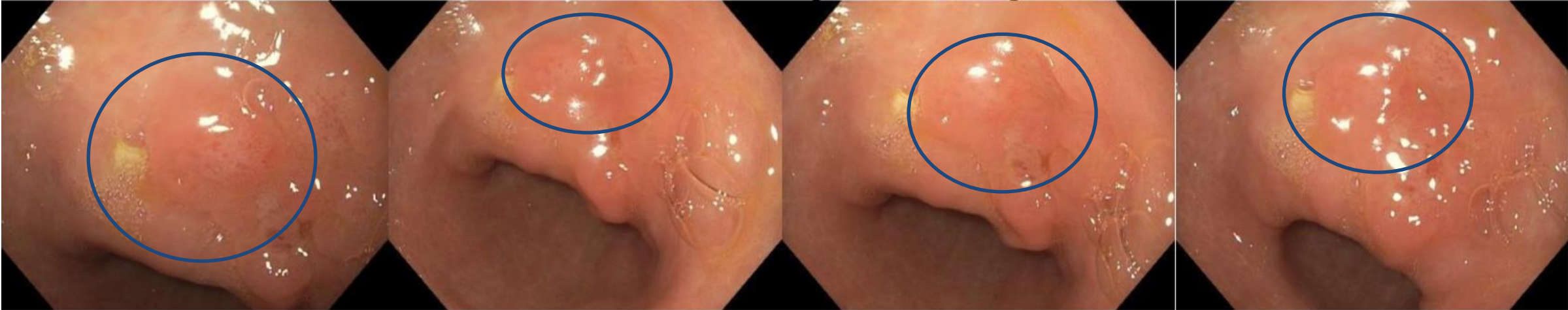Shah SC Gastroenterology 2021;161:1325-32

Pimentel-Nunes P, Endoscopy 2019;51:365-88

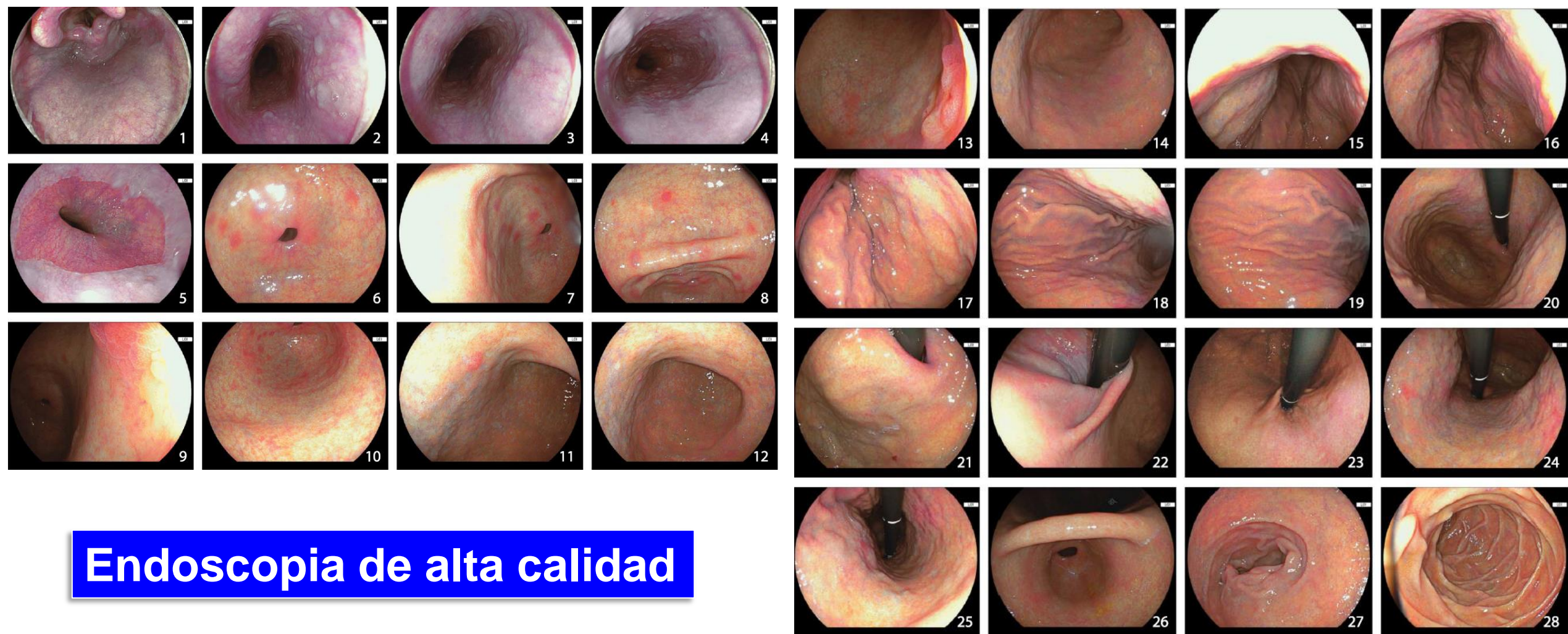
OLGA Colombia, N=1515



Mujer 52 años, OLGA IV 2 años de seguimiento



Endoscopia sistemática codificada alfa numérica 28 estaciones



Endoscopia de alta calidad

Importancia de las lesiones precursoras de Cáncer Gástrico



***Vigilar para detectar
Cáncer Gástrico temprano***



***Tratamiento
Endoscópico***



***Sobrevida
5 años >90%***



44 meses



CG avanzado

***Sobrevida
5 años <25%***

Endoscopic grading of gastric intestinal metaplasia on risk assessment for early gastric neoplasia: can we replace histology assessment also in the West?

Pedro Marcos ,^{1,2} Gisela Brito-Gonçalves,³ Diogo Libânio,^{1,4} Inês Pita,¹ Rui Castro,¹ Inês Sá ,¹ Mário Dinis-Ribeiro,^{1,4} Pedro Pimentel-Nunes^{1,4,5}

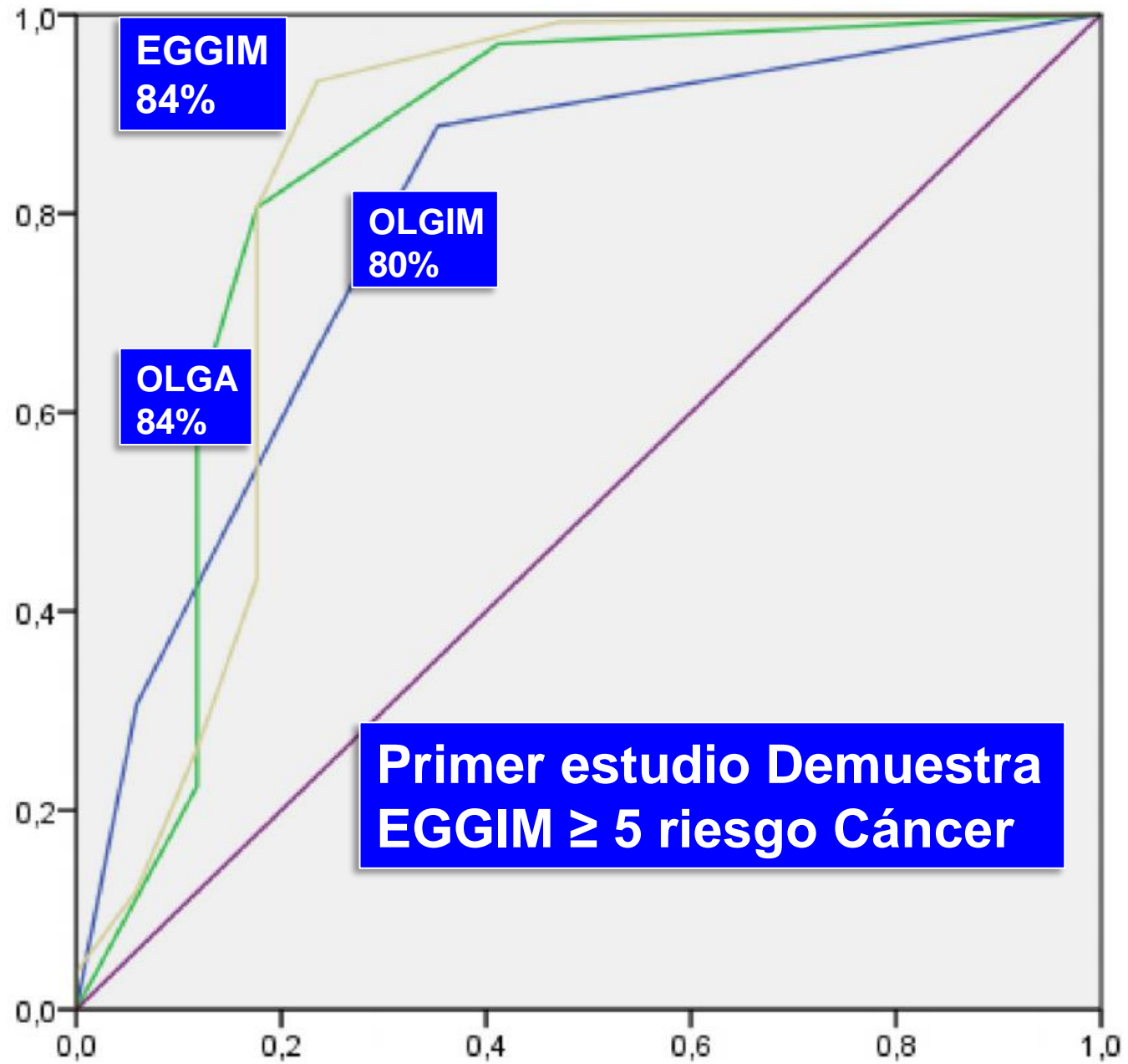
OLGIM, OLGA

EKGIM: Graduación endoscópica Metaplasia intestinal

Antro C>, C<, Cuerpo C>, C<, Incisura: estaciones de Sídney

Cada sitio 0-2 puntos

0=no MI, 1: MI(focal) <30%, 2: MI Extensa ≥ 30%



Displasia

Biopsia Gástrica

Indefinido neoplasia
Intraepitelial/displasia

Bajo grado neoplasia
Intraepitelial/displasia

Alto grado neoplasia
Intraepitelial/displasia

Re examinar

Sin lesión
Endoscópica

Seguimiento
12 meses

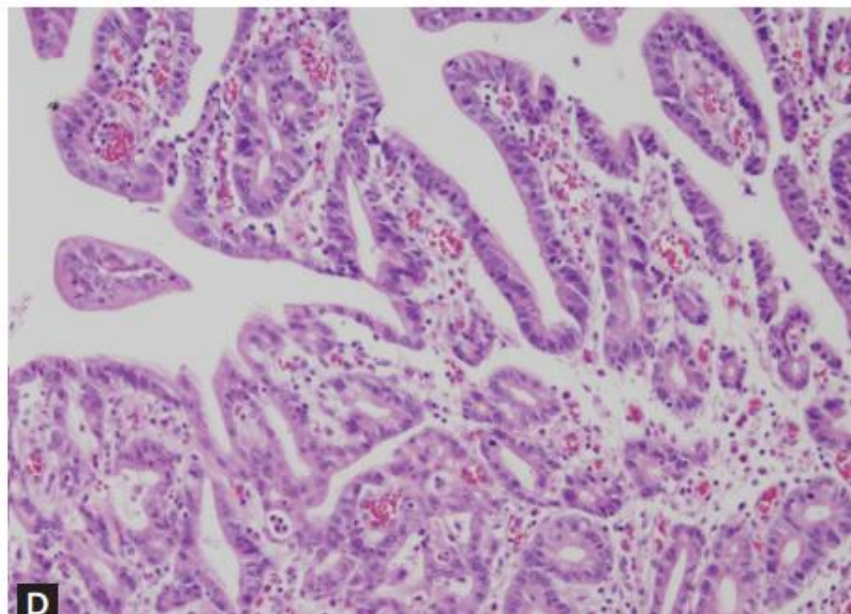
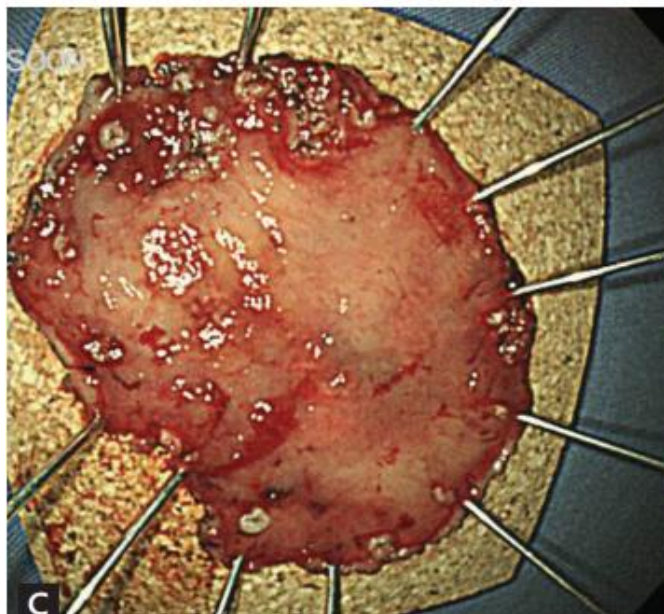
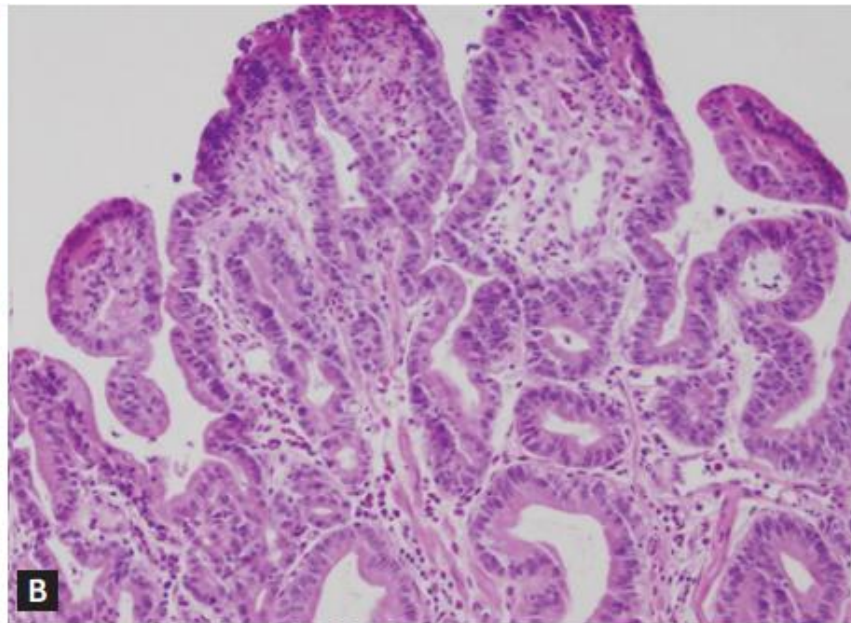
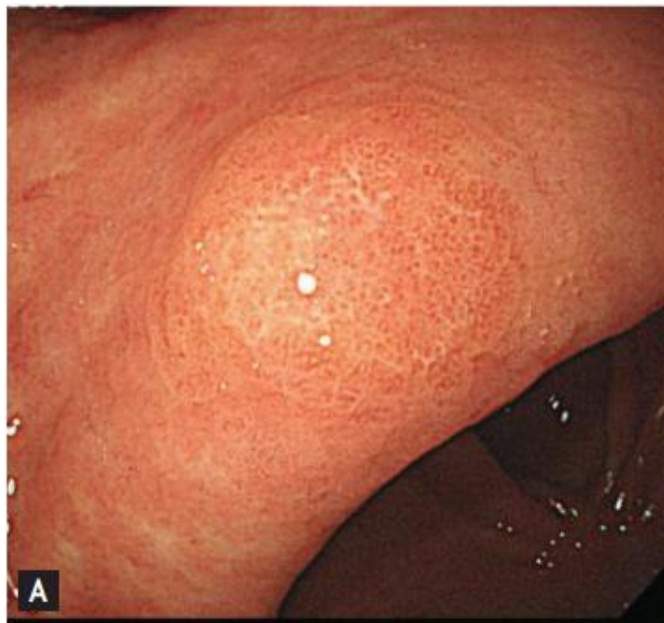Endoscópicamente
Definida

Resección endoscópica

No Endoscópicamente
Definida Control en 6mSES

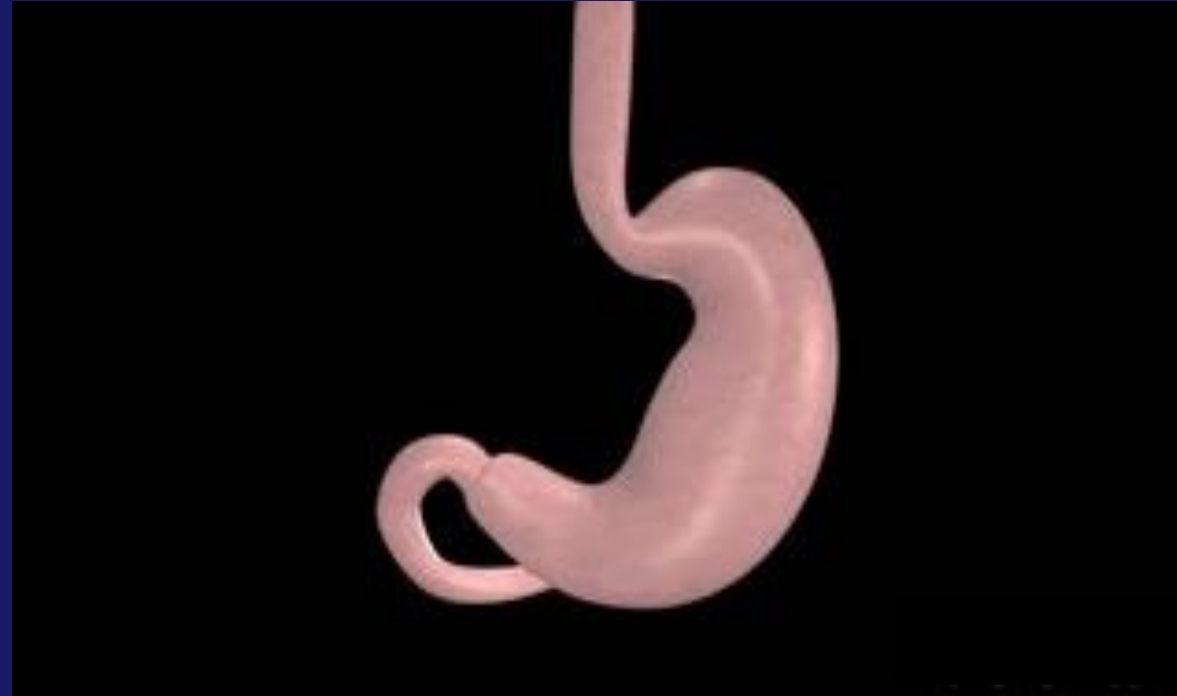Endoscópicamente
Definida

Displasia Gástrica



Estómago premaligno

**Gastritis
Autoinmune**

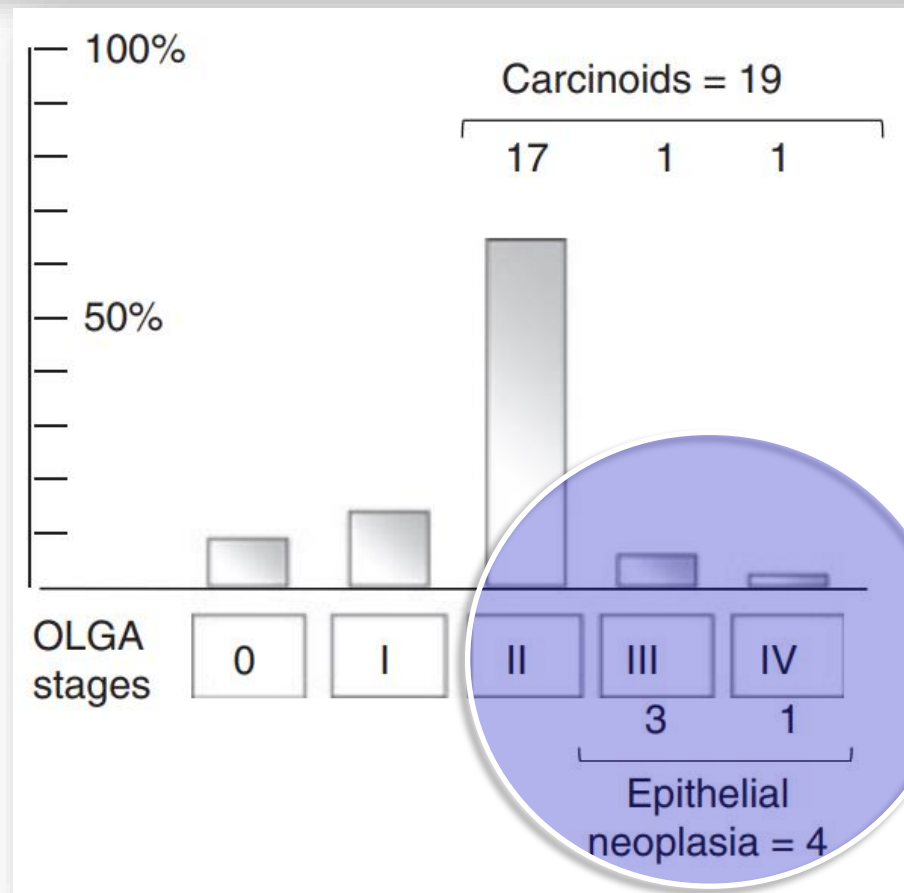


Vigilar c/3- 5años

Pimentel-Nunes P, Endoscopy 2019; 51: 365-88
Shah SC, Gastroenterology 2021;161:1325-32




Autoimmune gastritis: histology phenotype and OLGA staging

M. Rugge^{*,†,1}, M. Fassan^{*,‡,1}, M. Pizzi[‡], V. Zorzetto[‡], G. Maddalo[‡], S. Realdon[†], M. DeBernard[§], C. Betterle^{*}, R. Cappelleso^{*}, G. Pennelli^{*}, M. de Boni[¶] & F. Farinati[‡]



Original research

Autoimmune gastritis: long-term natural history in naïve *Helicobacter pylori*-negative patients

Massimo Rugge ,^{1,2} Ludovica Bricca,¹ Stefano Guzzinati,² Diana Sacchi,³ Marco Pizzi,¹ Edoardo Savarino,³ Fabio Farinati,³ Manuel Zorzi ,² Matteo Fassan,^{1,4} Angelo Paolo Dei Tos,¹ Peter Malfertheiner,⁵ Robert M Genta,^{6,7} David Y Graham ⁷

Rugge M, et al. Gut 2023;72:30–38

WHAT ARE THE NEW FINDINGS?

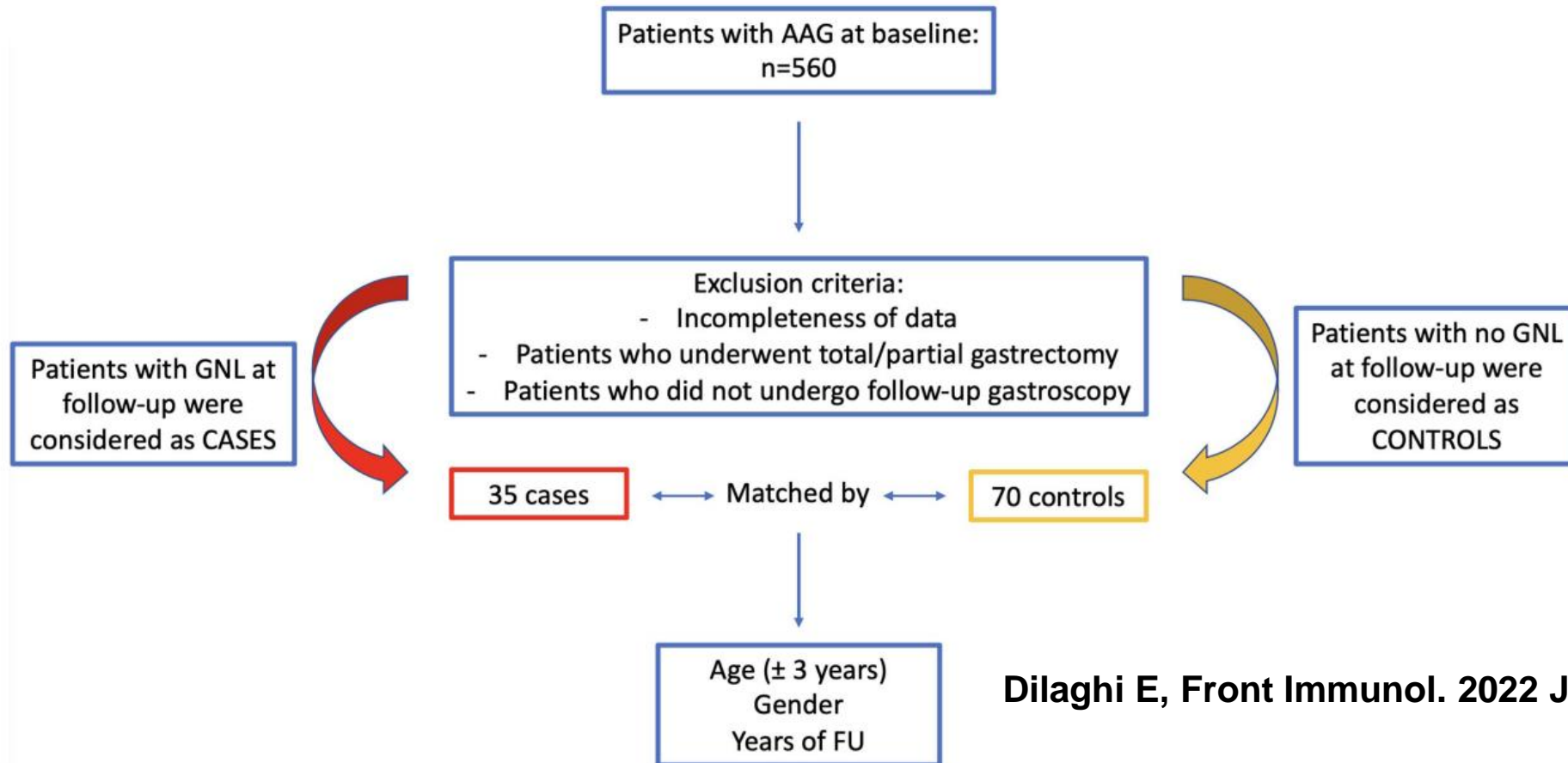
- ⇒ When previous or current *H. pylori* infection is rigorously excluded, the long-term follow-up of AIG does not reveal any excess risk for malignancy, except for thyroid cancers. In the natural history of AIG, the initial extensive pseudopyloric metaplasia is slowly replaced by focal gland intestinalisation.
- ⇒ Enterochromaffin-like-cell hyperplasia, an essential feature of AIG, progresses from diffuse to adenomatoid, the latter being significantly associated with type 1 neuroendocrine tumours.

HOW MIGHT IT IMPACT ON CLINICAL PRACTICE IN THE FORESEEABLE FUTURE?

- ⇒ In naïve *H. pylori*-negative patients, neuroendocrine neoplasia, not GC secondary prevention, prioritises the clinical, endoscopic and histopathological surveillance of AIG.

The Impact of Proton Pump Inhibitors on the Development of Gastric Neoplastic Lesions in Patients With Autoimmune Atrophic Gastritis

Emanuele Dilaghi[†], Mario Bellisario[†], Gianluca Esposito, Marilia Carabotti, Bruno Annibale[†] and Edith Lahner^{*†}



	Cases n=35	Controls n=70	p-value
Females	20 (57.1)	42 (60.0)	NS (matched)
Median age, years, median (range)	67.6 (44–84)	67.7 (42–86)	NS (matched)
Age >50 years	32 (91.4)	65 (92.9)	NS (matched)
Prior use of PPIs	19 (54.3)	13 (18.6)	<0.001
Body mass index ≥25	17 (48.6)	26 (37.1)	0.297
Smoking habit	4 (11.4)	34 (48.6)	<0.001
First-degree family history for gastric cancer	3 (8.6)	7 (10.0)	1.000
Dyspepsia	17 (48.6)	28 (40.0)	0.412
Use of antiplatelet or anticoagulant drugs	14 (40.0)	11 (15.7)	0.008
Iron deficiency anemia	4 (11.4)	13 (18.6)	0.412
Pernicious anemia	13 (37.1)	28 (40.0)	0.834
Severe corpus atrophy	13 (37.1)	27 (38.6)	1.000
Presence of corpus intestinal metaplasia	26 (74.3)	58 (82.9)	0.312

Management of upper gastrointestinal symptoms in patients with autoimmune gastritis

Juan D. Gomez Cifuentes^a, Jordan Sparkman^b and David Y. Graham^c

KEY POINTS

- The most common symptoms in autoimmune gastritis (AIG) are dyspepsia and typical gastroesophageal reflux (GERD) symptoms.
- Typical GERD symptoms are caused by weakly acid and alkaline reflux, the exact mechanism behind dyspepsia is unknown.
- Acid suppressant medications should be discontinued as their physiologic targets are absent in AIG patients.
- Therapy for AIG patients should be approached based on the predominant symptoms of GERD and dyspepsia.

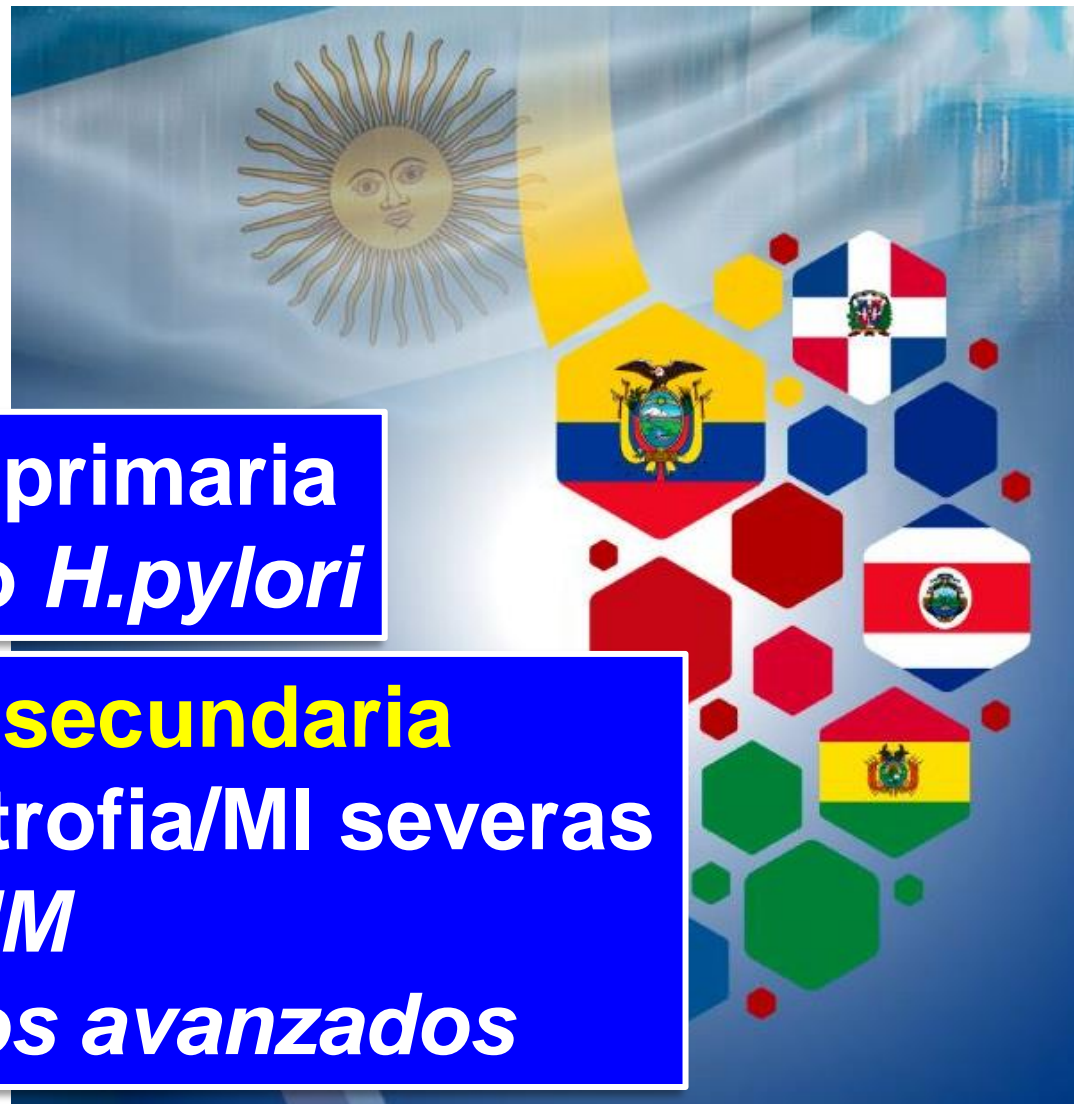Mensajes para la casa

Prevención Cáncer Gástrico LATAM?

Prevención primaria
Erradicando *H.pylori*

Prevención secundaria
Vigilando Atrofia/MI severas
OLGA/OLGIM
Endoscopios avanzados

Gastritis crónica autoinmune
Neuroendocrino



Muchas gracias!



Muchas gracias!



Queridos colegas de Perú



A Colombia, Un País hermano !!!

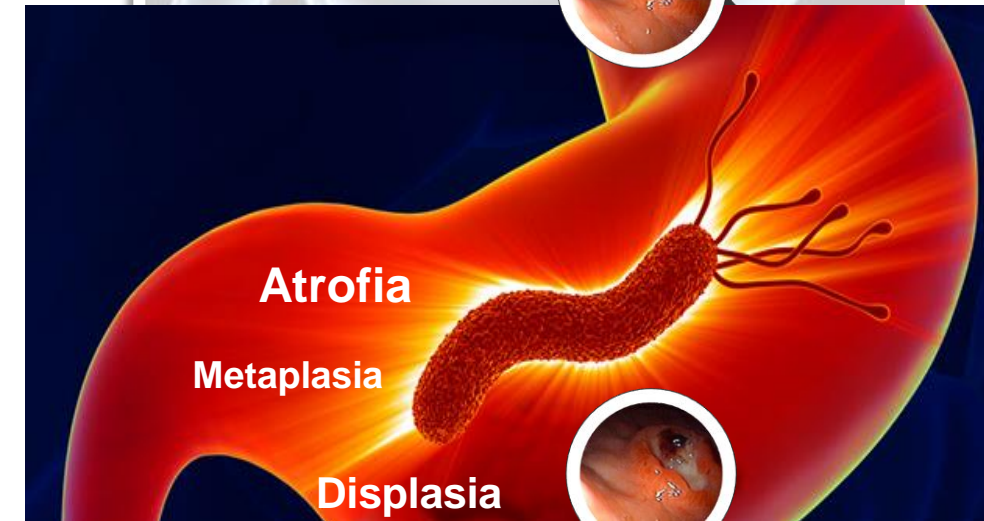
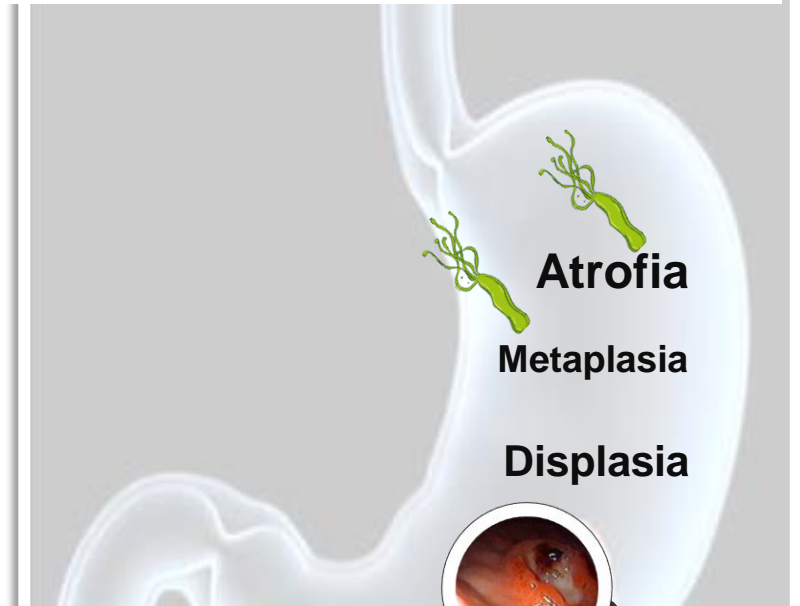
II Tecnofarma Adium Summit Bogotá junio 2-3, 2023



Atrofia y metaplasia intestinal Condiciones precursoras de cáncer gástrico: qué ¿hacer ?

“No *Hpylori* No cáncer”



William Otero MD, FAGA, FASGE, FACP
Profesor Titular de Medicina
Unidad de Gastroenterología
Universidad Nacional de Colombia
Hospital Universitario Nacional de Colombia

