

Rifaximina en Medicina Interna Porqué cuando y cómo?

William Otero Regino MD AGAF, ACPF

Profesor Titular de Medicina,

Director Posgrado Gastroenterología ,


Universidad Nacional de Colombia

Ex presidente Asociación Colombiana de Endoscopia Digestiva

Ex presidente Asociación Colombiana de Gastroenterología

Ex Presidente ACMI Capítulo Central





ACEITE DE COCO

USO CASERO

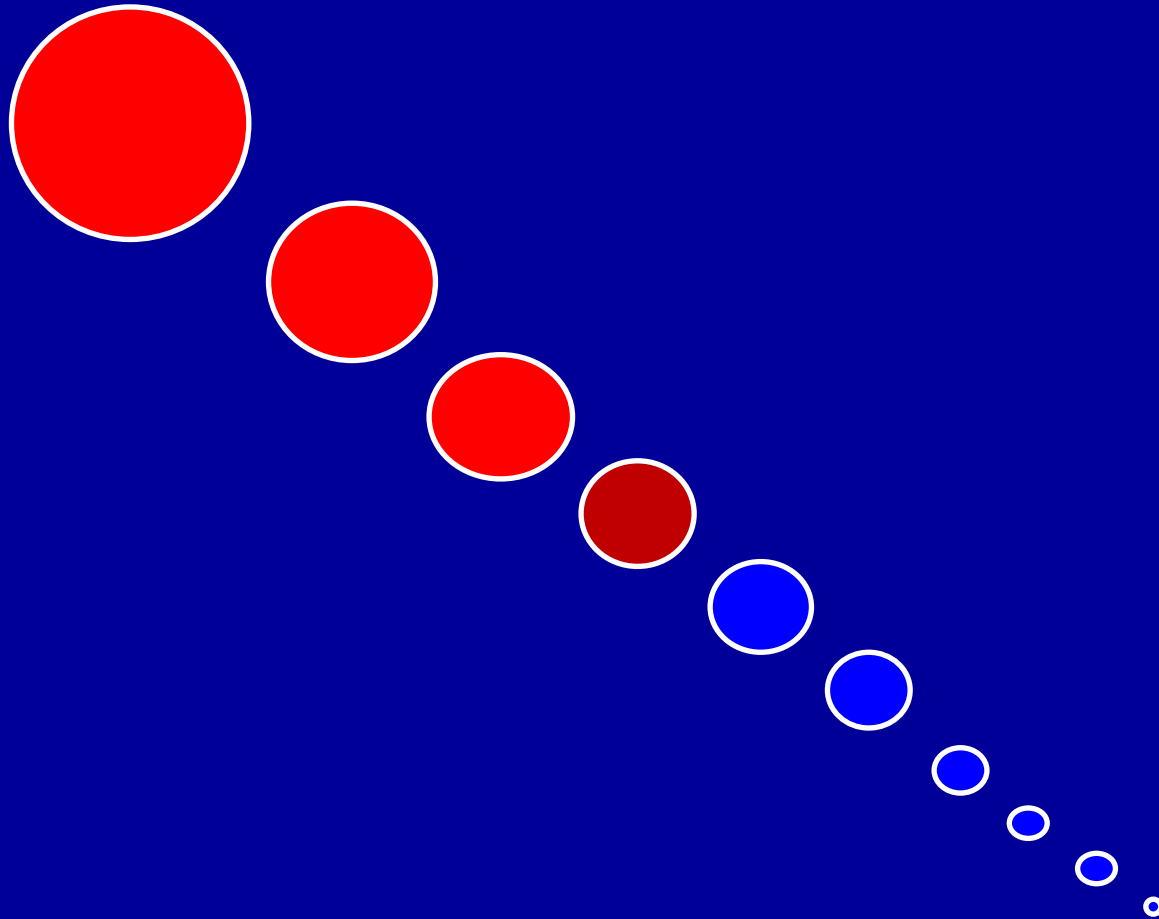
6	COMO ACEITE AROMATICO PARA VELAS HECHAS EN CASA
7	REDUCTOR DE MOHO
8	JABON DE MANOS CASERO
9	DETERGENTE
10	CERA PARA MUEBLES
6	ABRIR UNA CREMALLERA ATASCADA
7	ENGRASAR UNA CADENA
8	CERA PARA ZAPATOS
9	QUITAR UN CHICLE DEL CABELLO
10	PROTECTOR PARA MUEBLES

**74 usos
Adicionales**

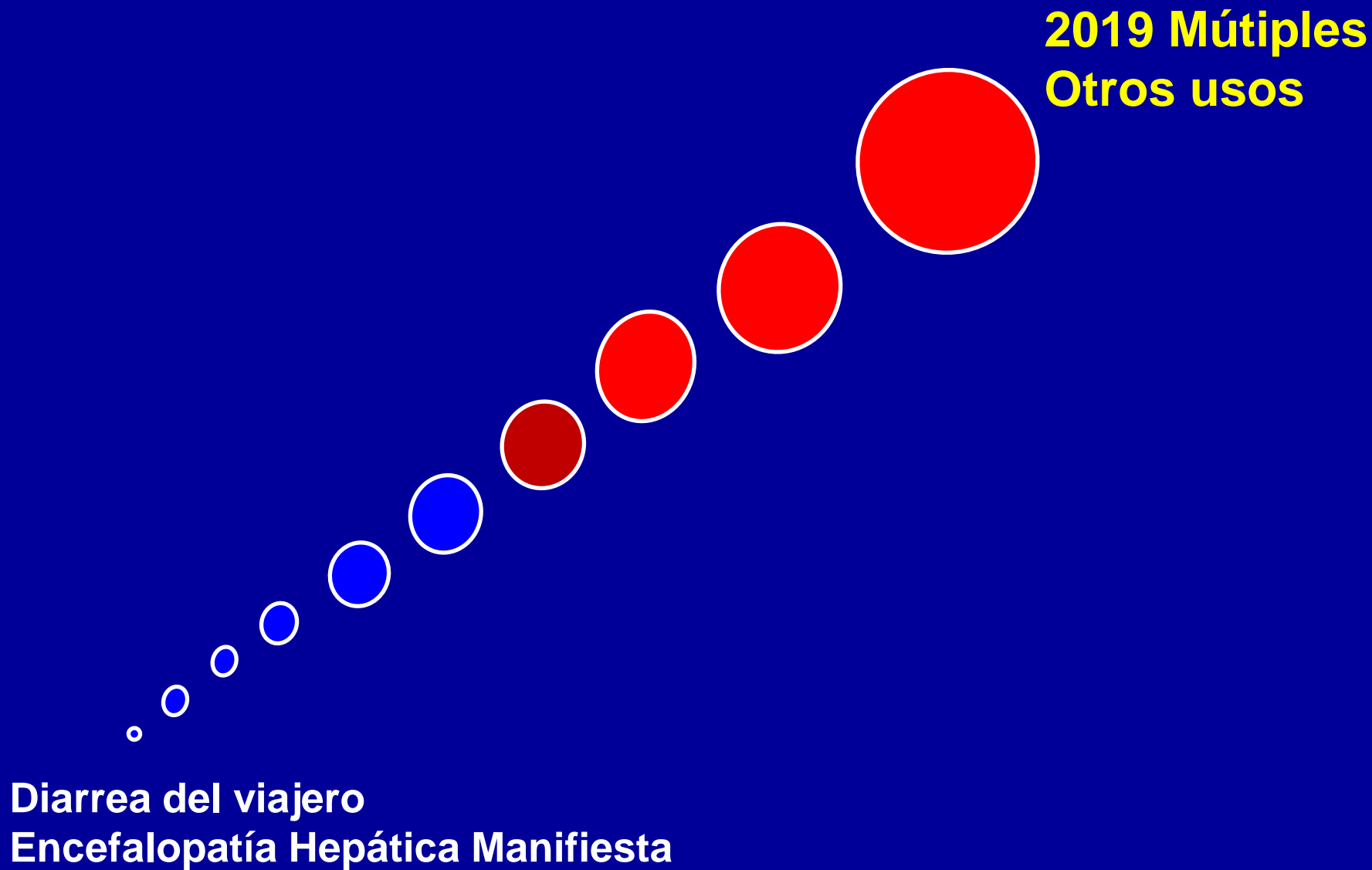
**Usos del aceite coco
en a piel y el pelo
Mascarilla
Desmaquillante
Hidratante...**



La vida usual de un antibiótico



Rifaximina es al contrario!






**Rifaximina
550 mg**

Rifaximina

1987 Aprobado Italia



**2018 Más de 50 países
Nuevos conocimientos
Nuevos usos**

DuPont HL, *Ann Intern Med* 2005;142:805-12
Xu D, *Gastroenterology* 2014;144:1478-87
Kogawa AC, *Crit Rev Anal Chem* 2018;48:459-66

Rifaximina

Aprobado Italia 1987,

2019: más de 50 países

Derivado de Rifamicina

Resiste el jugo gástrico

Solubilizada por sales biliares

Actividad antibiótica en Intestino delgado

En colon: *C. Difficile*

Inhibe RNA polimerasa dependiente DNA

Activo contra: Gram (+), Gram (-)

Aerobios y anaerobios

Absorción: < 0.4%

Efectos adversos similares a placebo

Cristal alfa polimorfo

Genéricos “amorfos”: se absorben (América Latina)

DuPont HL, Ann Intern Med 2005;142:805-12

Xu D, Gastroenterology 2014;144:1478-87

Kogawa AC, Crit Rev Anal Chem 2018;48:459-66

Rifaximina

Resistente al jugo gástrico

Biodisponibilidad < 0.4%

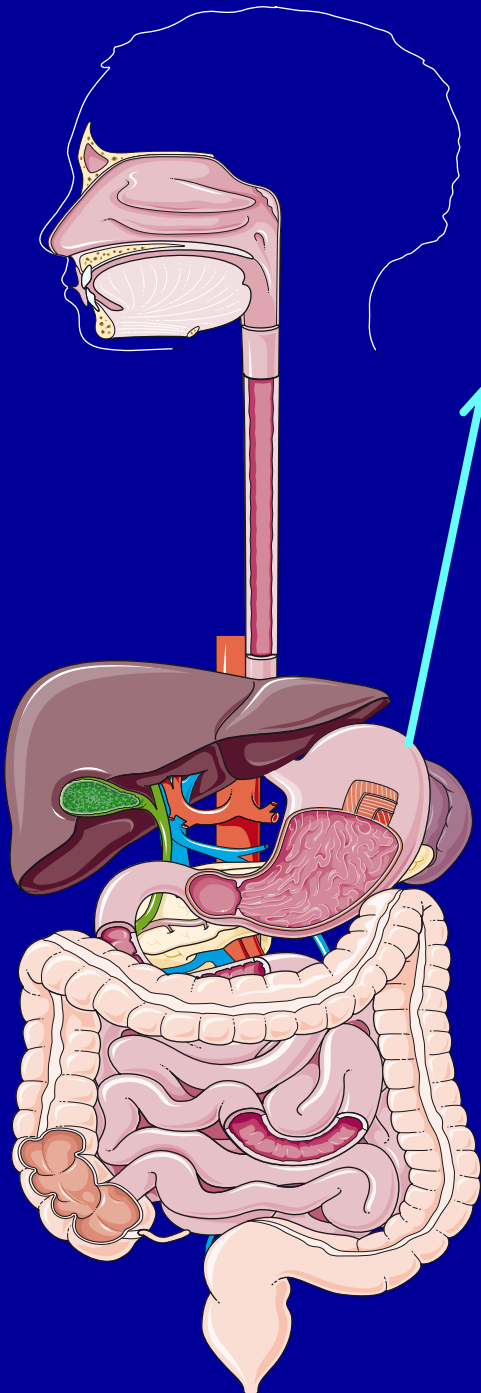
No requiere ajustes en disfunción hepática/renal

Pos 400 mg 2v/día

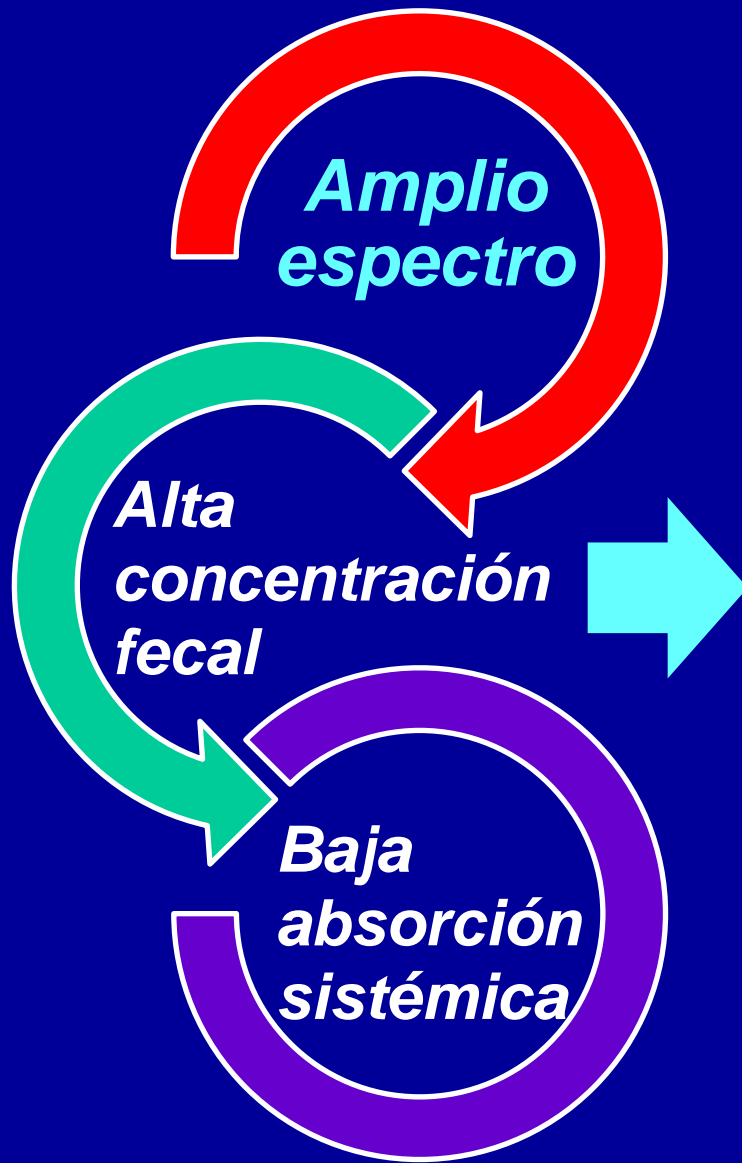concentración fecal:800mcg/gr

Jiang ZD, Antimicrob Agents Chemother 2000;44:2205-6

Adachi JA, Rev Anti infect Ag 2006;42:541-7



Rifaximina

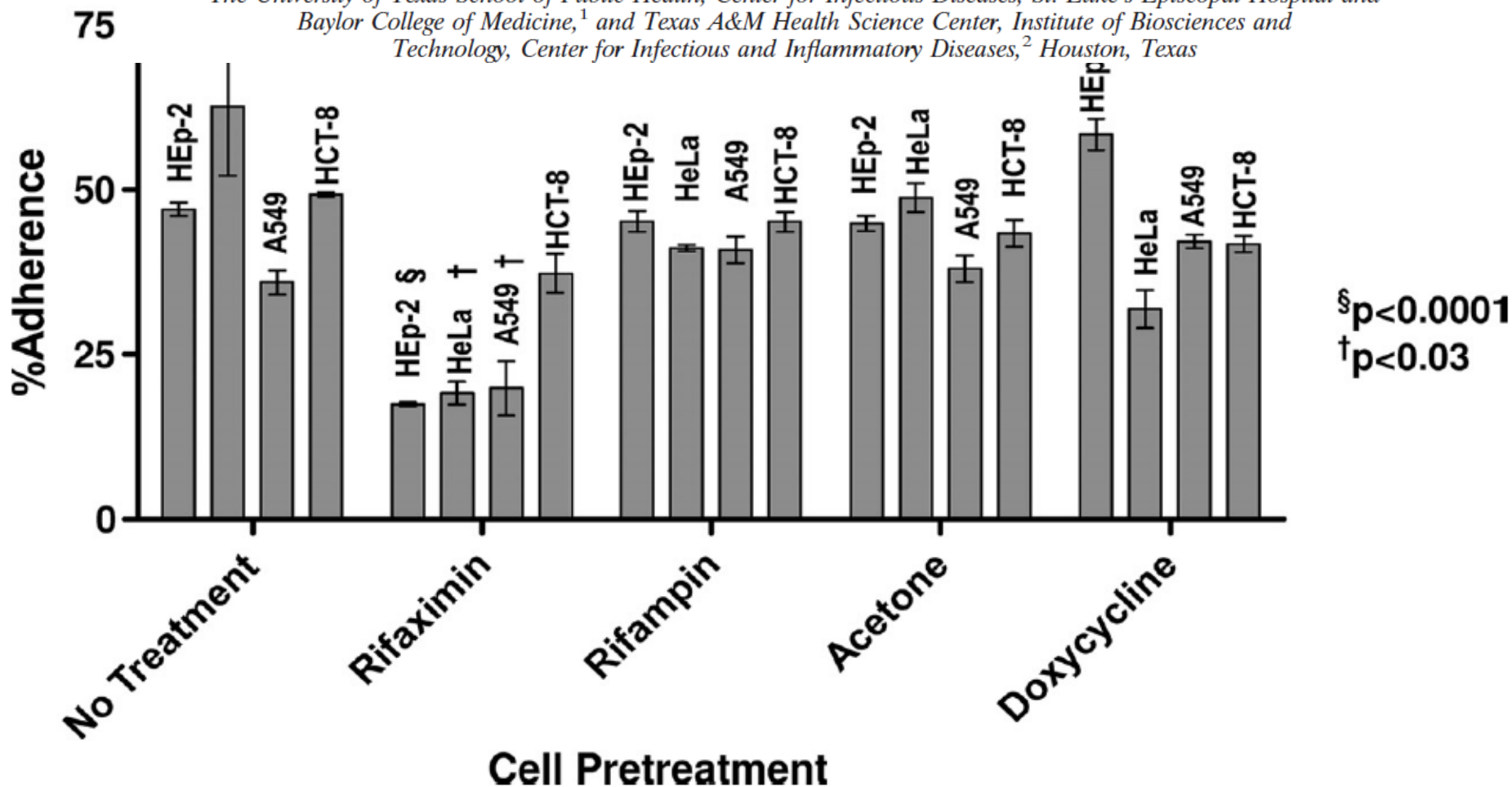


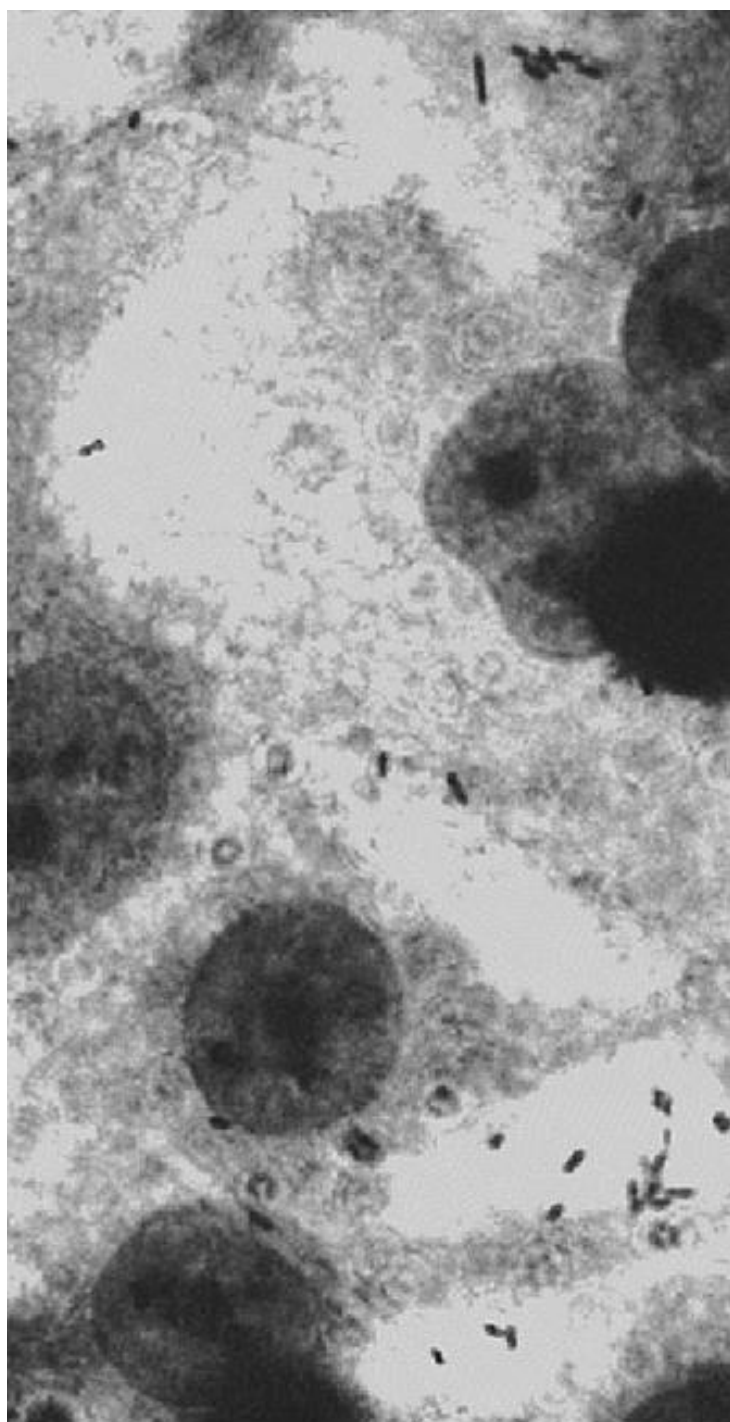
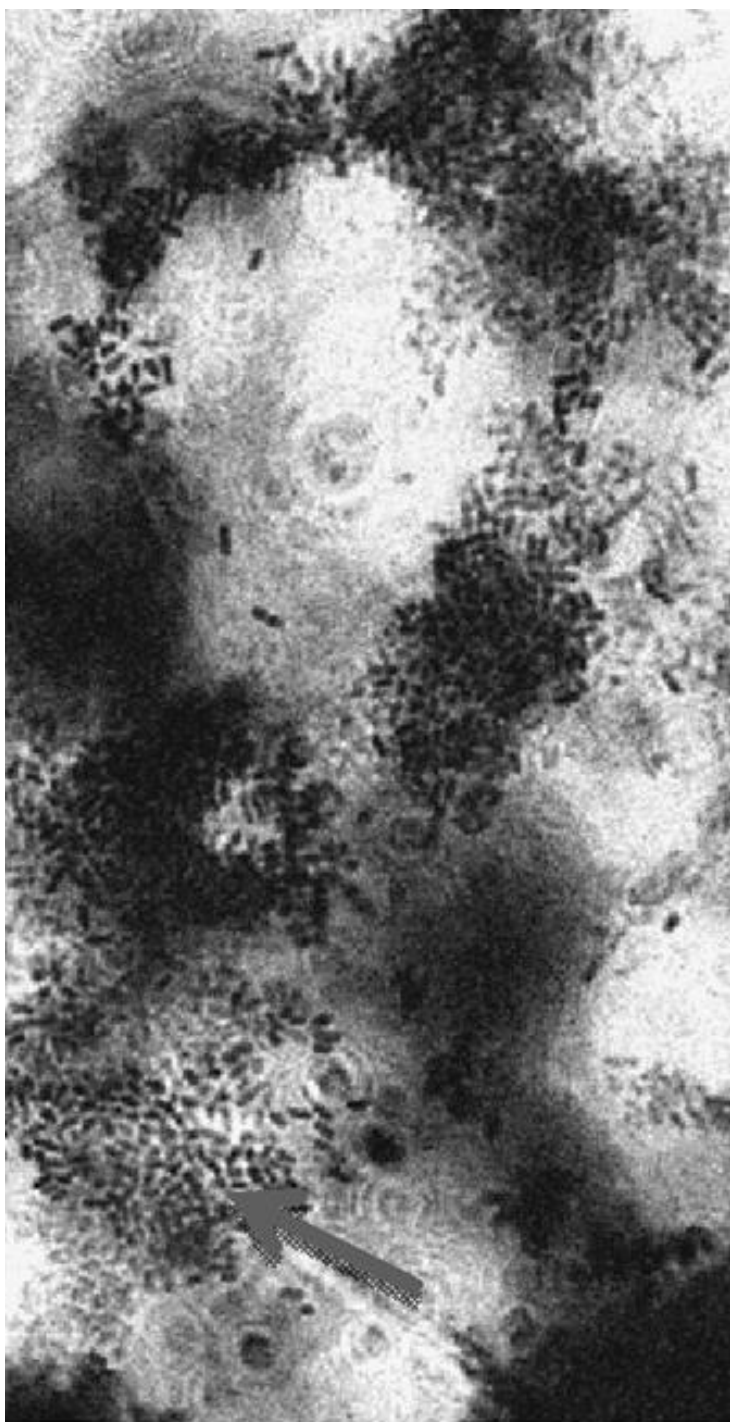
Antibiótico ideal para tratar enfermedades gastrointestinales

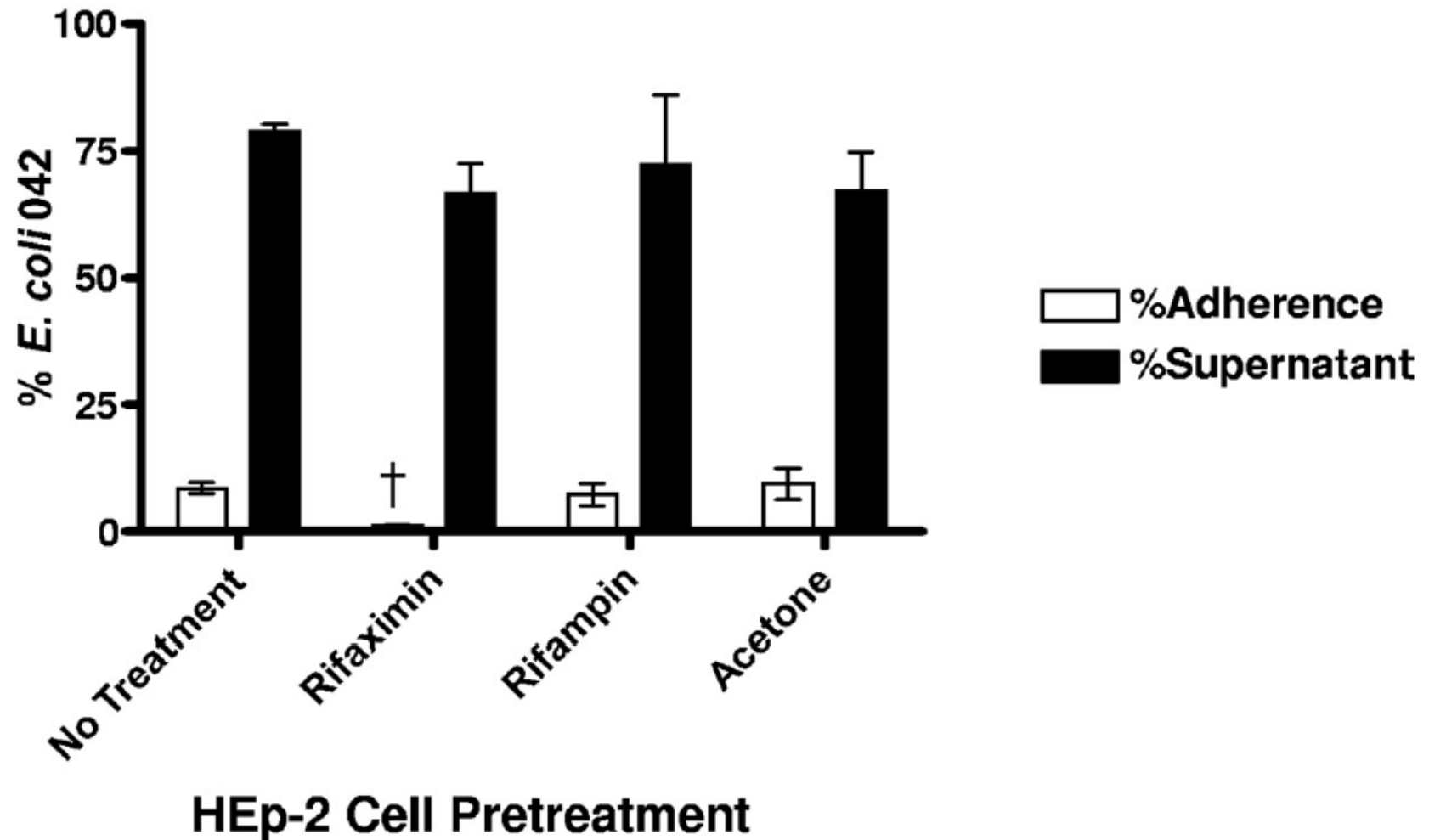
Pretreatment of Epithelial Cells with Rifaximin Alters Bacterial Attachment and Internalization Profiles[∇]

Eric L. Brown,^{1*} Qiong Xue,² Zhi-Dong Jiang,¹ Yi Xu,² and Herbert L. DuPont¹

The University of Texas School of Public Health, Center for Infectious Diseases, St. Luke's Episcopal Hospital and Baylor College of Medicine,¹ and Texas A&M Health Science Center, Institute of Biosciences and Technology, Center for Infectious and Inflammatory Diseases,² Houston, Texas





C

Cambios en la fisiología celular mediados por Rifaximina producen menor adhesión bacteriana y menor liberación de citoquinas inflamatorias

Rifaximin-Mediated Changes to the Epithelial Cell Proteome: 2-D Gel Analysis

Caroline Schrodt¹, Erin E. McHugh¹, Mary Ann Gawinowicz², Herbert L. DuPont^{1,3}, Eric L. Brown^{1*}

1 Center for Infectious Diseases, the University of Texas School of Public Health, Houston, Texas, United States of America, **2** Protein Core Facility, Columbia University College, New York, New York, United States of America, **3** Internal Medicine Services, St. Luke's Episcopal Hospital and Department of Medicine, Infectious Diseases Section, Baylor College of Medicine, Houston, Texas, United States of America

Abstract

Rifaximin is a semi-synthetic rifamycin derivative that is used to treat different conditions including bacterial diarrhea and hepatic encephalopathy. Rifaximin is of particular interest because it is poorly adsorbed in the intestines and has minimal effect on colonic microflora. We previously demonstrated that rifaximin affected epithelial cell physiology by altering infectivity by enteric pathogens and baseline inflammation suggesting that rifaximin conferred cytoprotection against colonization and infection. Effects of rifaximin on epithelial cells were further examined by comparing the protein expression profile of cells pretreated with rifaximin, rifampin (control antibiotic), or media (untreated). Two-dimensional (2-D) gel electrophoresis identified 36 protein spots that were up- or down-regulated by over 1.7-fold in rifaximin treated cells compared to controls. 15 of these spots were down-regulated, including annexin A5, intestinal-type alkaline phosphatase, histone H4, and histone-binding protein RbbP4. 21 spots were up-regulated, including heat shock protein (HSP) 90 α and fascin. Many of the identified proteins are associated with cell structure and cytoskeleton, transcription and translation, and cellular metabolism. These data suggested that in addition to its antimicrobial properties, rifaximin may alter host cell physiology that provides cytoprotective effects against bacterial pathogens.

Mini Rev Med Chem. 2015;16(3):200-5.

Rifaximin: An Antibiotic with Important Biologic Effects.

DuPont HL .

 **Author information**

Abstract

Rifaximin is a poorly absorbed rifamycin drug with unique pharmacokinetic properties: bile solubility making it highly active against pathogenic and non-pathogenic bacterial flora in the bile-rich small bowel and low water solubility making it active only against highly susceptible bacteria, primarily anaerobes, in the aqueous colon. The drug has anti-inflammatory gut mucosal stabilization properties that are important to its sustained effects in non-infectious diseases. Rifaximin is used chronically or recurrently for hepatic encephalopathy and diarrhea-predominant irritable bowel syndrome. Monitoring of long-term use of rifaximin for development of resistance and then determining whether developed resistance is associated with reduced efficacy are needed. Studies of changes of intestinal flora during therapy and the health implications of these changes are also needed.

**Antibiótico
Intestino
Delgado**

**Actividad
Microbiota
Funcion
Virulencia
Bacteriana**

**Activa el Receptor
Humano
Pregnano X,
Anti-inflamtorio**

Rifaximina

**Citoproteccòn
Intestinal
<< infecciones
intestinaes**

**Prevenccòn
Translocacòn
Bacteriana
>>>Lactobacilo**

**Actividad
inmuno-
Moduladora**

Gastroenterology 2014;146:484-496

Rifaximin Alters Intestinal Bacteria and Prevents Stress-Induced Gut Inflammation and Visceral Hyperalgesia in Rats

Dabo Xu, Jun Gao, Merritt Gilliland III, Xiaoyin Wu, Il Song, John Y. Kao, and Chung Owyang

Rifaximina

Excelentes oportunidades
terapéuticas



Efecto benéfico
En la microbiota

Actúa tópicamente
Decontaminación selectiva

>>> *Lactobacilo*

>>> *Bifidobacterium*

>>> *Faecalobacterium prausnitzii*

Soldi S, Clin Exp Gastroenterol 2015;8:309-25

Ponziani FR, Dig Dis 2016;34:269-78

Ponziani FT, World J Gastroenterol 2017; 23: 4491-4499

Rifaximina, “eubiótico”



<<<Roseburia

<<<Haemophilus

<<<Veillonela

<<<Streptococcus



*World Journal of
Gastroenterology*

Submit a Manuscript: <http://www.f6publishing.com>

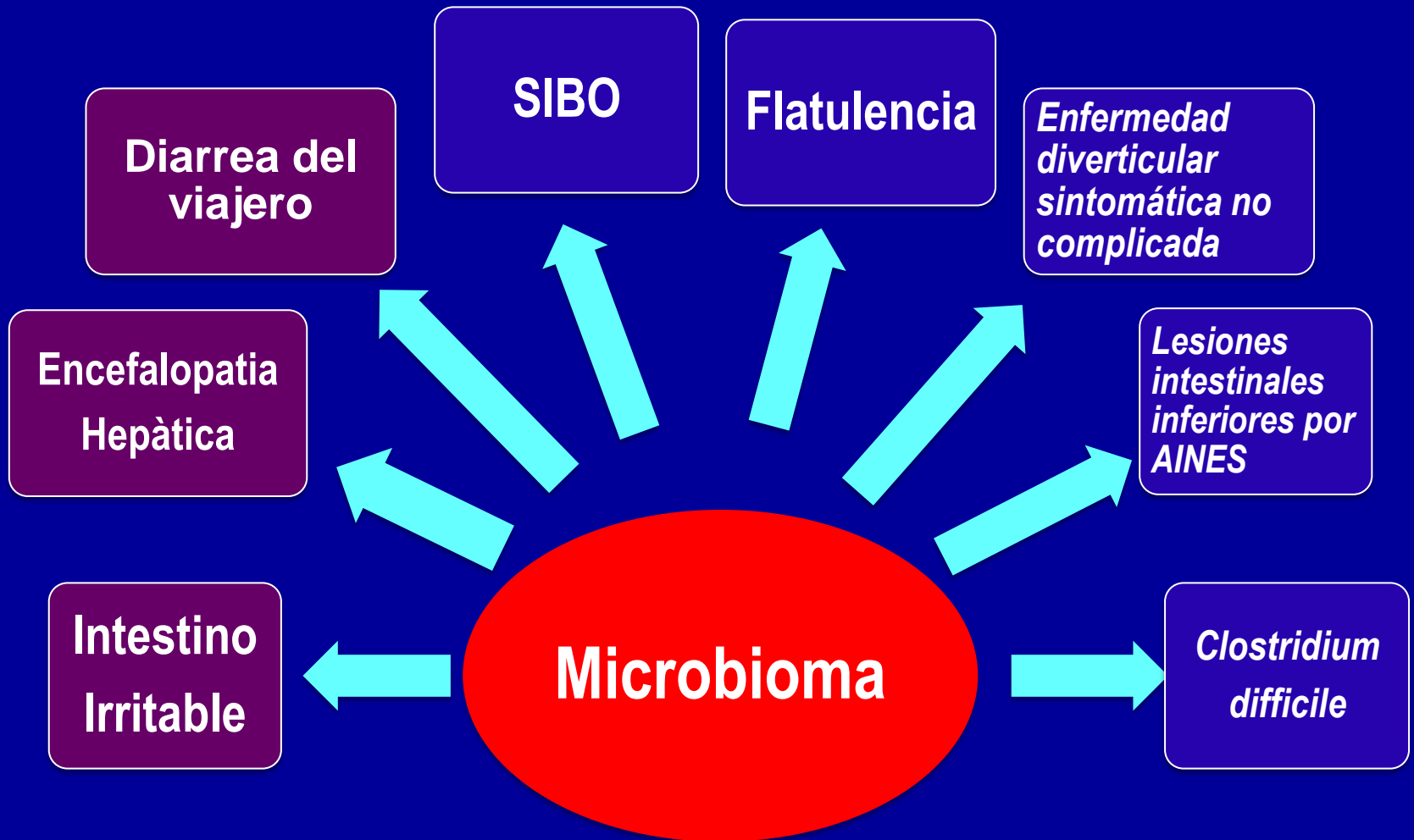
World J Gastroenterol 2017 July 7; 23(25): 4491-4499

DOI: 10.3748/wjg.v23.i25.4491

ISSN 1007-9327 (print) ISSN 2219-2840 (online)

REVIEW

Eubiotic properties of rifaximin: Disruption of the traditional concepts in gut microbiota modulation



Diarrea del viajero

INTRODUCTION — Travelers' diarrhea is the most common illness in persons traveling from resource-rich to resource-limited regions of the world [1,2]. Among travelers to such areas, 40 to 60 percent develop diarrhea [3]. Episodes of travelers' diarrhea are nearly always benign and self-limited, but symptoms may disrupt planned activities and result in health care visits for some travelers [4].

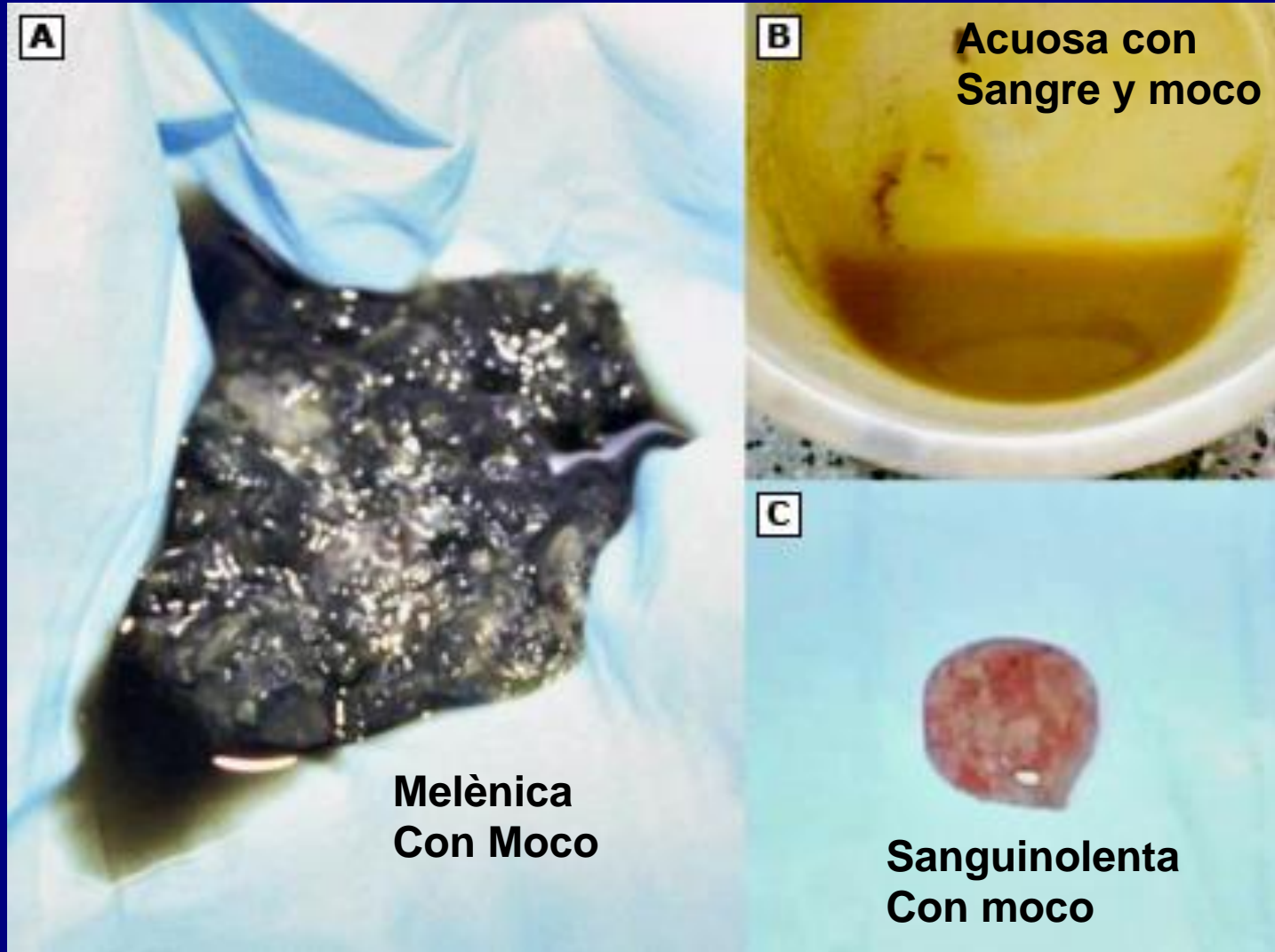
***E.Coli* enterotoxigénica**
Shigella spp
Resistencia a quinolona

LaRocque R, Up To date 2019

Diarrea acuosa



Diarrea invasiva



Rifaximina NO
Azitromicina: Si
Quinolonas: Si

LaRocque R, To Date 2019

**Diarrea acuosa sin
inflamación**



Nunca quinolonas!!!

Sindrome de Intestino irritable

SII, Criterios diagnósticos, Roma IV 2016

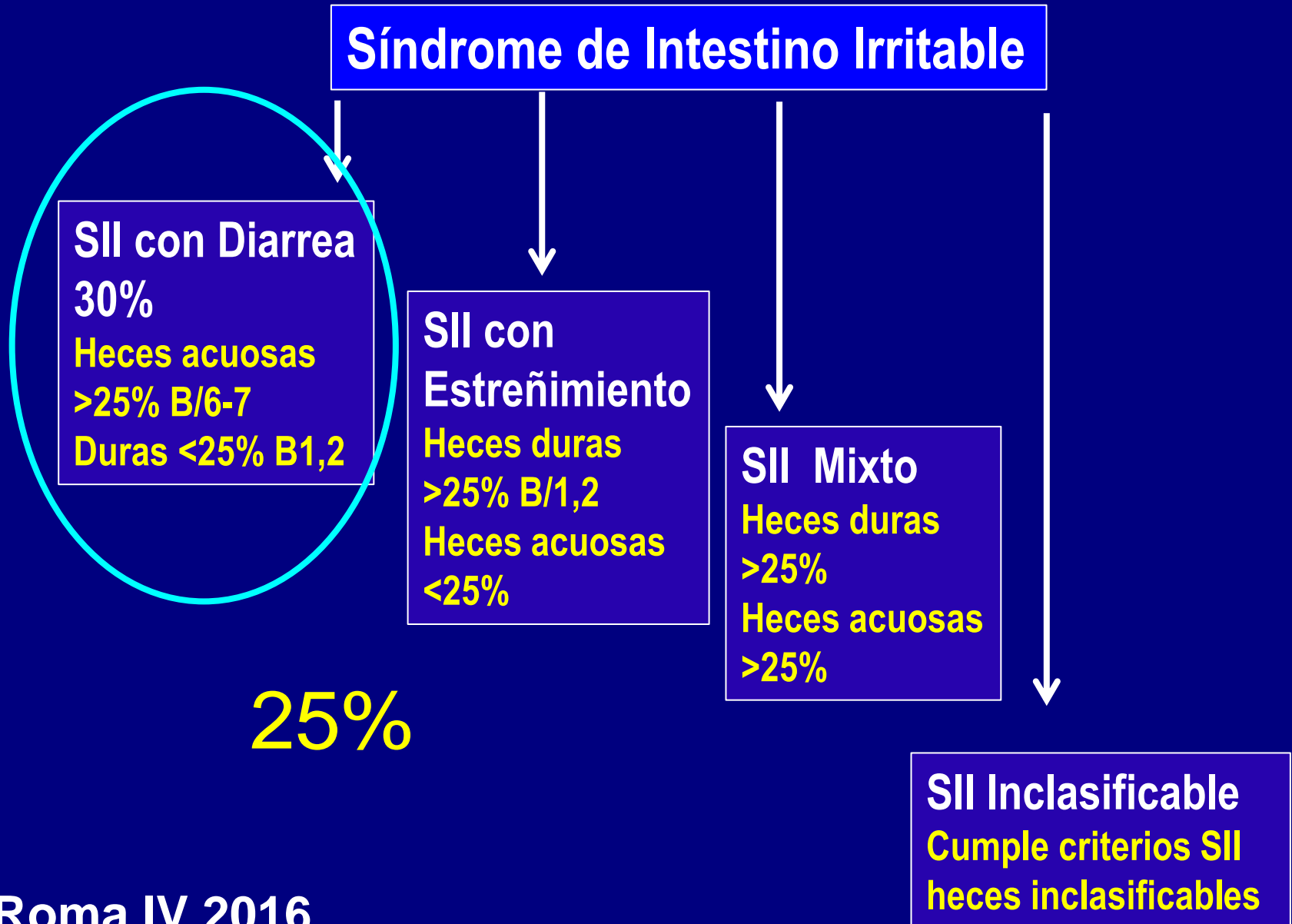
En ausencia de síntomas de alarma o patologías evidentes que expliquen los síntomas

Asociado a la Defecación

Cambio en la Frecuencia heces

Cambio en la Apariencia heces

Subtipos
Fisiopatología diferente



SII Diarrea predominante

Characterisation of faecal protease activity in irritable bowel syndrome with diarrhoea: origin and effect of gut transit

David Tooth,¹ Klara Garsed,² Gulzar Singh,² Luca Marciani,² Ching Lam,² Imogen Fordham,² Annie Fields,² Rawinder Banwait,² Melanie Lingaya,² Robert Layfield,¹ Maggie Hastings,³ Peter Whorwell,³ Robin Spiller²

Gut 2014;63:753–760

Immune Activation in Irritable Bowel Syndrome: Can Neuroimmune Interactions Explain Symptoms?

Hughes PA, *Am J Gastroenterol* 2013; 108:1066–1074

Instability of the faecal microbiota in diarrhoea-predominant irritable bowel syndrome

Ana Durbán¹, Juan J. Abellán¹, Nuria Jiménez-Hernández¹, Alejandro Artacho¹, Vicente Garrigues², Vicente Ortiz², Julio Ponce², Amparo Latorre^{1,3} & Andrés Moya^{1,3}

FEMS Microbiol Ecol 2013;86: 581–589

Mitochondrial ATP 6 and 8 polymorphisms in irritable bowel syndrome with diarrhea

Wang WF, et al *World J Gastroenterol* 2013; 19: 3847-3853

Low prevalence of 'classical' microscopic colitis in Asian Irritable Bowel Syndrome patients with diarrhoea

Hilmi et al. *BMC Gastroenterol* 2013, 13:80

Irritable Bowel Syndrome: Methods, Mechanisms, and Pathophysiology.
Genetic epidemiology and pharmacogenetics in irritable bowel syndrome
Camilleri M, *Am J Physiol Gastrointest Liver Physiol* 302: G1075–G1084, 2012.

SII diarrea predominante

Antiguos
Loperamida
Antidepresivos

<< Sales biliares
Colestiramina
Colestipol,
Colesevelam

Antagonistas 5HT3
Alosetrón
Ondansetrón
Ramosetrón

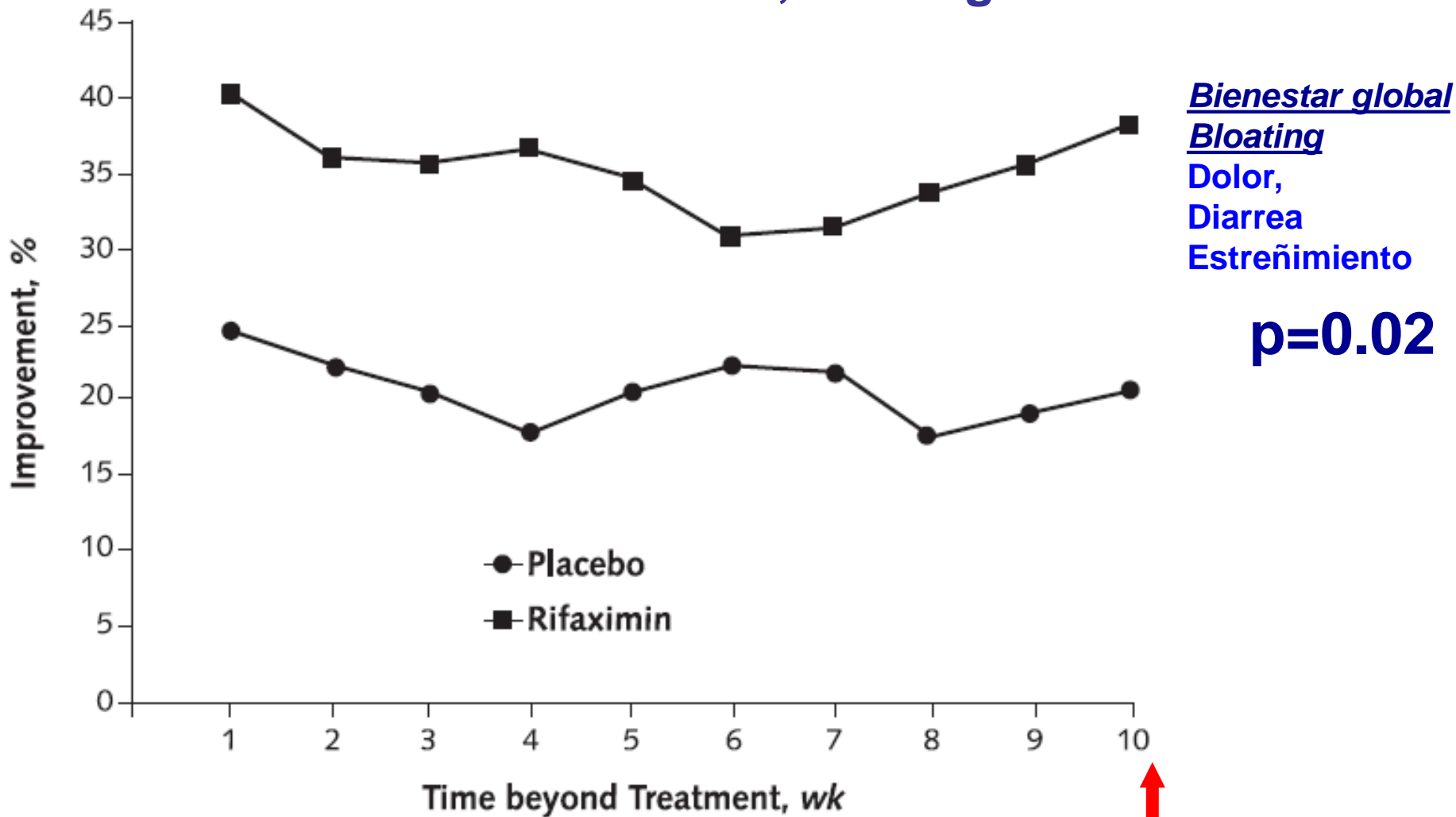
Dieta
<< FODMAP

Rifaximina
FDA: Mayo 28/15
550 mg 3v/dia, 14dias

Eluxadoline
(Agonista opioide)
100 mg 2v/día
NO en: pancreatitis
Disfunción de Oddi,
Hepatopatía crónica
FDA: Mayo 28,2015

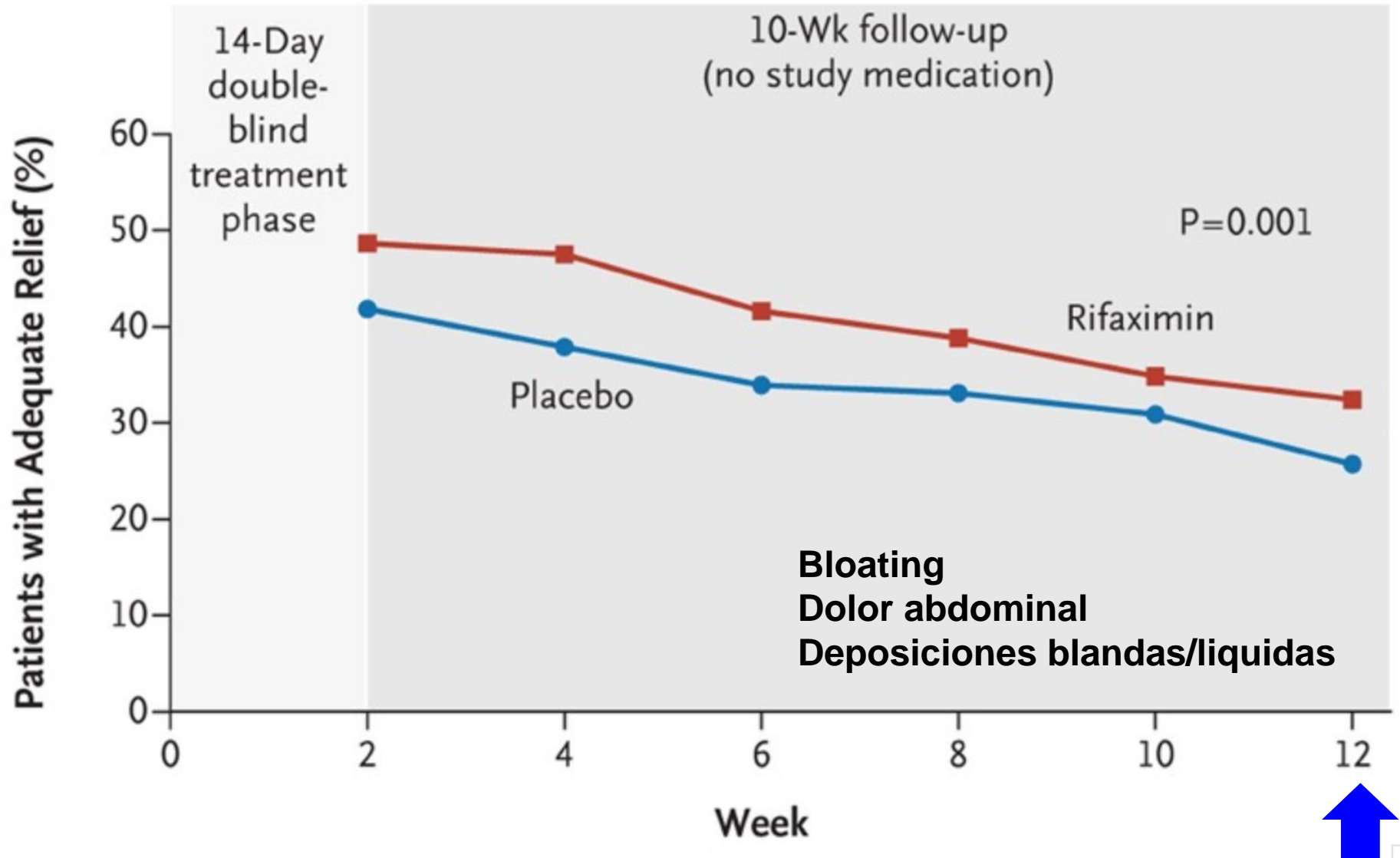
Pimentel M, Ann Intern Med 2006;145:557-63

Tto 10 días, 1200mg



Beneficio sostenido postratamiento!

550 mg tres veces al día 14 días



Pimentel M, N Engl J Med 2011;364:22-32

Rifaximina

2438
patients

completed 2 weeks of open-label rifaximin

44%
n=1074

responded to open-label treatment

TARGET 3

< 30% Dolor
50% <dias
Bristol 6,7

36%
n=382

did not experience
symptom recurrence
during 18 weeks of follow-up

59%
n=636

entered the double-blind phase
after symptom recurrence

308

patients
randomized

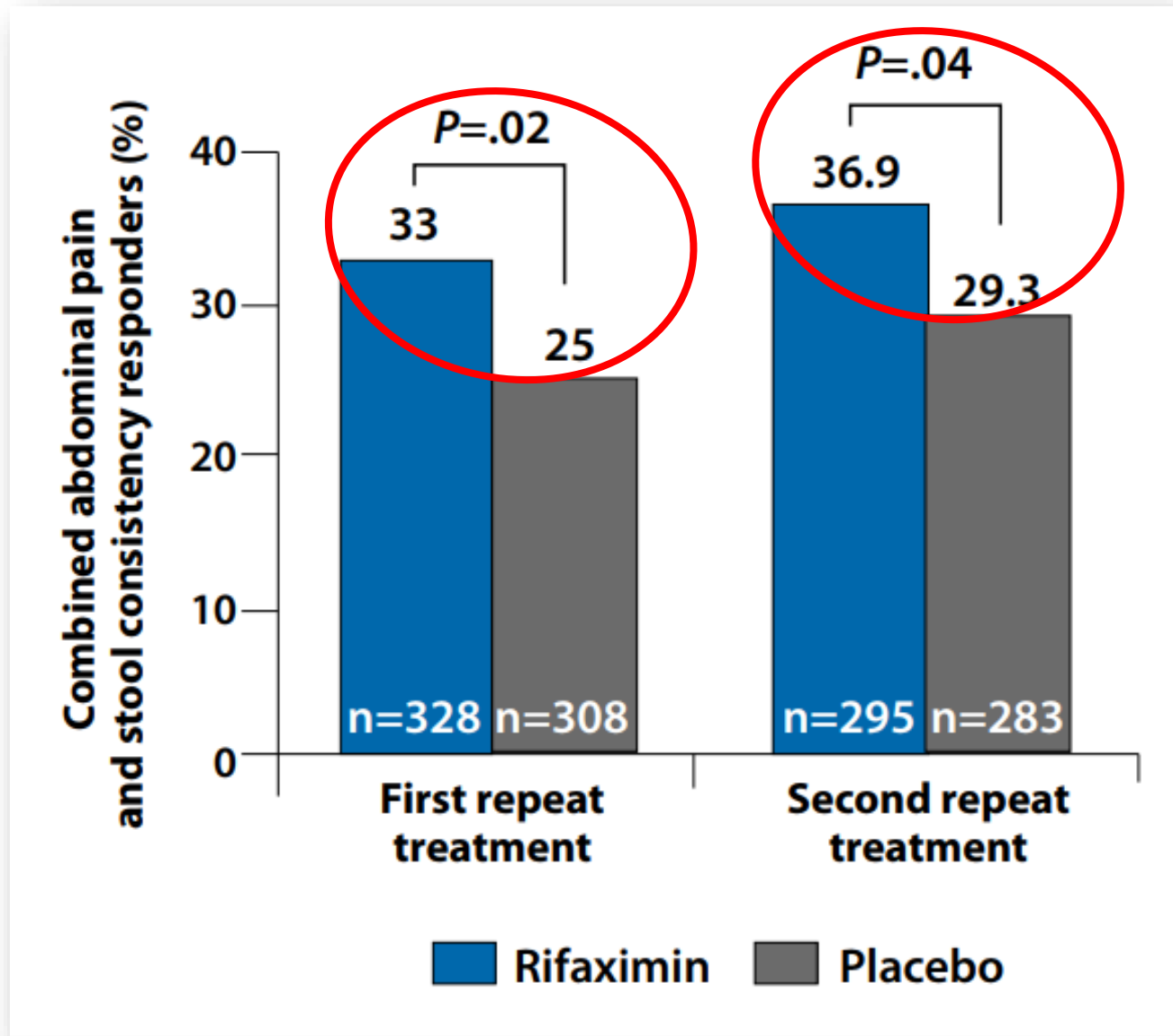
Placebo

328

patients randomized
to rifaximin

550 3v/d

Rifaximina -SII



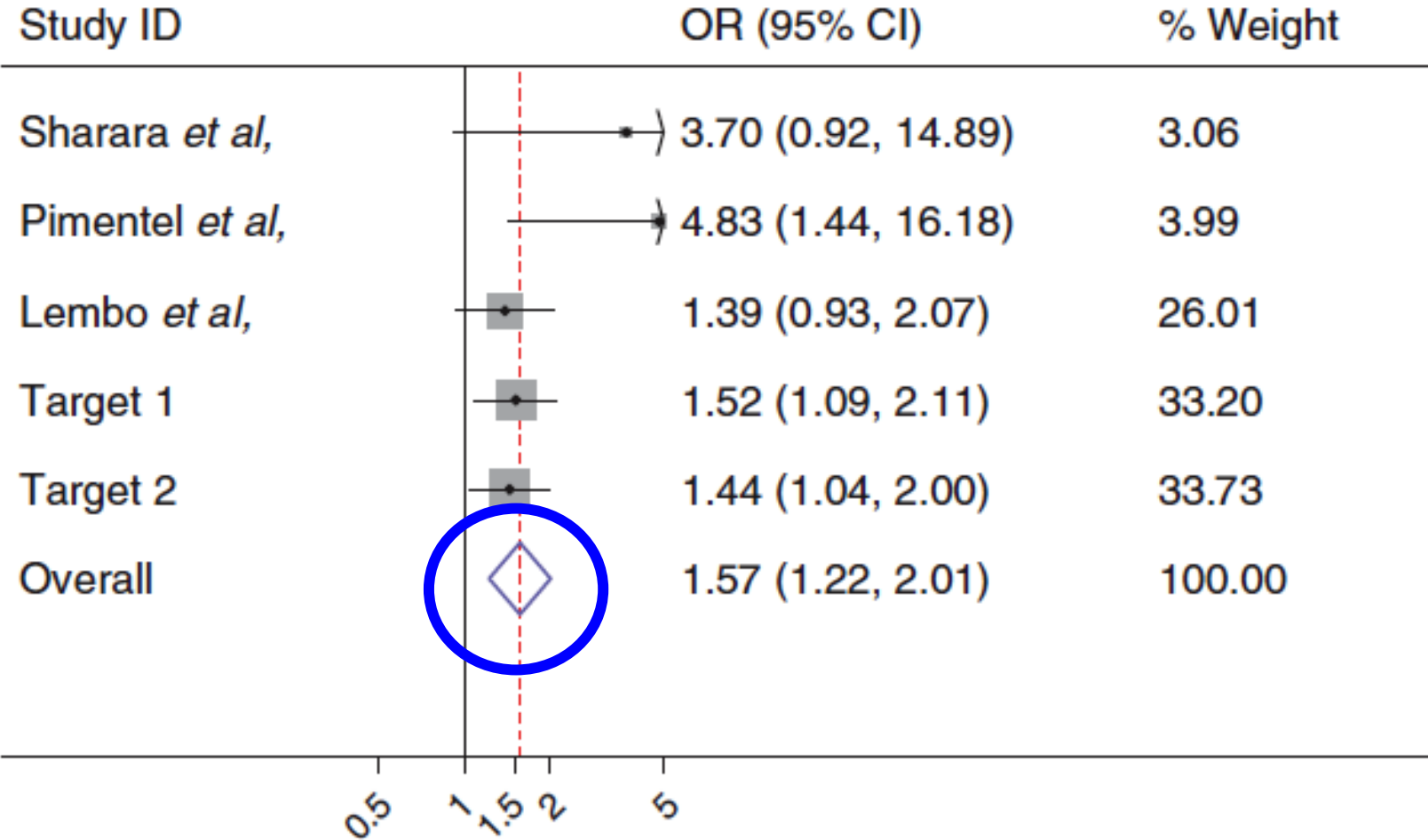
Lembo AJ, TARGET-3 study.

American College of Gastroenterology; October 17-22; Philadelphia, PA. Abstract 45.

The Efficacy and Safety of Rifaximin for the Irritable Bowel Syndrome: A Systematic Review and Meta-Analysis

Stacy B. Menees, MD, MSCRDSA¹, Monthira Maneerattannaporn, MD, MSCRDSA², Hyungjin Myra Kim, ScD¹ and William D. Chey, MD, AGAF, FACP, FACP¹

Am J Gastroenterol 2012;107:28-35



Seguridad comparativa en SII Diarrea

Safety and tolerability of rifaximin for the treatment of irritable bowel syndrome without constipation: a pooled analysis of randomised, double-blind, placebo-controlled trials

P. Schoenfeld^{*}, M. Pimentel[†], L. Chang[‡], A. Lembo[§], W. D. Chey^{*}, J. Yu[¶], C. Paterson[¶], E. Bortey[¶] & W. P. Forbes[¶]

Results

Patients receiving rifaximin ($n = 1103$) and placebo ($n = 829$) had a similar incidence of drug-related AEs (12.1% vs. 10.7%), serious AEs (1.5% vs. 2.2%), drug-related AEs resulting in study discontinuation (0.8% vs. 0.8%), gastrointestinal-associated AEs (12.2% vs. 12.2%) and infection-associated AEs (8.5% vs. 9.5%). There were no cases of *Clostridium difficile* colitis or deaths.

Aliment Pharmacol Ther 2014; 39: 1161–1168

TABLE 3. NNT and NNH Across IBS-D Trials^{32,46}

Treatment	Study duration	NNT	NNH ^a	NNT:NNH ratio
Alosetron	48 weeks	9	8	1.125
Eluxadoline	26 weeks	8.7	23.3	0.373
Rifaximin	10 weeks	10.6	8971	0.001

IBS-D indicates irritable bowel syndrome with prominent diarrhea; NNH, number needed to harm; NNT, number of patients needed to be treated. ^aNNH for alosetron is the reciprocal of the treatment difference between alosetron and placebo for any adverse effects; NNH for eluxadoline includes patients who experienced an adverse event(s) that prompted discontinuation.

Chey WD, et al. *Am J Gastroenterol*. 2004;99(11):2195-2203.
Lucak S, et al. *Ther Adv Gastroenterol*. 2017;10(2):253-275.

Encefalopatía Hepática 2019
Diagnóstico y tratamiento

Encefalopatía hepática

Incidencia y severidad

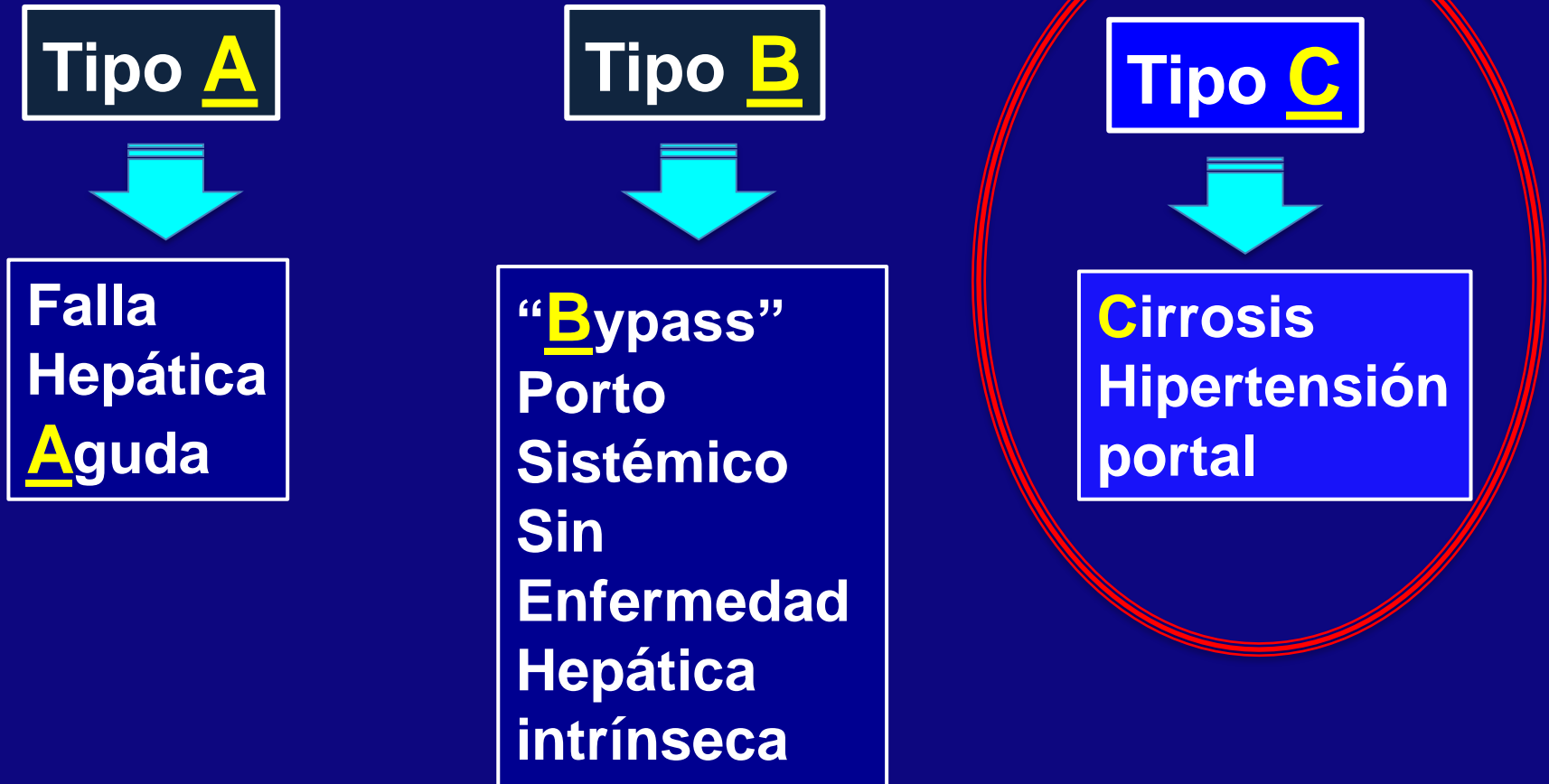


**Insuficiencia
Hepática**



**Hipertensión
Portal**

Encefalopatía Hepática



Encefalopatía Hepática

```
graph TD; A[Encefalopatía Hepática] --> B[Manifiesta]; A --> C[Subclínica/mínima]; B --> D["Clínicamente Evidente  
30-45%"]; C --> E["No Evidente  
Necesita pruebas  
Sicométricas especiales  
60-80%"];
```

Manifiesta

**Clínicamente Evidente
30-45%**

Subclínica/mínima

**No Evidente
Necesita pruebas
Sicométricas especiales
60-80%**




**Alteración calidad de vida
Incapacidad funcional diaria
>mortalidad**

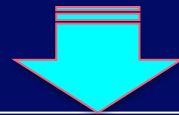
**Poodad F, Aliment Pharmacol Ther 2007;25 (supp.1):3-9
Bajaj JS, Am J Gastroenterol 2009;104:898-905
Groeneweg M, Hepatology 1998;28:45-9**

Encefalopatía hepàtica


Patogénesis



Desconocida



NH₃/+



**Neurotoxina fundamental
1896**

EH

Tratamiento

**No existe tratamiento específico!
Se ignora la historia natural**

Dirigido al intestino

Reducir, Inhibir la producción NH_3/H^+

Aumentar la eliminación de NH_3/H^+

Piedra angular del tratamiento



Lactulosa
Rifaximina

Nonabsorbable Disaccharides for Hepatic Encephalopathy: A Systematic Review and Meta-Analysis

Lise L. Gluud,¹ Hendrik Vilstrup,² and Marsha Y. Morgan³

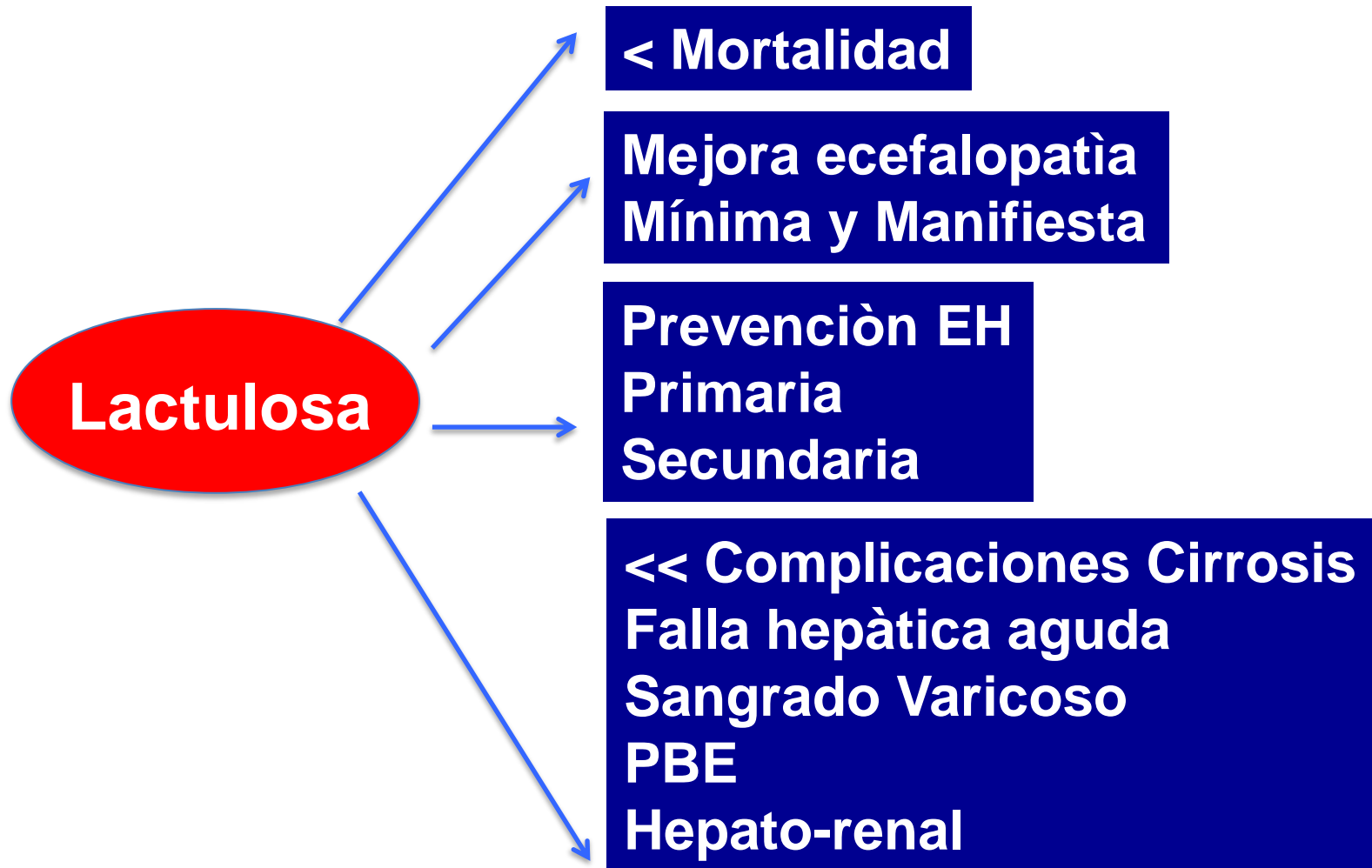
Hepatology 2016;64:908-922

**Nueva evidencia favorece
La LACTULOSA en todos
Los escenarios!!**

Nonabsorbable Disaccharides for Hepatic Encephalopathy: A Systematic Review and Meta-Analysis

Lise L. Glud,¹ Hendrik Vilstrup,² and Marsha Y. Morgan³

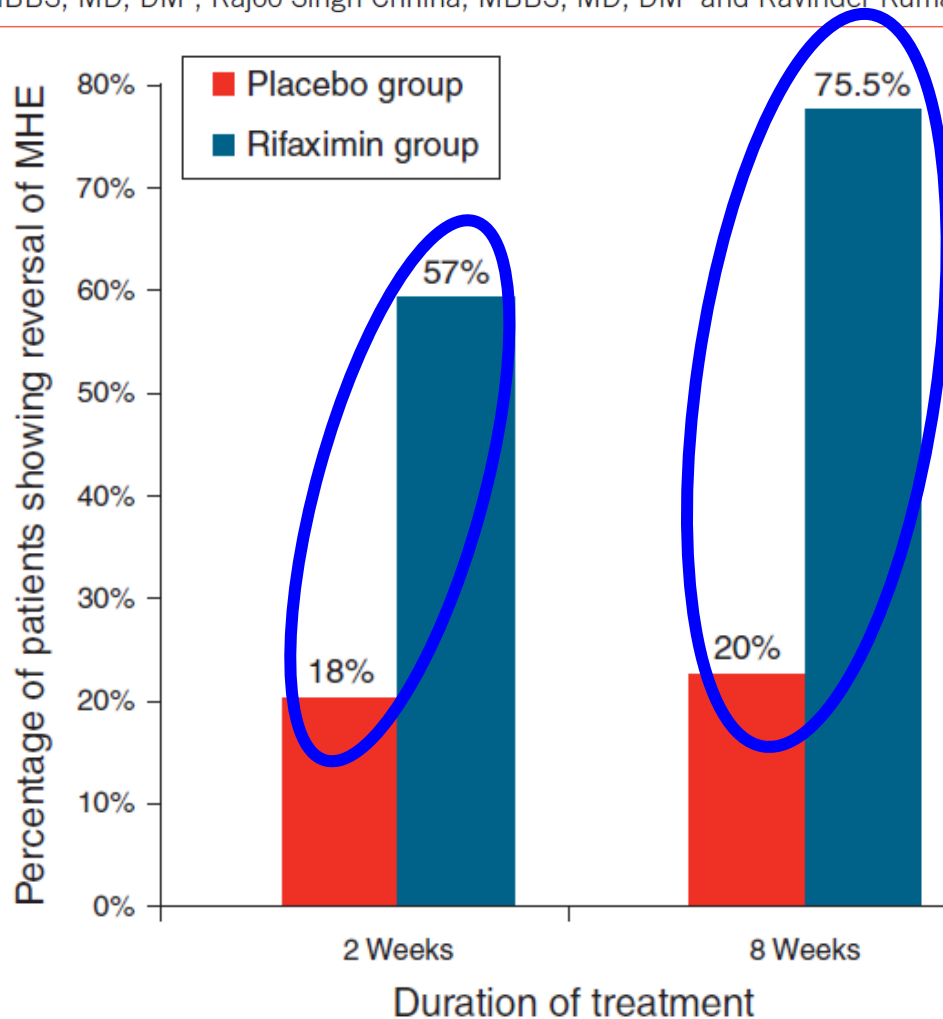
Hepatology 2016;64:908-922



Rifaximina

Rifaximin Improves Psychometric Performance and Health-Related Quality of Life in Patients With Minimal Hepatic Encephalopathy (The RIME Trial)

Sandeep Singh Sidhu, MBBS, MD, DM¹, Omesh Goyal, MBBS, MD, DM¹, Bholeshwar Prashad Mishra, MBBS, PhD², Ajit Sood, MBBS, MD, DM¹, Rajoo Singh Chhina, MBBS, MD, DM¹ and Ravinder Kumar Soni, MBBS, MD³



Encefalopatía hepática

Rifaximina

20 estudios clínicos

**Relación riesgo/beneficio:
favorable**

Williams R, Rev Gastroenterol Disord 2005;5 (Suppl1): S10-18

Encefalopatía hepática

Seguimiento ambulatorio

Prevención secundaria

The NEW ENGLAND JOURNAL of MEDICINE

ESTABLISHED IN 1812

MARCH 25, 2010

VOL. 362 NO. 12

Rifaximin Treatment in Hepatic Encephalopathy

Nathan M. Bass, M.B., Ch.B., Ph.D., Kevin D. Mullen, M.D., Arun Sanyal, M.D., Fred Poordad, M.D., Guy Neff, M.D., Carroll B. Leevy, M.D.,* Samuel Sigal, M.D., Muhammad Y. Sheikh, M.D., Kimberly Beavers, M.D., Todd Frederick, M.D., Lewis Teperman, M.D., Donald Hillebrand, M.D., Shirley Huang, M.S., Kunal Merchant, Ph.D., Audrey Shaw, Ph.D., Enoch Bortey, Ph.D., and William P. Forbes, Pharm.D.

	Placebo	RFX	OR	p
Recurrencia 6 M%	45	22.1	0.42 (0.28-0.64)	<0.001
Pacientes/Hospital.	22.6	13.6	0.5 (0.29-0.87)	<0.01

Rifaximin Is Safe and Well Tolerated for Long-term Maintenance of Remission From Overt Hepatic Encephalopathy

Kevin D. Mullen,^{*} Arun J. Sanyal,[‡] Nathan M. Bass,[§] Fred F. Poordad,^{||}
Muhammad Y. Sheikh,[¶] R. Todd Frederick,[#] Enoch Bortey,^{**} and William P. Forbes^{**}

Clin Gastroenterol Hepatol. 2014;12:1390-7.

BACKGROUND & AIMS:

Rifaximin is a gut-selective, oral antimicrobial agent shown to reduce the recurrence of overt hepatic encephalopathy (HE) and HE-related hospitalizations in a 6-month, randomized, controlled trial (RCT). We performed a phase 3, open-label maintenance study to assess the safety and rate of hospitalization with long-term rifaximin use.

METHODS:

We conducted a 24-month, open-label maintenance study of rifaximin (550 mg, twice daily) in patients with HE who participated in the previous RCT of rifaximin or new patients enrolled from March 2007 to December 2010. Safety was assessed (adverse events, clinical laboratory parameters) for the integrated population of all patients, who were given rifaximin 550 mg twice daily (all-rifaximin population, N = 392). Safety and hospitalization data were compared between the group given placebo in the original RCT (n = 159) and those given rifaximin (n = 140).

RESULTS:

In the all-rifaximin population, the median exposure to rifaximin was 427.0 days (range, 2–1427 d), with 510.5 person-years of exposure. The profile and rate of adverse events with long-term rifaximin treatment were similar to those of the original RCT. There was no increase in the rate of infections, including with *Clostridium difficile*, or development of bacterial antibiotic resistance.

Rates of hospitalizations with long-term rifaximin administration remained low: the HE-related hospitalization rate, normalized for exposure (0.21; all-rifaximin population), was similar to that of the rifaximin group in the original RCT (0.30), and lower than that for the placebo group (0.72).

CONCLUSIONS:

Long-term treatment (≥ 24 mo) with rifaximin (550 mg, twice daily) appears to provide a continued reduction in the rate of HE-related and all-cause hospitalization, without an increased rate of adverse events. ClinicalTrials.gov number: NCT00686920.

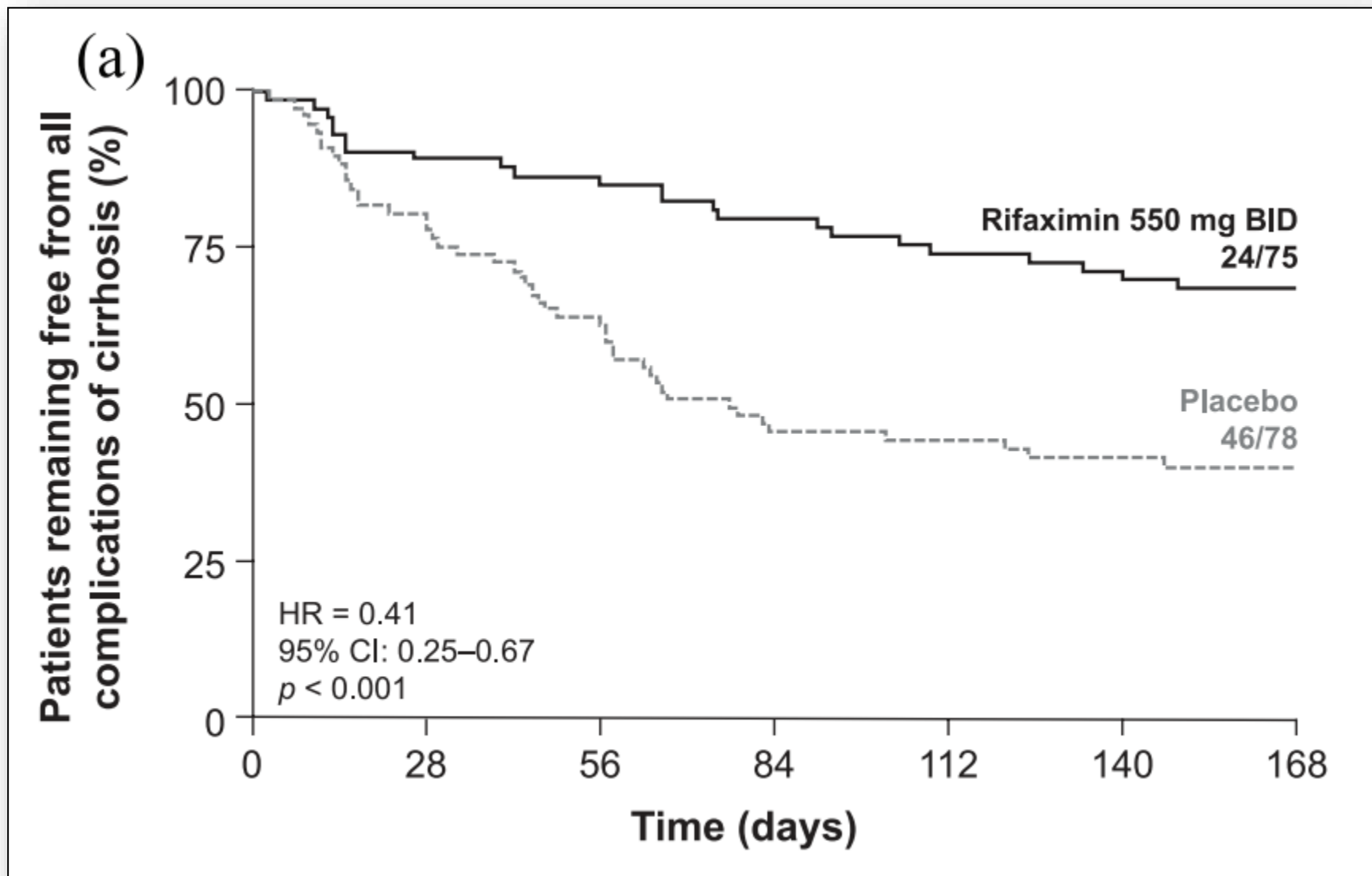
Rifaximin has the potential to prevent complications of cirrhosis

Steven L. Flamm, Kevin D. Mullen, Zeev Heimanson and Arun J. Sanyal

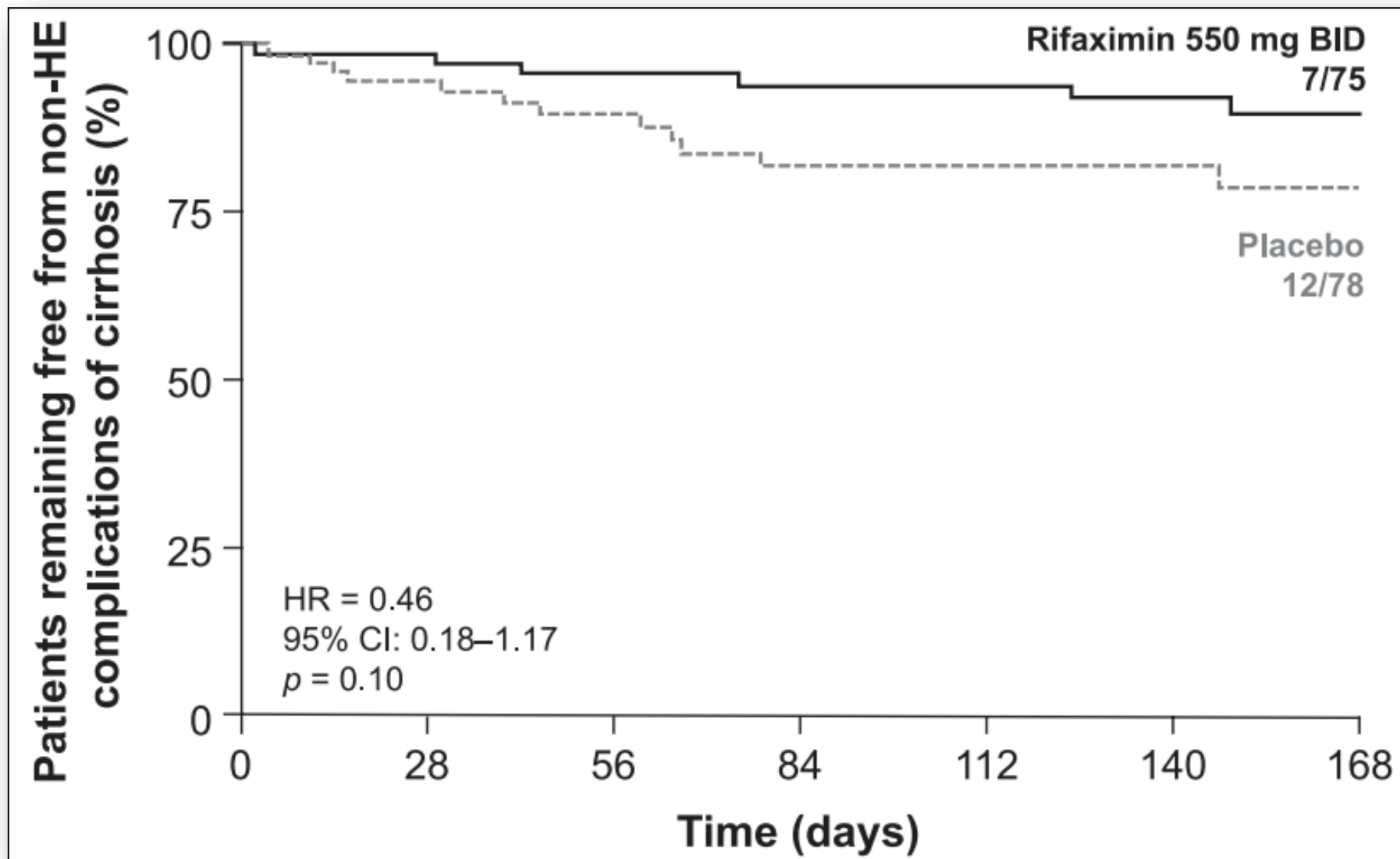
Rifaximina	n= 140
Placebo	n= 159

Ther Adv Gastroenterol 2018 Sep 28;11:1756284818800307

Pacientes cirróticos libres de complicaciones



Pacientes cirróticos libres de complicaciones Diferentes a encefalopatía



Flatulencia

Flatulencia


Diagnóstico

➤ **20 Flatos
al día !**

**Bacterias
Intestinales**

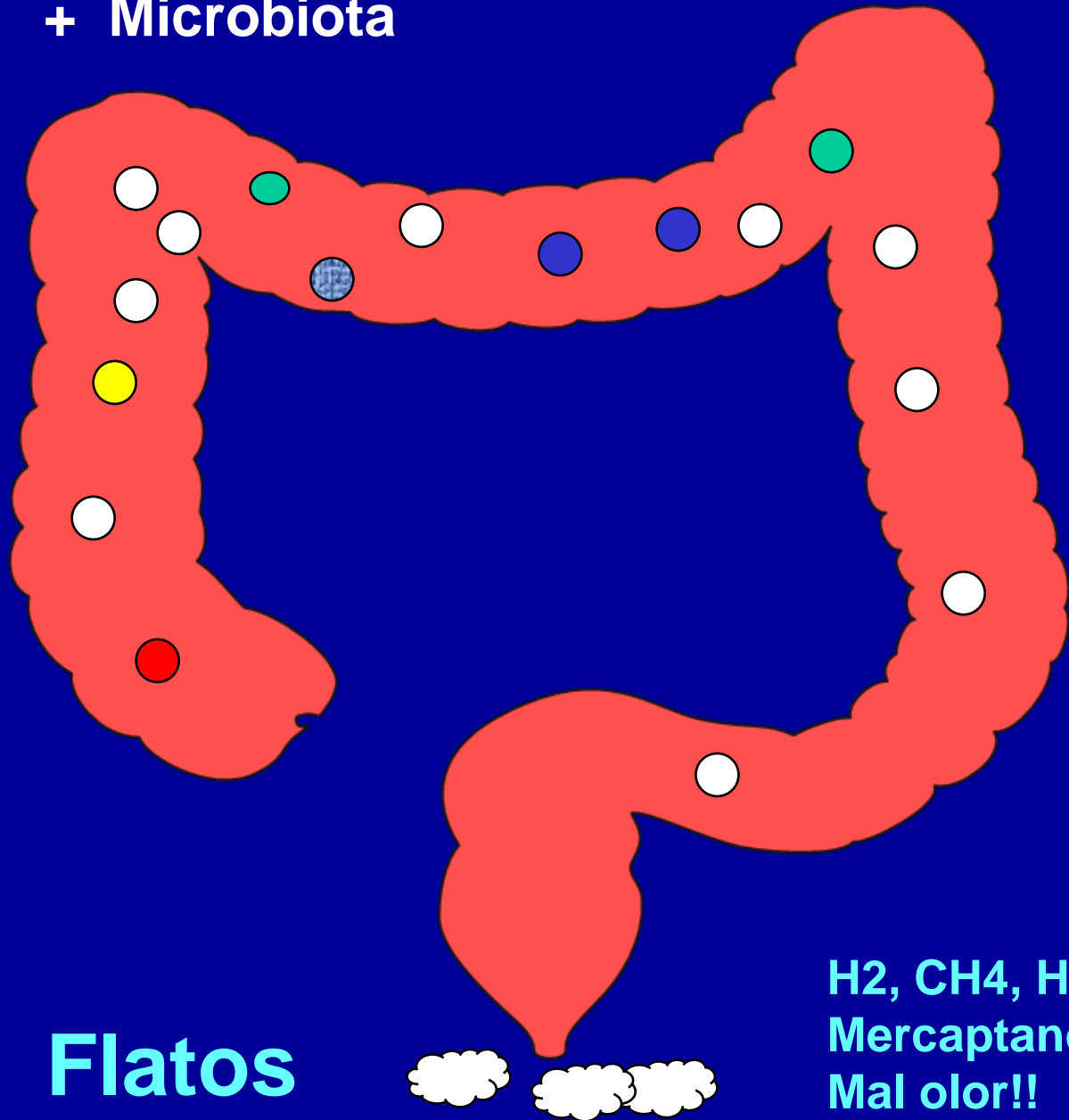
+

**Alimentos
Fermentables**



Gas

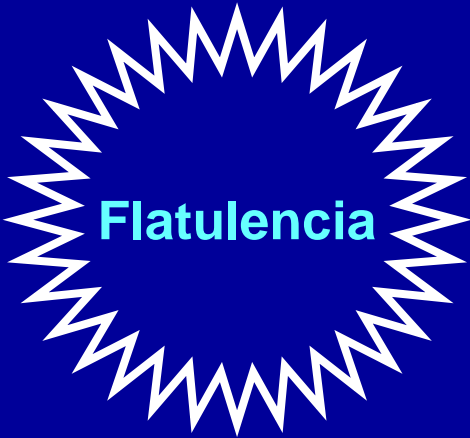
Residuos fermentables NO ABDORBIDOS + Microbiota



Flatos

H₂, CH₄, HS
Mercaptanos
Mal olor!!

Dieta




Flatulencia




Bismuto



Rifaximina



Mal olor



Rifaximina 400 mg 2v/día/10d

< Flatulencia
Mejoría asociada
con < producción H2

Sharara AI, Am J Gastroenterol 2006;101:326-33

Rifaximina 400 mg 2v/día/7d vs carbón activado 400mg2v/d/7d

Di Stefano M, Aliment Pharmacol Ther 2000;14:1001-8

Rifaximina vs Carbón

< excreción H₂: $p < 0.05$

< expulsión de flatos $p < 0.05$

< Diámetro de la cintura $p < 0.05$

Los flatos

NO mejoran con Carbón activado o Remedios populares

Son un problema social y medico <<autoestima

La evidencia favorece su tratamiento con: DIETA, Rifaximina!

**Los flatos excesivos, hay que controlarlos
Pueden acabar con el matrimonio, aunque
lleve muchos años**



Observaciones no publicadas

Rifaximina 550 mg tres veces al día 10-14 día



Más económico que
Un divorcio

Rifaximina: Mejora
el amor de pareja !!

Sobrecrecimiento bacteriano del Intestino Delgado (SIBO)

Sobrecrecimiento bacteriano del ID (SIBO)

**Exceso de bacterias colónicas
en el intestino delgado**



**Síntomas intestinales
Mala-absorción**

**Inducción y exacerbación
De enfermedades
Extra-intestinales**

SIBO


Estasis del Intestino delgado



Comunicación anormal GI superior-GI inferior



Asociación con Entidades multifactoriales



Causas anatómicas

Diverticulosis ID
Asas ciegas QX
Estenosis: cirugía
Crohn, radioterapia
Motilidad Alterada
Diabetes mellitus
Esclerodermia
Cirugía, Crohn
Radioterapia

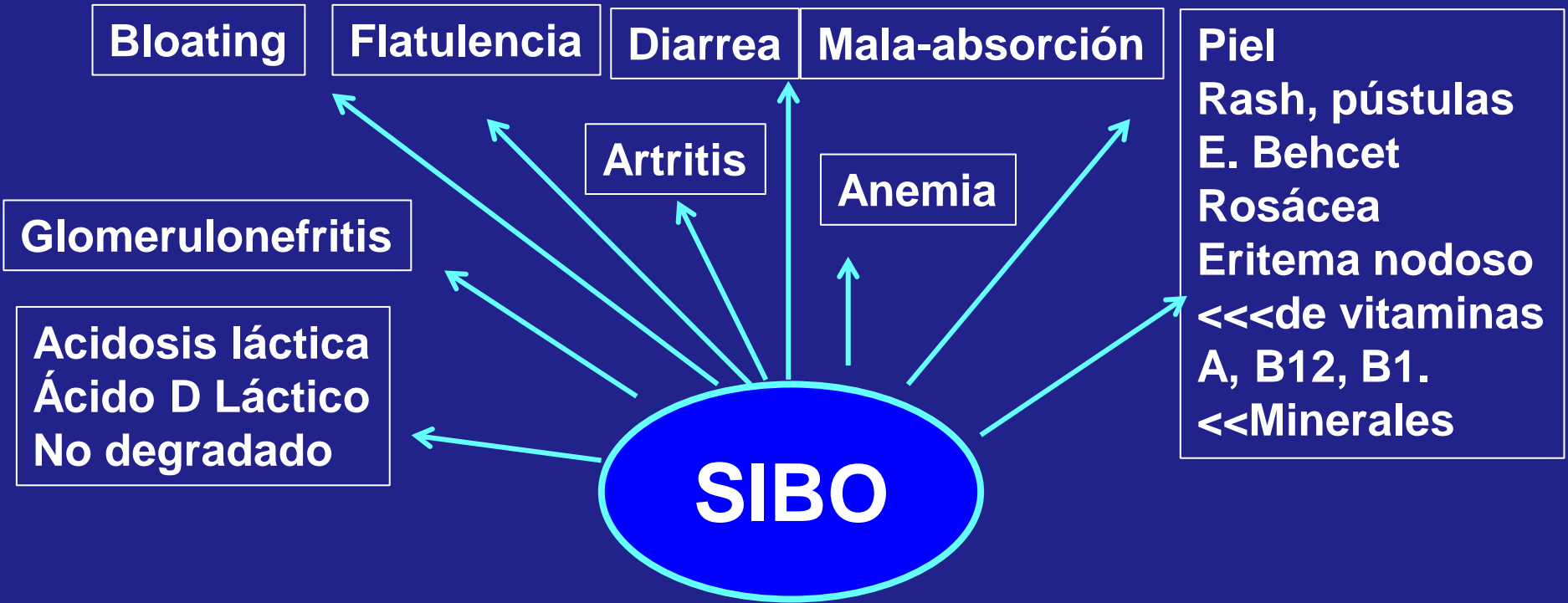
Fístulas

Gastro-cólica
Yeyuno-cólica
Resección válvula ileocecal

Roland BC, Dig Dis Sci 2014;59:1269-75
Bures J, World J Gastroenterol 2010;16:2978-86
Miazga A, Adv Med sci 2015;60:118-24

SIBO: Afecta la salud pública!

Entidades	%
Síndrome de Intestino irritable	30-85%
Enfermedad celíaca	9-55%
E. De Crohn	25%
NAFLD/NASH	>50%
Esclerodermia	90%
Diabetes mellitus	60%
Cirrosis	60%
Fibromialgia	100%
Obesidad Pancreatitis crónica Deficit de IgA, VIH	



Empeoramiento de patologías crónicas



SIBO: diagnóstico (3)

*Diarrea, bloating, dolor abdominal,
perdida de peso +*

Condiciones predisponentes +

Tratamiento

Yamini D, J Clin Gastroenterol 2010;44:672-5
Baker JC, Am J Gastroenterol 2015;110:S1004
Rezaie A, Curr Gastroenterol Rep 2016;18:8

SIBO: diagnóstico (1)

No hay alteraciones de laboratorio específicas
Existirán anomalías por las consecuencias
Anemia, hipoalbuminemia, pérdida de peso
alteraciones de coagulación, esteatorrea, etc.

Erdogan A, Neurogastroenterol Motil 2015;27:481-9
Quigly EM, Infect Dis Clin North Am 2010;24:943-57

SIBO: diagnóstico (2)

Cultivo de aspirado de yeyuno

>10 (5) bacterias /mL, Cuestionado

Endoscopia alta

Técnicas microbiológicas estrictas, falsos (-)

El sobrecrecimiento es en parches, falsos (-)

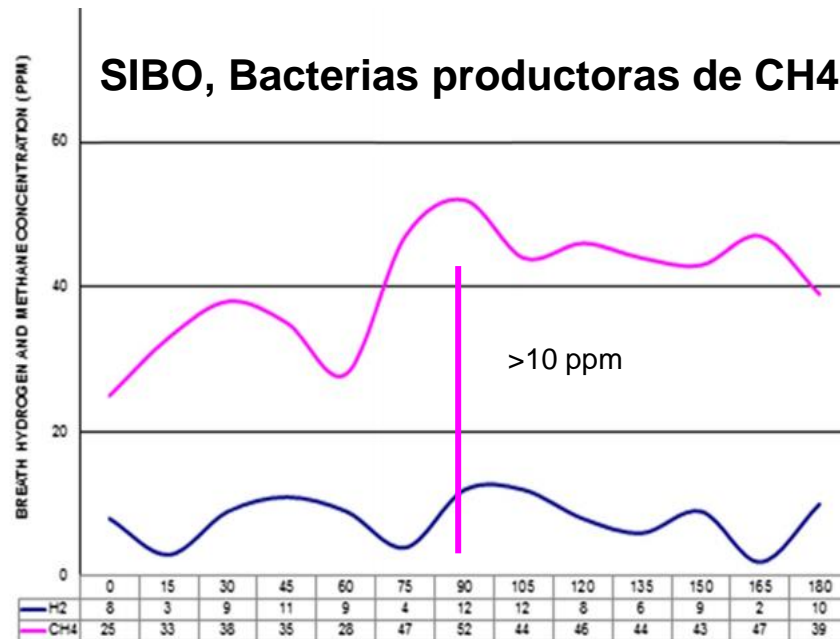
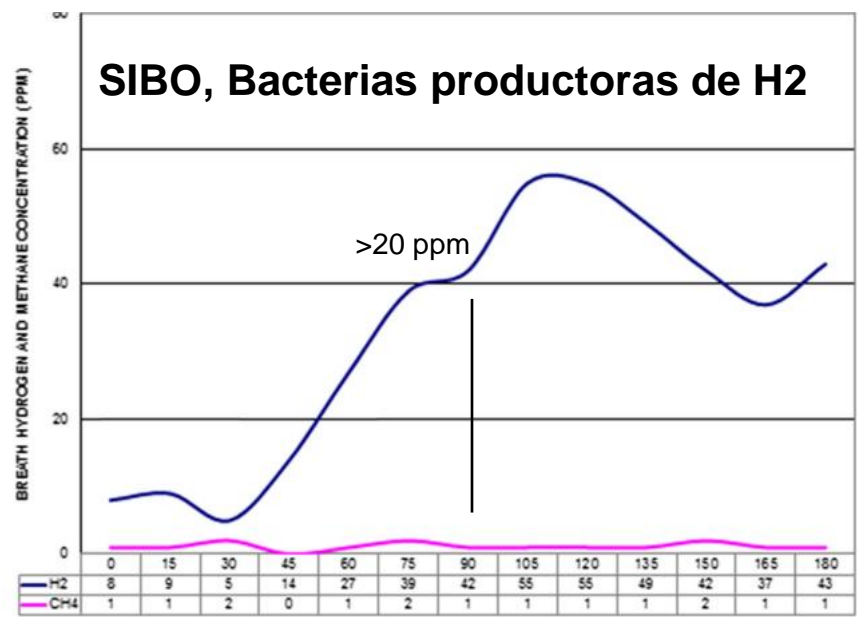
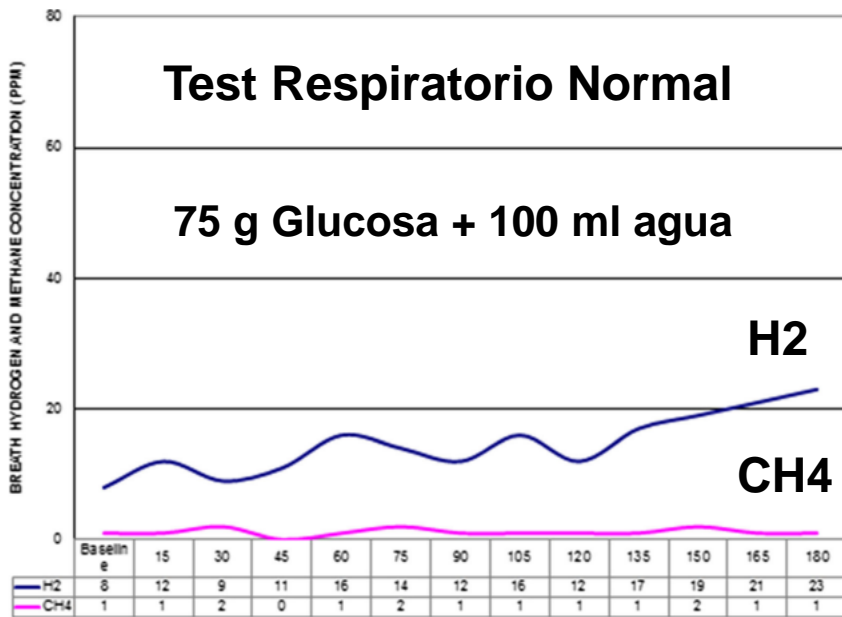
Pobre reproductibilidad

Tests respiratorios de H₂: E 84% S 42%

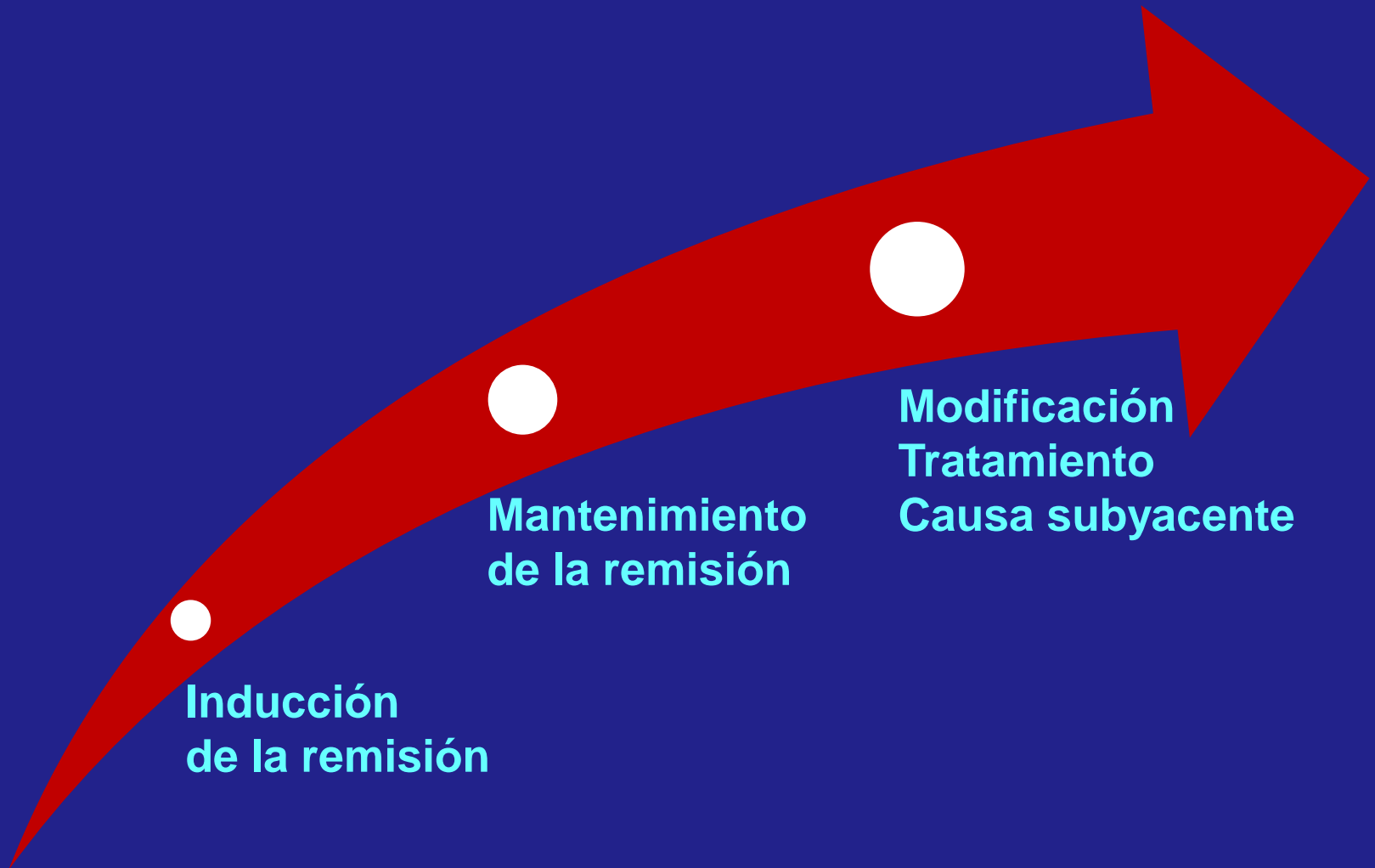
Yamini D, J Clin Gastroenterol 2010;44:672-5

Baker JC, Am J Gastroenterol 2015;110:S1004

Erdogan A, Neurogastroenterol Motil 2015;27:481-9



SIBO, Tratamiento



SIBO

Antibióticos, 7-10 días.

Rifaximina 400-550 mg 3v/día/

Amoxicilina/clavulanato 30 mg/kg/día

Ciprofolxacina

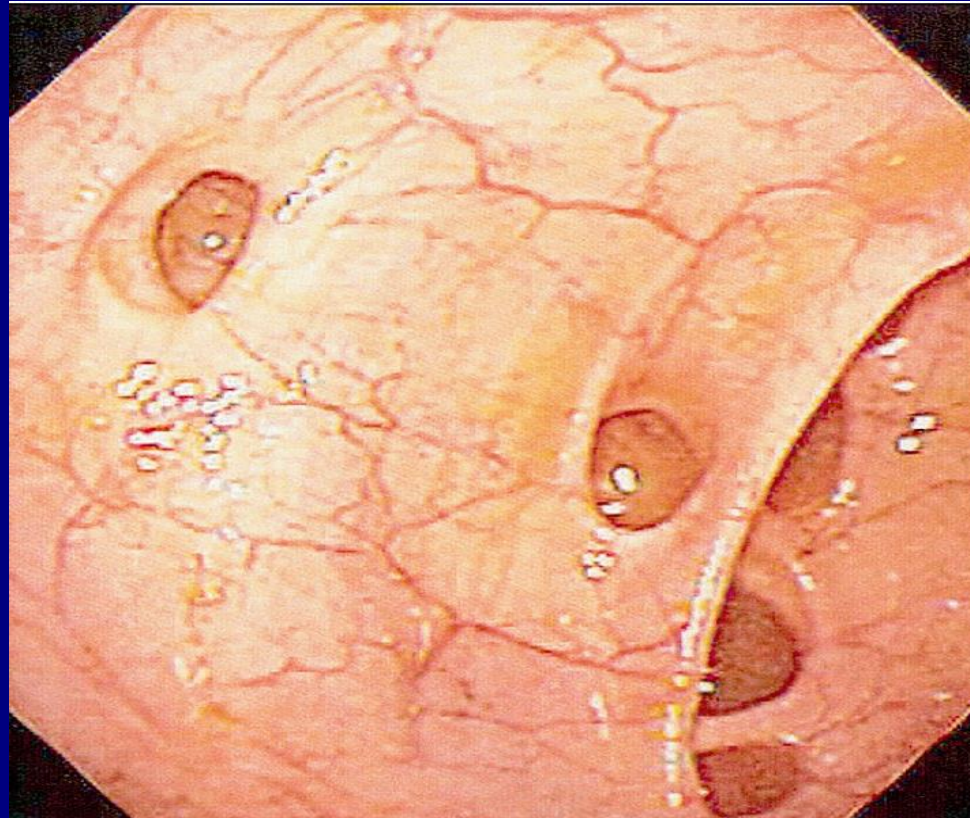Norfloxacina 800 mg/día

Metronidazol 20 mg/kg/día+cefalexina/TMT-S

Probióticos, prebióticos: Faltan evidencias

Pimentel M, Up To date 2019.

Rezaie A, Curr Gastroenterol Rep 2016;18:8



Factores de riesgo

Edad avanzada: menos colágeno > elásticas

Obesidad:

RR: 1.56 (IC95%1.18-2.07): diverticulitis

RR: 1.96 (IC95%1.30-2.97): Sangrado diverticular

Factores genéticos

Monocigotos OR 7.15, dicigotos OR 3.2

Riesgo atribuible 40-53%, ambientales 60%

Tabaquismo: diverticulitis perforada

ASA, AINES: sangrado, diverticulitis

Fibra ?

Grandlund J, Aliment Pharmacol Ther 2012; Early release

Strate LL, Gastroenterology 2013;144:736-42

Crowe FL; BMJ 2011;343:d4131

Peery AF, Gastroenterology 2012;142:266-72

Humes DJ, Gut 2011;60:219-24, Hjern F, Br J Surg 2011;98:997

Jeyarajah J, Aliment Pharmacol Ther 2011; 33: 789–800

A High-Fiber Diet Does Not Protect Against Asymptomatic Diverticulosis

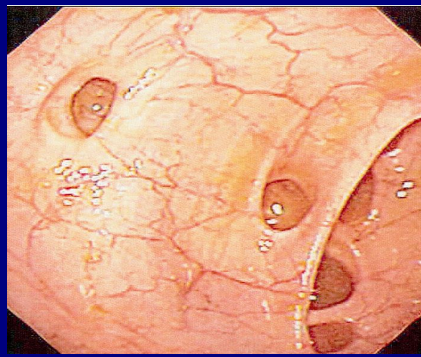
ANNE F. PEERY,* PATRICK R. BARRETT,* DOYUN PARK,*[‡] ALBERT J. ROGERS,* JOSEPH A. GALANKO,*
CHRISTOPHER F. MARTIN,* and ROBERT S. SANDLER*

**Department of Medicine, University of North Carolina School of Medicine, Chapel Hill, North Carolina; [‡]Department of Medicine, Albert Einstein College of Medicine, Bronx, New York*

Gastroenterology 2012;142:266-72

dated instruments. **RESULTS:** The prevalence of diverticulosis increased with age, as expected. High intake of fiber did not reduce the prevalence of diverticulosis. Instead, the quartile with the highest fiber intake had a greater prevalence of diverticulosis than the lowest (prevalence ratio = 1.30; 95% confidence interval, 1.13–1.50). Risk increased when calculated based on intake of total fiber, fiber from grains, soluble fiber, and insoluble fiber. Constipation was not a risk factor. Compared to individuals with <7 bowel movements per week, individuals with >15 bowel movements per week had a 70% greater risk for diverticulosis (prevalence ratio = 1.70; 95% confidence interval, 1.24–2.34). Neither physical inactivity nor intake of fat or red meat was associated with diverticulosis. **CONCLUSIONS:** A high-fiber diet and increased frequency of bowel movements are associated with greater, rather than lower, prevalence of diverticulosis. Hypotheses regarding risk factors for asymptomatic diverticulosis should be reconsidered.

Todos al revés



60-70%: de adultos mayores
Diverticulitis 5%: 20% recurren
Sangrado: 1-1.5%
20%: Síntomas GI crónicos
Dolor abdominal, “bloating”
Alteración hábito intestinal

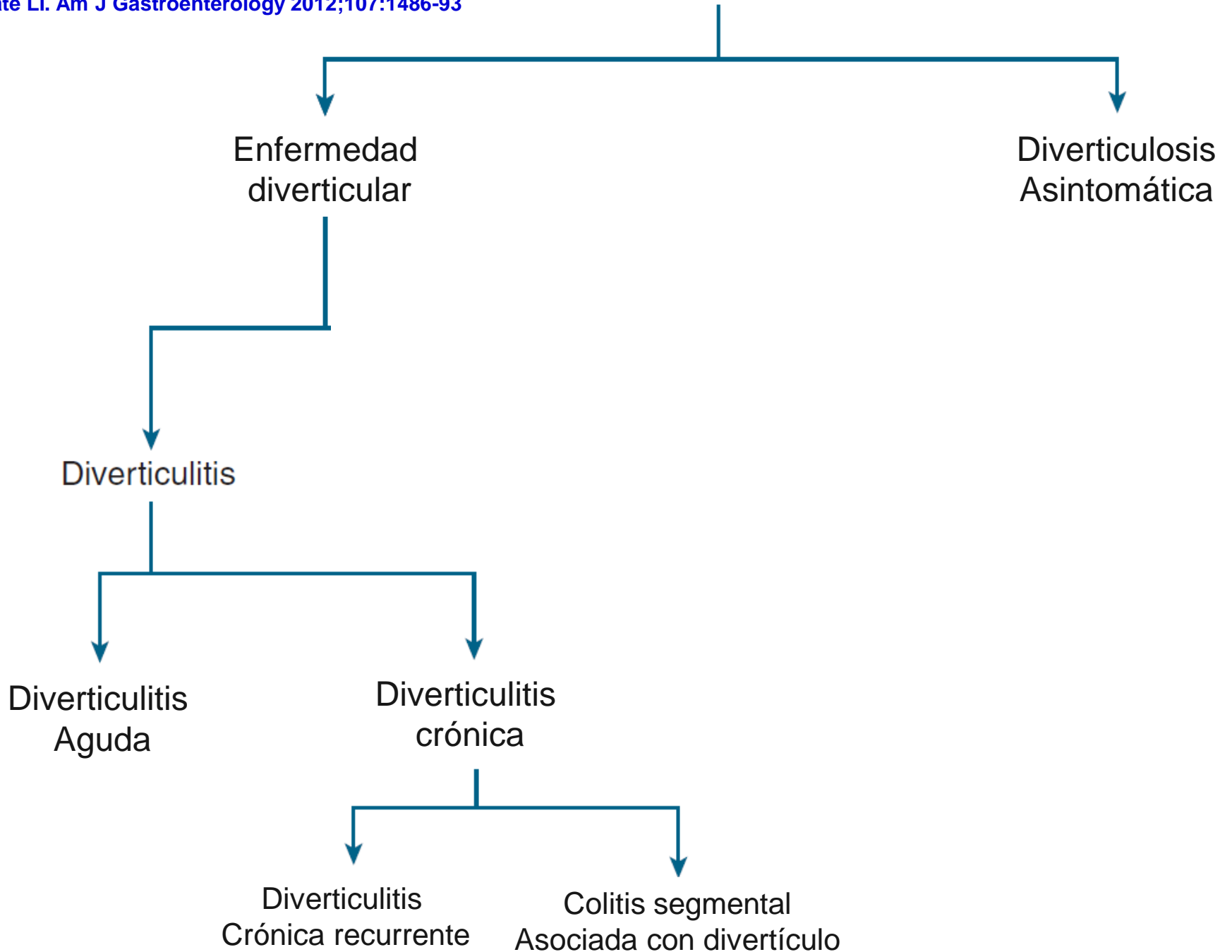


Enfermedad diverticular
Sintomática No complicada

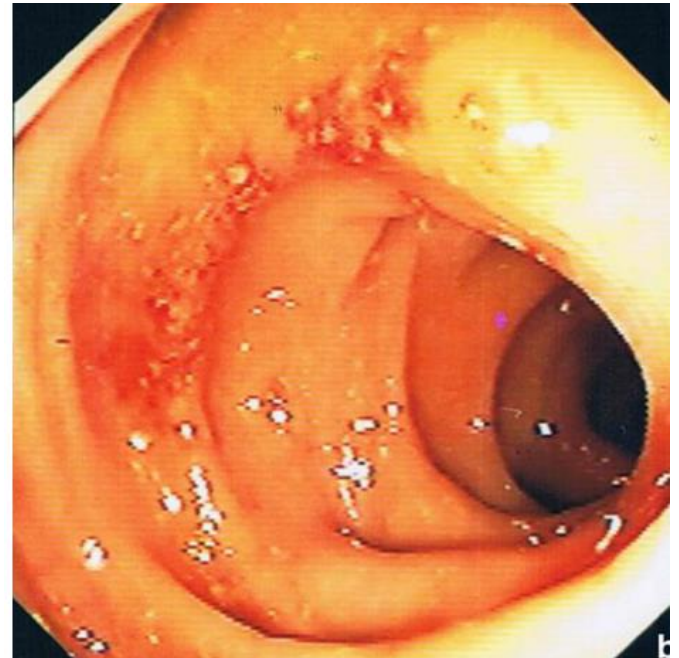
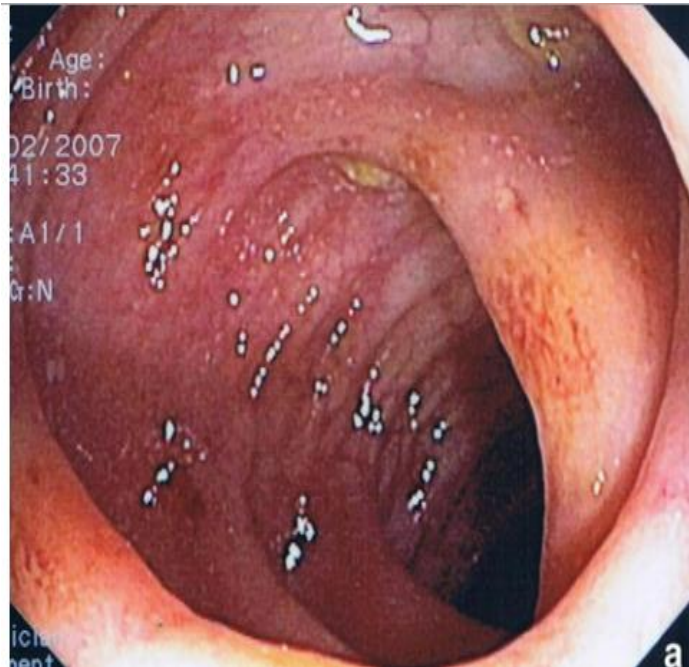
Shahedi K, Clin Gastroenterol Hepatol 2013;11:1609-13
Scarpignato C, Ther Adv Gastroenterol 2018;11:1-21

“Nomenclatura de los divertículos”

Diverticulosis



Colitis asociada a divertículos

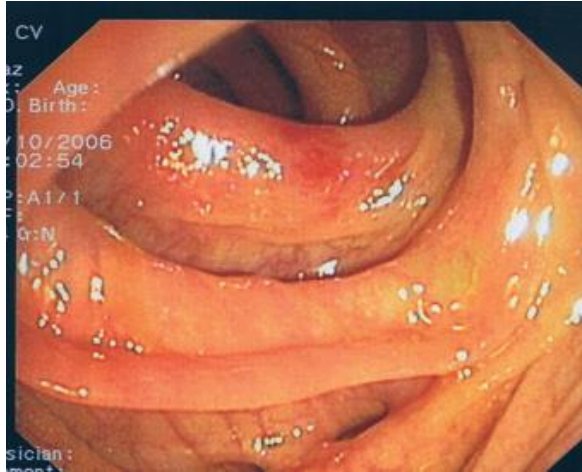

The endoscopic spectrum of segmental colitis associated with diverticulosis

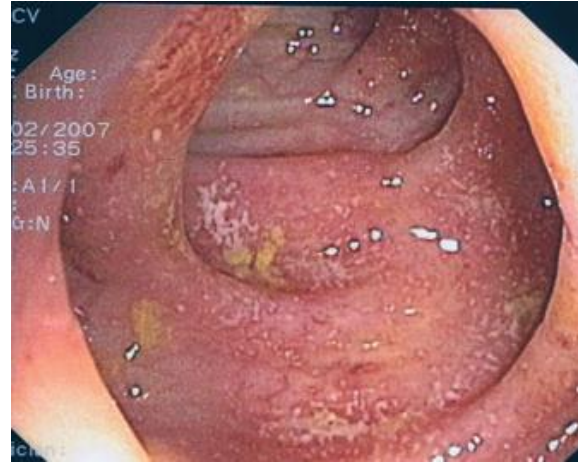Colorectal Dis 2010;12:464-70

A. Tursi*, **W. Elisei†**, **G. Brandimarte†**, **G. M. Giorgetti‡**, **P. G. Lecca†**, **L. Di Cesare†**,
C. D. Inchigolo§ and **F. Aiello¶**

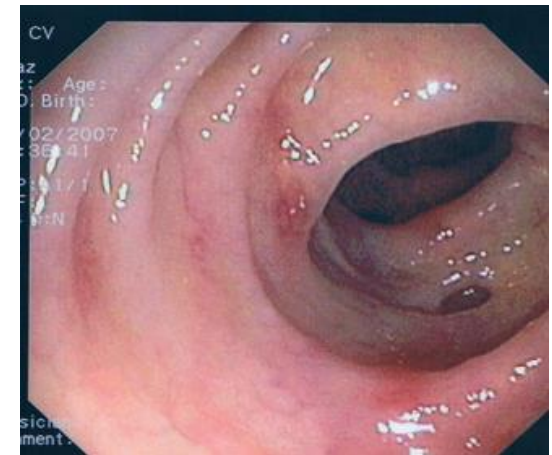*Digestive Endoscopy Unit, 'Lorenzo Bonomo' Hospital, Andria (BA), Italy, †Department in Internal Medicine, Division of Gastroenterology, 'Cristo Re' Hospital, Rome, Italy, ‡Department of Internal Medicine, Clinical Nutrition Unit, 'S. Eugenio' Hospital, Rome, Italy, §Department of Pathology, 'Lorenzo Bonomo' Hospital, Andria (BA), Italy and ¶Department of Statistics and Mathematic Sciences, University of Palermo, Palermo, Italy



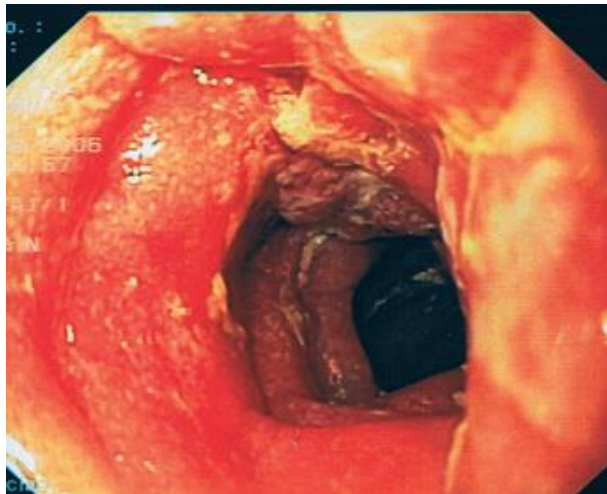
A. pliegues



B. Colitis like



C. Crohn like



D. Ulcerativa severa "like"

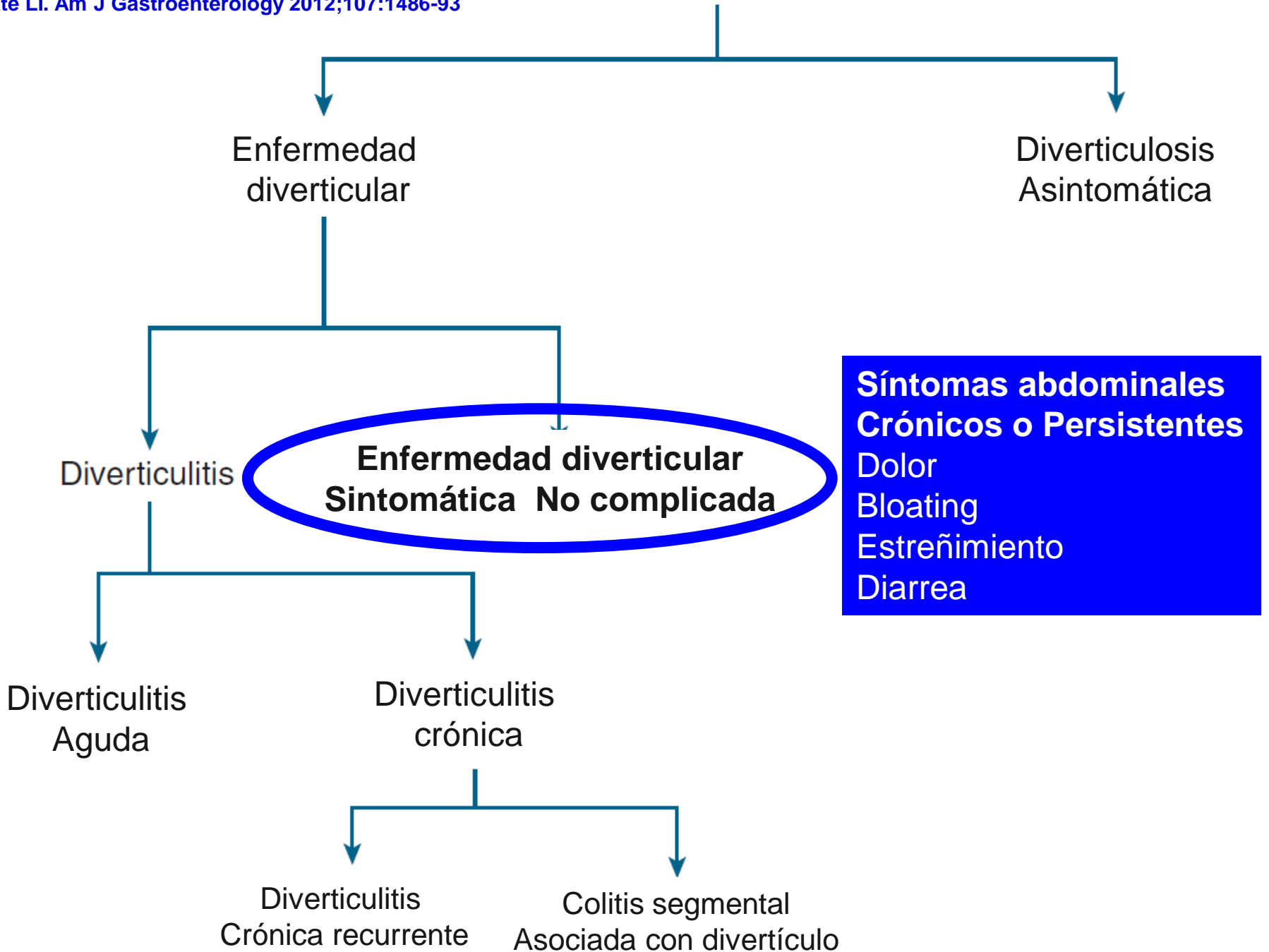
Tratamiento

A y C: Mesalazina 2.4 gr/4 semanas—1.6 gr: 50-80%

B y D: Beclometasona 10 mg/4 semanas + VSL #3

Tursi A, Int J Colorectal Dis 2012;27:179-85

Diverticulosis



**Síntomas abdominales
Crónicos o Persistentes**
Dolor
Bloating
Estreñimiento
Diarrea

Enfermedad diverticular sintomática no Complicada Vs SII

<i>Características clínicas y bioquímicas</i>	<i>Enfermedad diverticular crónica sintomática no complicada</i>	<i>SII</i>
Dolor abdominal	Si	Si
Difuso	No	SI
Cuadrante Inferior Izq	Si	No
Últimas 24 horas	Si	No
Alivio después de deposiciones	No	Si
Calprotectina fecal elevada	Si	No

Lanas A, et al Ther Adv Gastroenterol 2018;11: 1–21

Enfermedad diverticular

Síntomas abdominales crónicos

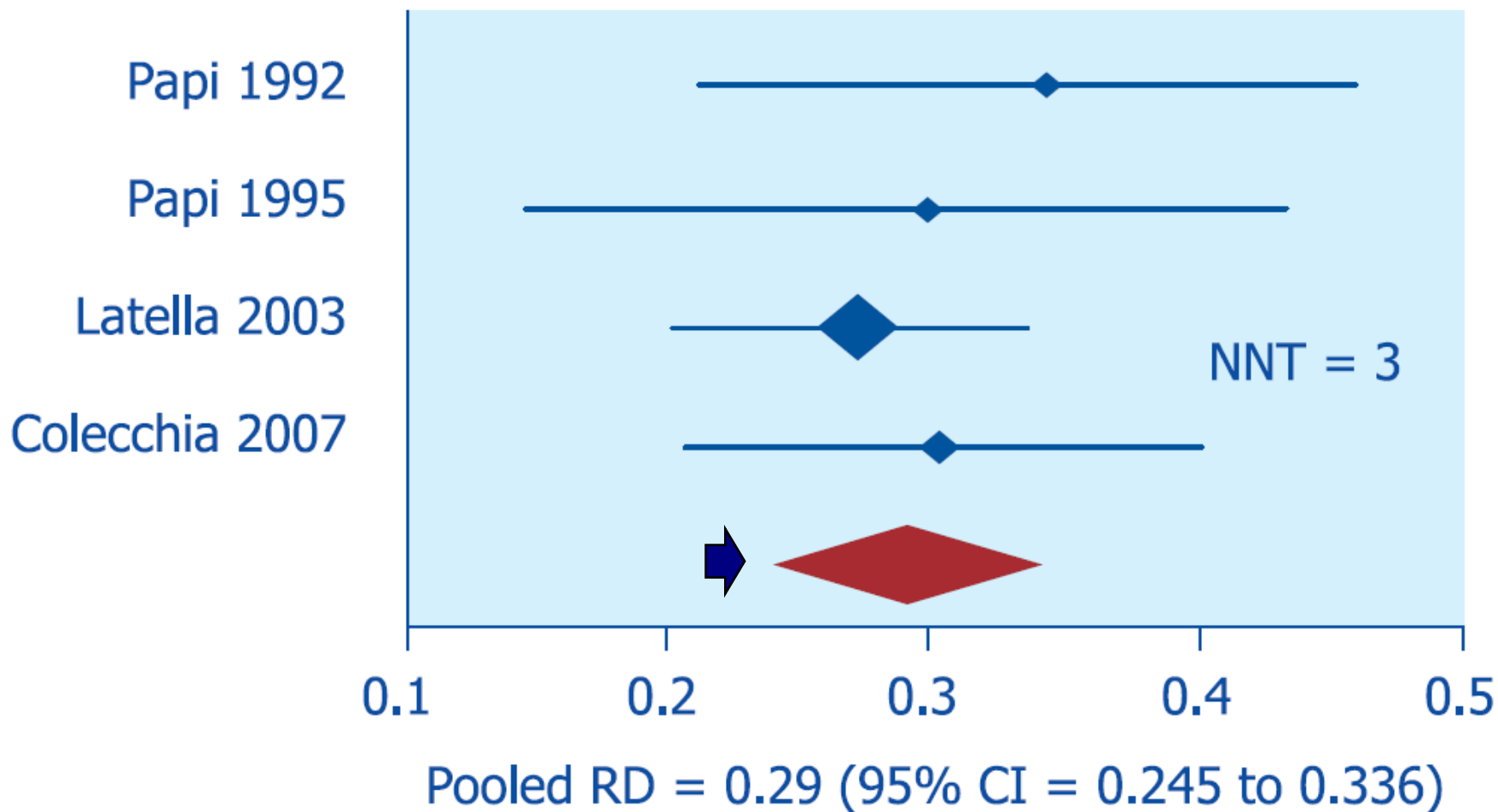
Rifaximina ciclica
400 mg 2v/día-7 días cada Mes

```
graph TD; A[Rifaximina ciclica  
400 mg 2v/día-7 días cada Mes] --> B[Alivio de síntomas  
64 vs 39%  
NNT3]; A --> C[Prevenir  
Diverticulitis aguda  
NNT 59];
```

Alivio de síntomas
64 vs 39%
NNT3

Prevenir
Diverticulitis aguda
NNT 59


Rifaximina- Enfermedad diverticular no Complicada: Metaanálisis



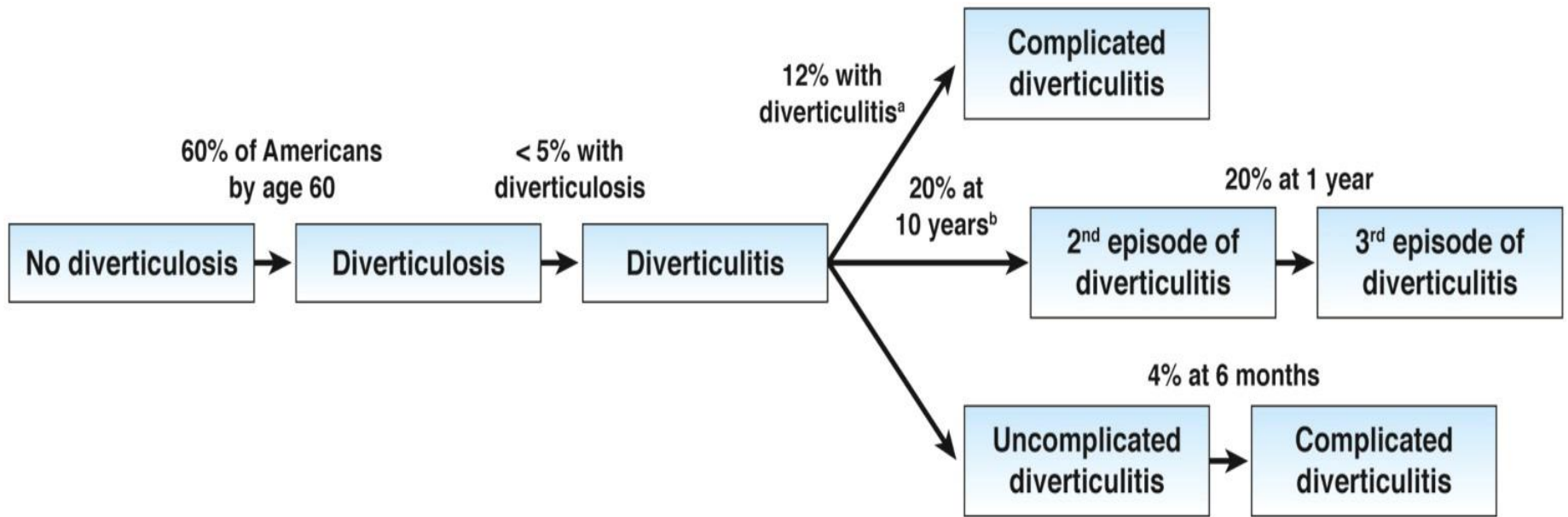
Bianchi M, *Aliment Pharmacol Ther* 2011; 33: 902–910.

Rifaximina

**Enfermedad diverticular
Sintomática no complicada**



**Su eficacia se debe a efectos
Más allá de ser un antibiótico**



***Gastroenterology* 2019;156:1282-98.**

Figure 2

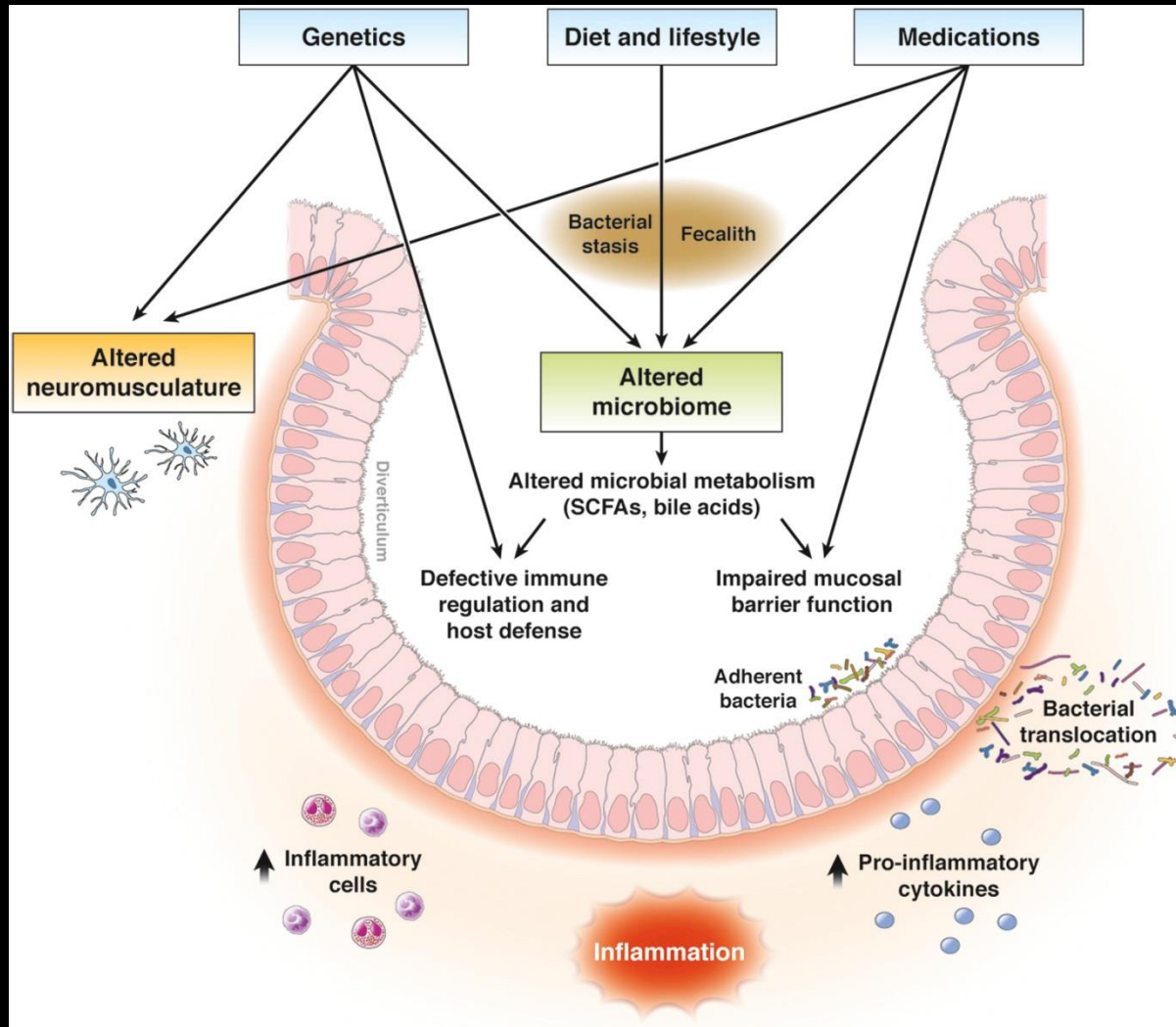
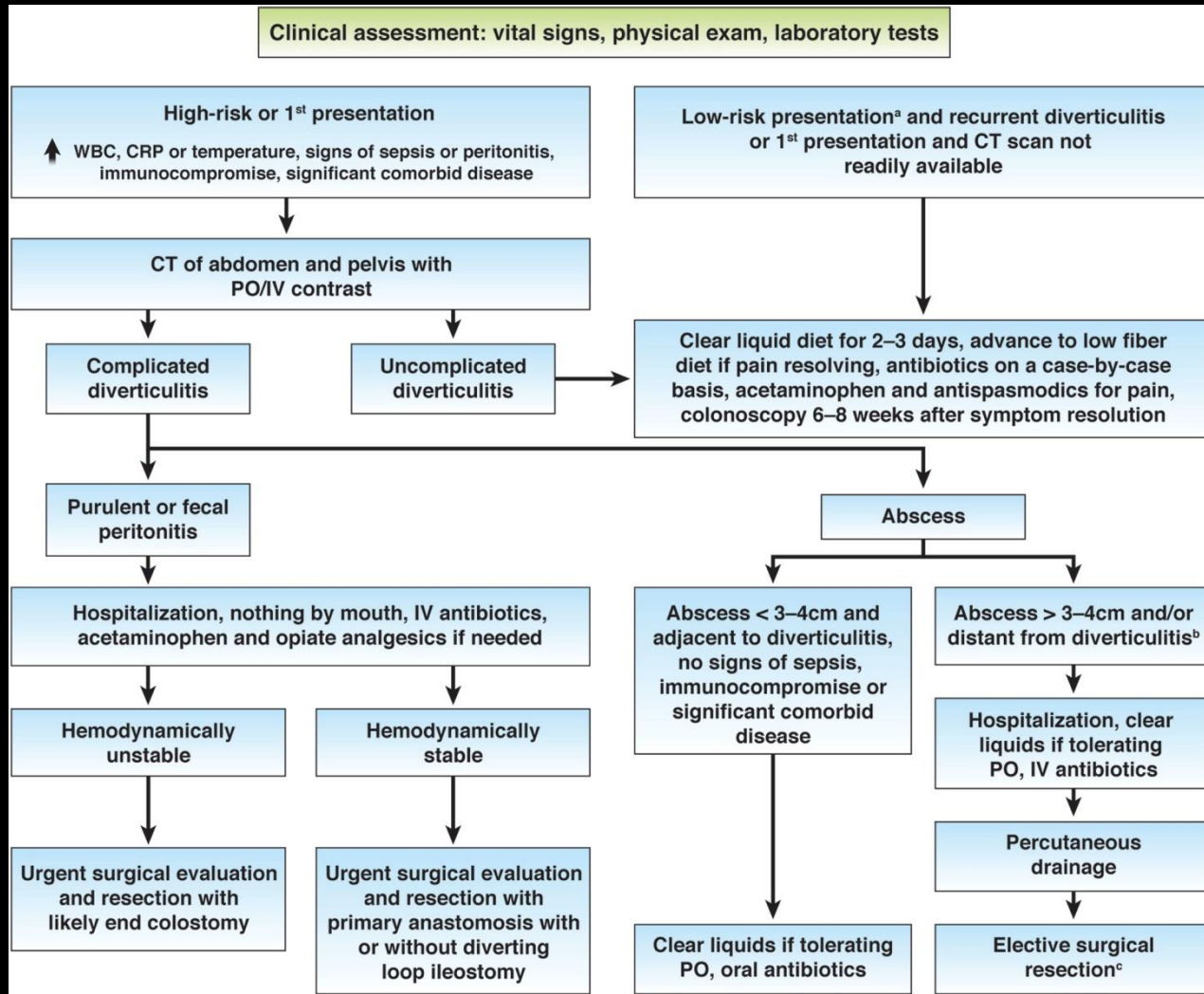


Figure 3



AINES y patología GI Superior
Necesidad de IBP profilactico

Profilaxis con IBP

*Edad > 60 años, / 45 o más**

Altas dosis de AINES

Úlcera péptica previa

Efectos adversos previos

Uso concomitante

Esteroides, Anticoagulantes

Bifosfonatos, varios AINES


***NICE 2015**

Causas del aumento

IBP +AINES



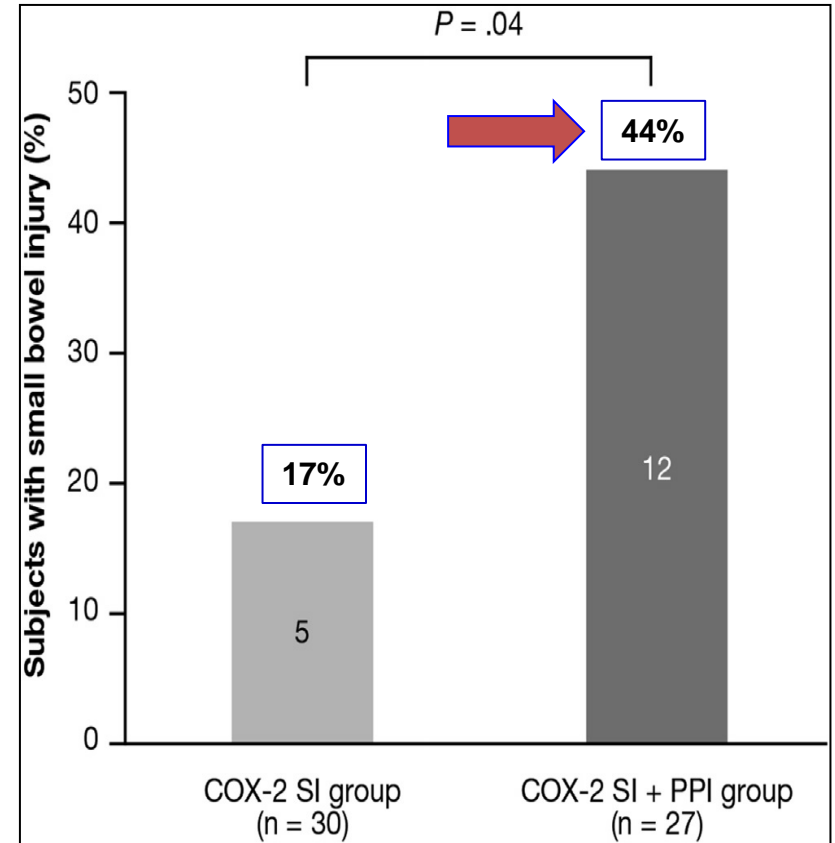
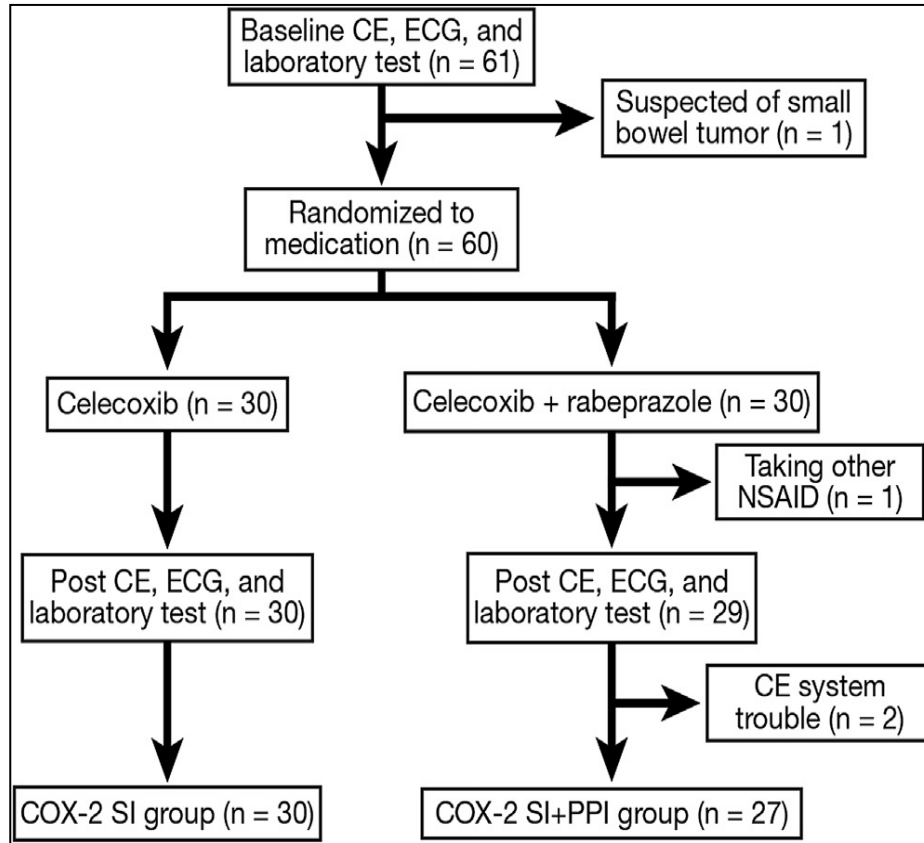
**Protección
hasta
el duodeno**



**Incrementa
Lesiones
inferiores**

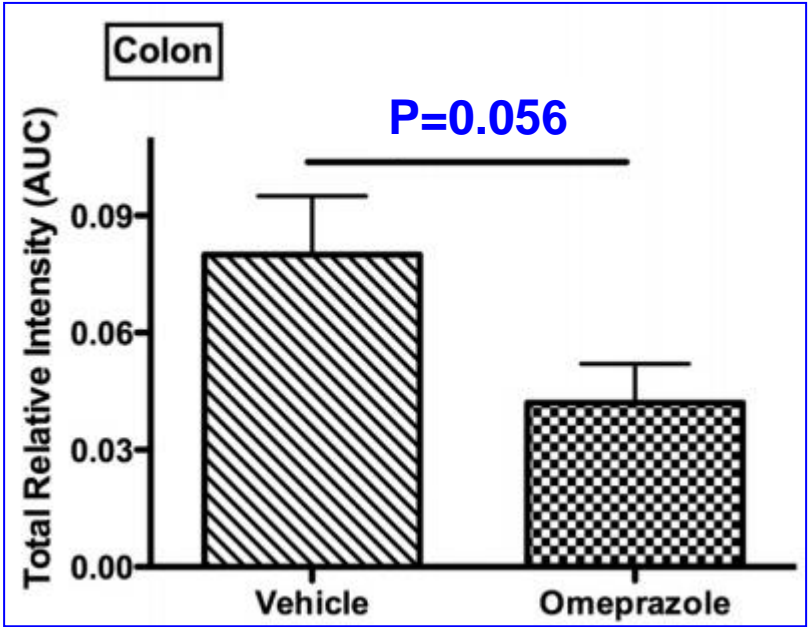
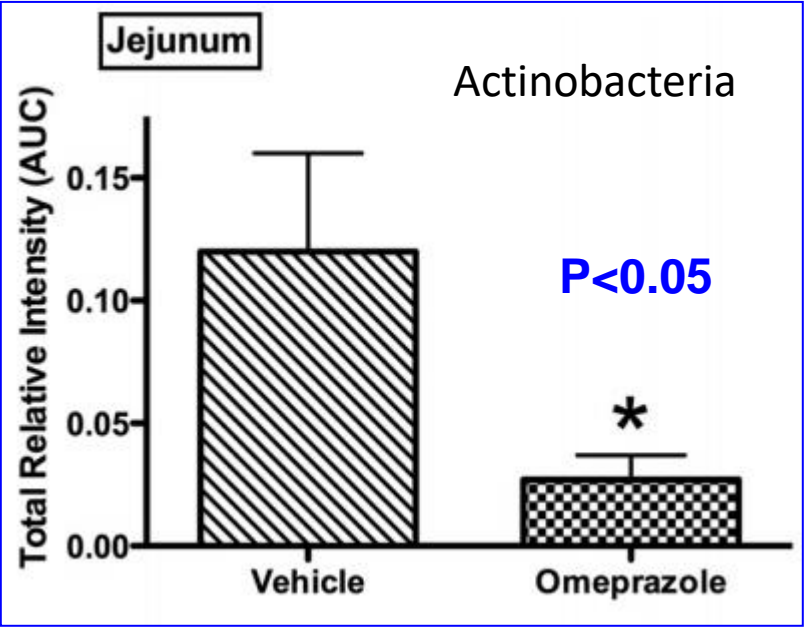
Proton Pump Inhibitors Increase Incidence of Nonsteroidal Anti-Inflammatory Drug–Induced Small Bowel Injury: A Randomized, Placebo-Controlled Trial

Emi Washio,* Motohiro Esaki,* Yuji Maehata,* Masashi Miyazaki,† Hiroyuki Kobayashi, Hideki Ishikawa,§ Takanari Kitazono,* and Takayuki Matsumoto||



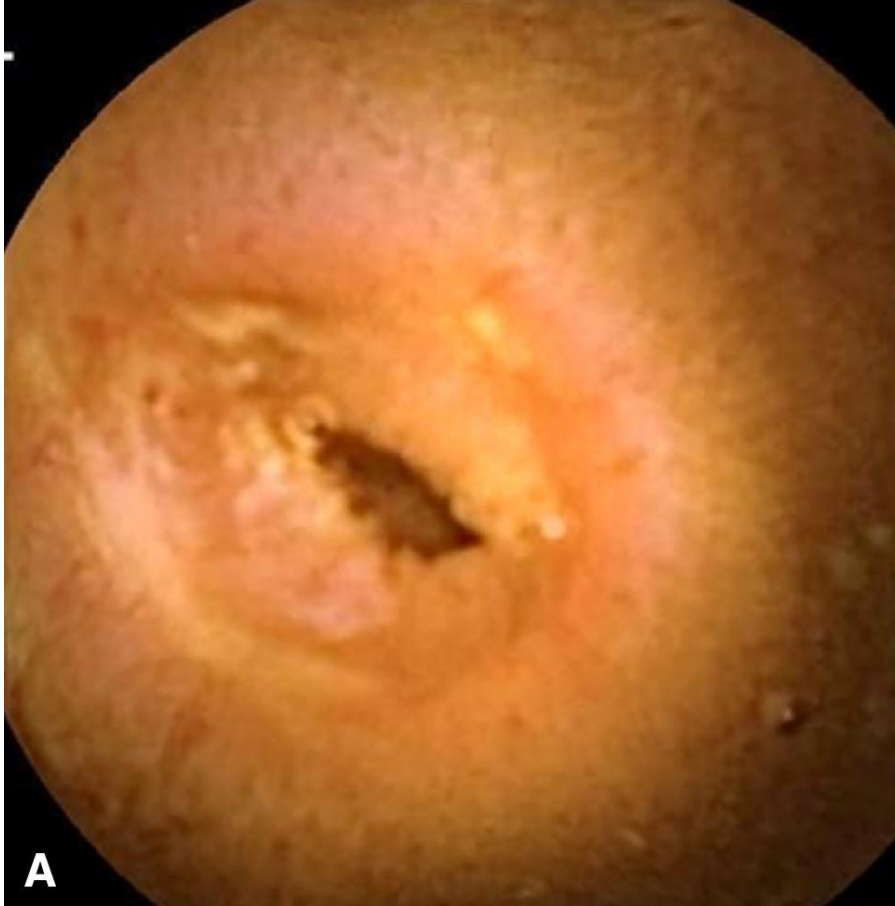
Proton Pump Inhibitors Exacerbate NSAID-Induced Small Intestinal Injury by Inducing Dysbiosis

JOHN L. WALLACE,* STEPHANIE SYER,* EMMANUEL DENOUE,* GIADA DE PALMA,* LINDA VONG,* WEBB McKNIGHT,* JENNIFER JURY,* MANLIO BOLLA,† PREMYSL BERCIK,* STEPHEN M. COLLINS,* ELENA VERDU,* and ENNIO ONGINI†

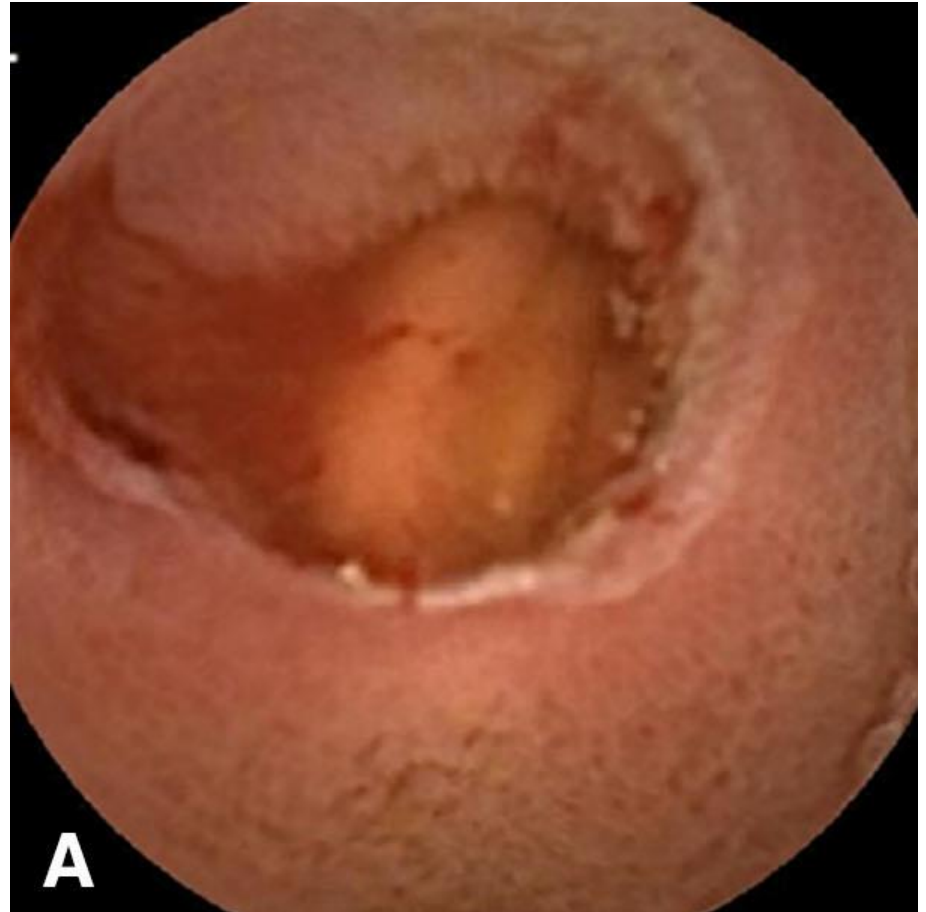


Tratamiento	IL-2	IL-17	INF gama	Granulocito/macófago	Activación Células T
Vehículo	321+/-38	693 +/-84	14+/-6	254+/-26	4476+/-326
Omeprazol	351+/-47	770+/-103	26+/-7	280+/-27	6791+/-2421

Video-cápsula

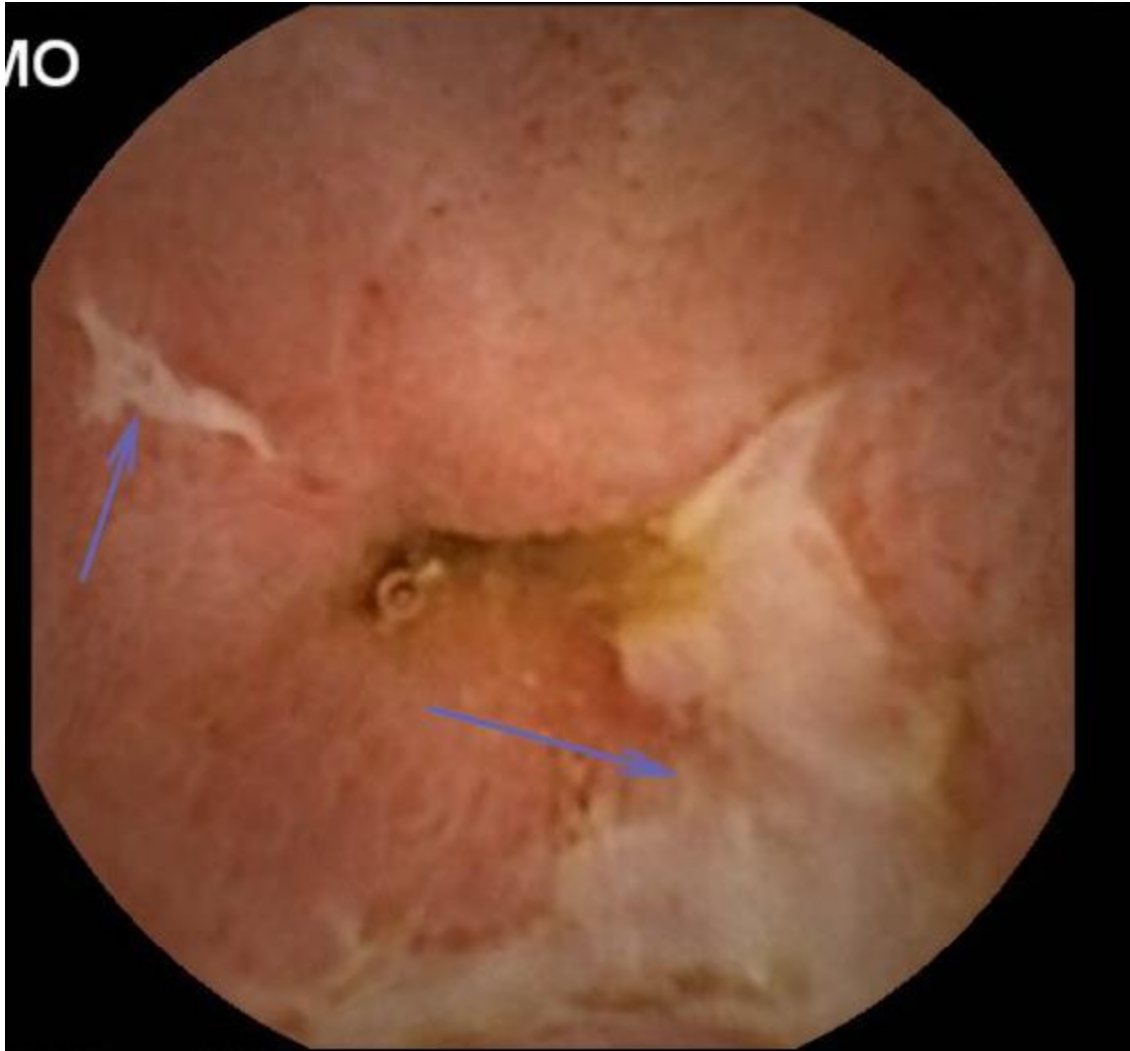


Úlcera circunferencial

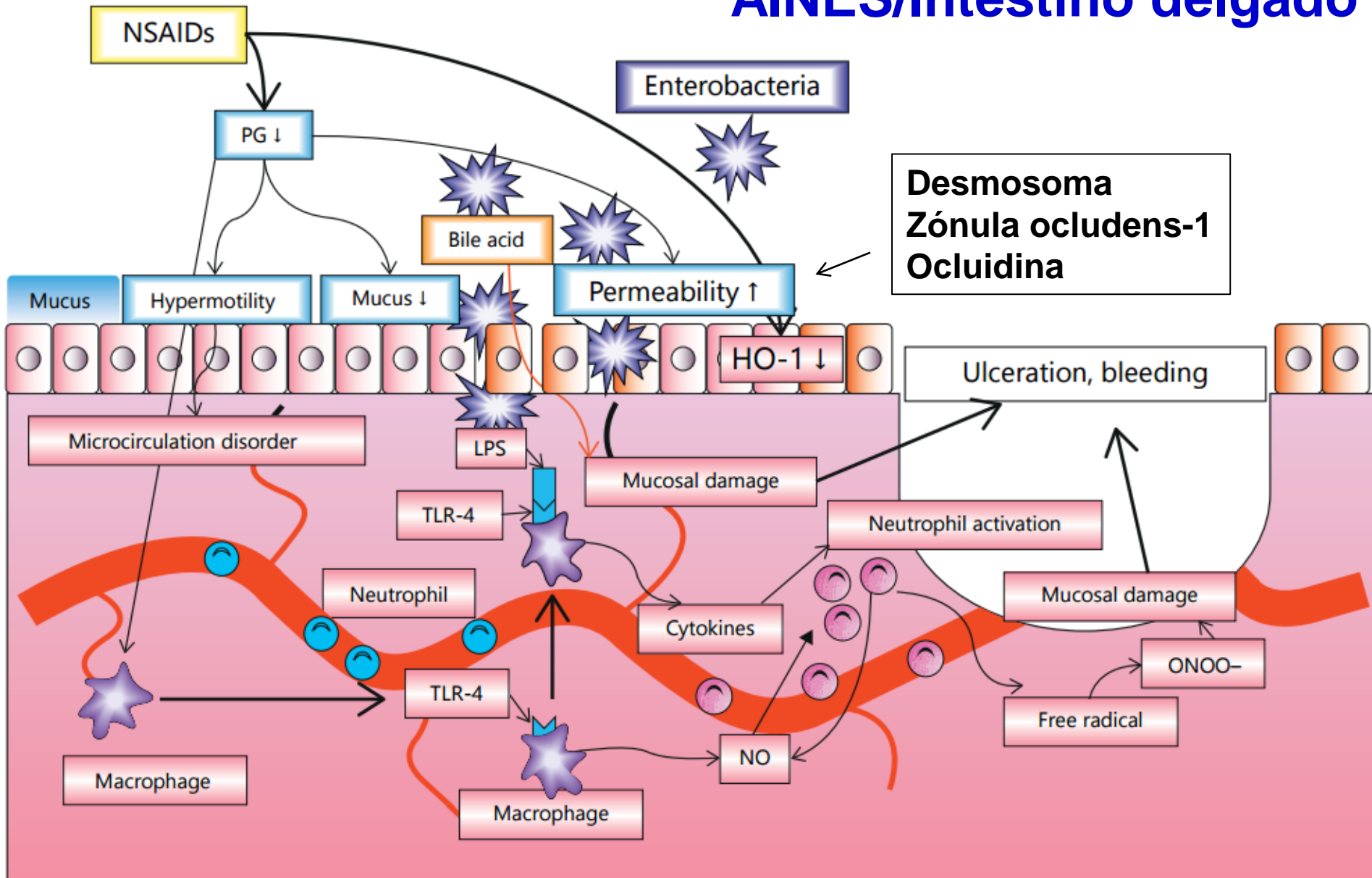


**Úlcera con sangrado activo
estenosis**

Úlceras por AINES en ID



AINES/Intestino delgado



Alteración de la microbiota

ORIGINAL ARTICLE

[Imhann F, et al. Gut 2016;65:740–748](#)

Proton pump inhibitors affect the gut microbiome

Floris Imhann,¹ Marc Jan Bonder,² Arnau Vich Vila,¹ Jingyuan Fu,² Zlatan Mujagic,³ Lisa Vork,³ Etti F Tigchelaar,² Soesma A Jankipersadsing,² Maria Carmen Cenit,² Hermie J M Harmsen,⁴ Gerard Dijkstra,¹ Lude Franke,² Ramnik J Xavier,⁵ Daisy Jonkers,³ Cisca Wijmenga,² Rinse K Weersma,¹ Alexandra Zhernakova²

ORIGINAL ARTICLE

[Jackson MA, et al. Gut 2016;65:749–75](#)

Proton pump inhibitors alter the composition of the gut microbiota

Matthew A Jackson,¹ Julia K Goodrich,^{2,3} Maria-Emanuela Maxan,⁴ Daniel E Freedberg,⁵ Julian A Abrams,⁵ Angela C Poole,^{2,3} Jessica L Sutter,^{2,3} Daphne Welter,^{2,3} Ruth E Ley,^{2,3} Jordana T Bell,¹ Tim D Spector,¹ Claire J Steves¹

Proton Pump Inhibitors Alter Specific Taxa in the Human Gastrointestinal Microbiome: A Crossover Trial



Daniel E. Freedberg,¹ Nora C. Toussaint,² Sway P. Chen,³ Adam J. Ratner,⁴ Susan Whittier,⁵ Timothy C. Wang,¹ Harris H. Wang,^{5,6,§} and Julian A. Abrams^{1,§}

[Gastroenterology 2015;149:883–885](#)

Rifaximin Reduces the Number and Severity of Intestinal Lesions Associated With Use of Nonsteroidal Anti-Inflammatory Drugs in Humans

Carmelo Scarpignato,^{1,*} Werner Dolak,^{2,*} Angel Lanas,³ Peter Matzneller,⁴ Cecilia Re


Gastroenterology 2017;152:980–982

64 voluntarios sanos
Dclofenac 75 mg 2v/dia +
Omeprazol 20 mg/d 14 días

VDC antes y
después

Rifaximina
400 2v/d

Placebo
2v/d



Erosiones

20%

43%

p=0.05

Lsiones
Grandes

0

9

p<0.001

Conclusión

**Rifaximina es el antibiótico
desde cuidado primario**

A las supraespecialidades

Rifaximina: Usos en 2019

Diarrea del viajero

Síndrome Intestino irritable

Bloating

Encefalopatía hepática

Flatulencia

Sobrecrecimiento bacteriano

E. Diverticular Sintomática no complicada

Prevención de lesiones por AINEs-IBP en ID

***“A veces el hombre se encuentra
Muchas veces con la verdad y es
tan tonto que le saca el cuerpo”***

Winston Churchill

Mensajes para la casa

**Rifaximina es el antibiótico del ID
Citoprotector, anti-inflamatorio en colon
Eubiótico**

No quinolonas en diarrea aguda

Hace parte de tratamientos de la microbiota

Efectos adversos similares a un Placebo

NNH 9871

Formulación 550 mg facilita prescripción

Múltiples usos en el 2019

Muchas gracias

Muy amables!!

Bolivia es encantador