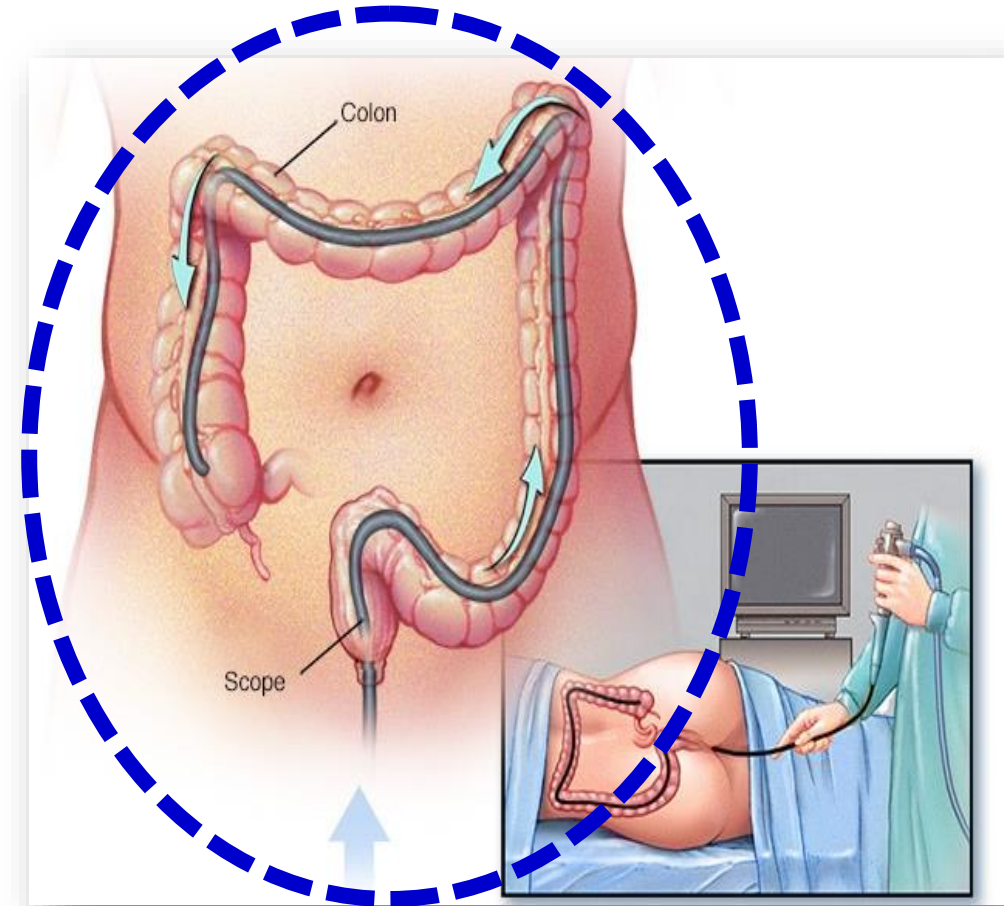




Indicadores de calidad en la colonoscopia 2023

William Otero R MD, FAGA, FACP, FASGE
Profesor Titular de Medicina
Universidad Nacional de Colombia
Hospital Universitario Nacional de Colombia



**El colonoscopio estándar de oro
para tamización diagnóstico y
Vigilancia patologías del colon**





Càncer colorrectal

USA 2do càncer màs frecuente

3^a causa dse muerte por càncer

45 años tamizaciòn

Colonoscopia **estàndar se oro**

Detecta y previene CCR polipectomia

Siegel RL, CA Cancer J Clin 2022;72:7-33

Almario CV, Teccn Innov Gastrointest Endosc 2022;269-83

Càncer colorrectal

Beneficios de la colonoscopia

Incidencia 31-91%

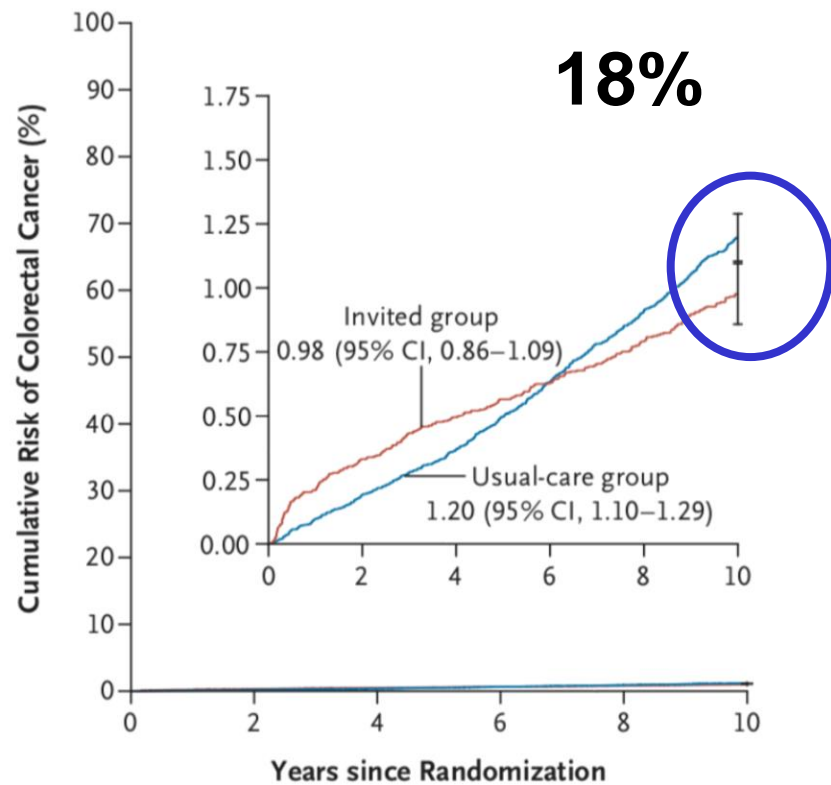
Mortalidad 65-88%

Estudios observacionales analíticos

Shaukat A, Am J Gastroenterol 2021;116:458-79

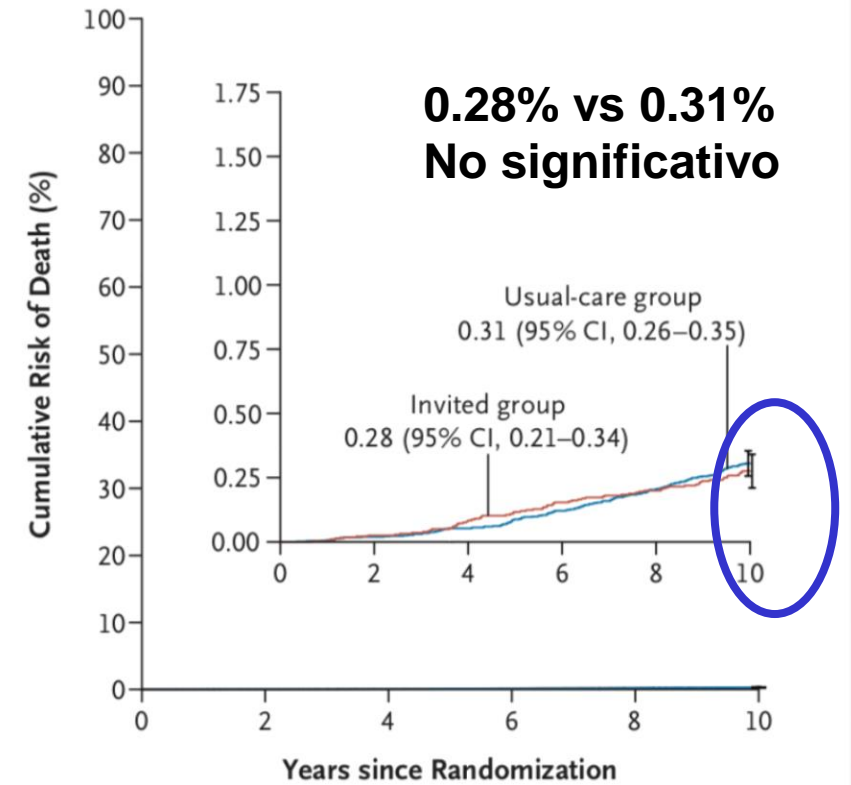
Effect of Colonoscopy Screening on Risks of Colorectal Cancer and Related Death

M. Bretthauer, M. Løberg, P. Wieszczyni, M. Kalager, L. Emilsson, K. Garborg, M. Rupinski, E. Dekker, M. Spaander, M. Bugajski, Ø. Holme, A.G. Zauber, N.D. Pilonis, A. Mroz, E.J. Kuipers, J. Shi, M.A. Hernán, H.-O. Adami, J. Regula, G. Hoff, and M.F. Kaminski, for the NordICC Study Group*



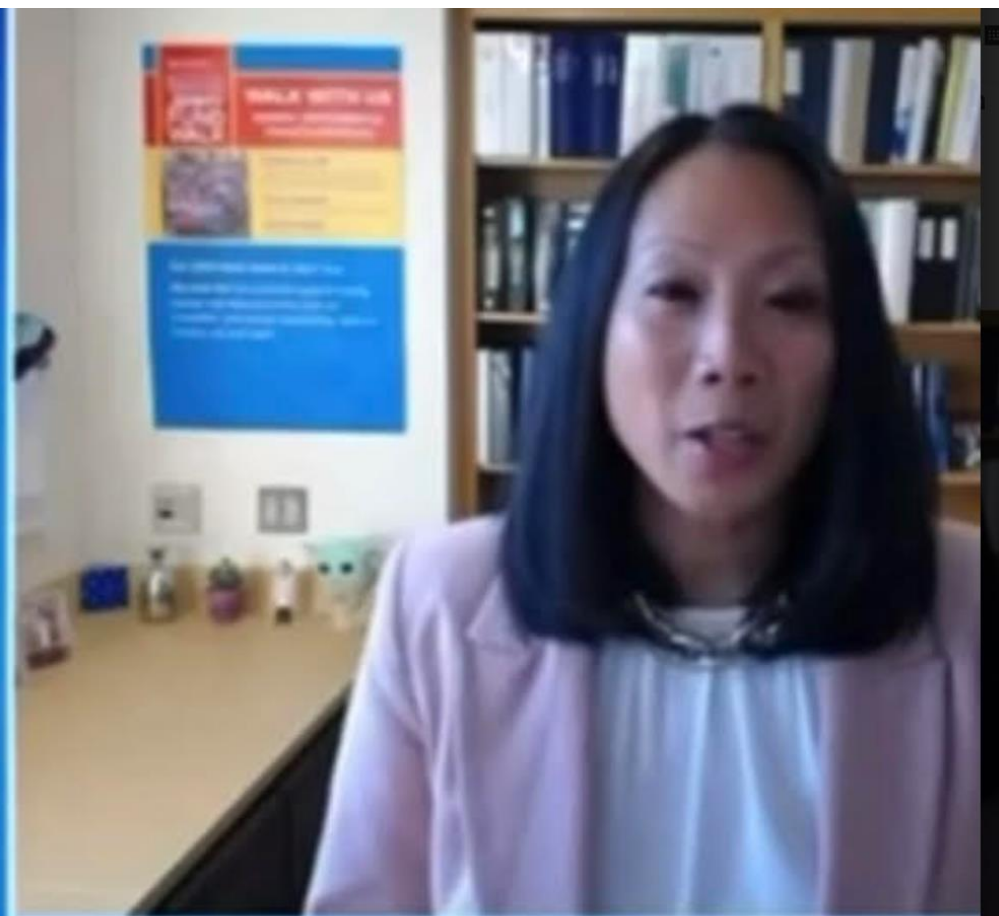No. at Risk

Invited group	28,220	27,684	27,111	26,461	24,000	18,748
Usual-care group	56,365	55,375	54,192	52,819	47,769	37,313



No. at Risk

Invited group	28,220	27,768	27,224	26,591	25,273	18,856
Usual-care group	56,365	55,469	54,362	53,086	50,356	37,604



CANCER SCREENING

NEW STUDY QUESTIONS EFFECTIVENESS OF COLONOSCOPIES IN PREVENTING DEATH

8:14
58°

The NEW ENGLAND JOURNAL of MEDICINE

ESTABLISHED IN 1812

OCTOBER 27, 2022

VOL. 387 NO. 17

Effect of Colonoscopy Screening on Risks of Colorectal Cancer and Related Death

M. Bretthauer, M. Løberg, P. Wieszcy, M. Kalager, L. Emilsson, K. Garborg, M. Rupinski, E. Dekker, M. Spaander, M. Bugajski, Ø. Holme, A.G. Zauber, N.D. Pilonis, A. Mroz, E.J. Kuipers, J. Shi, M.A. Hernán, H.-O. Adami, J. Regula, G. Hoff, and M.F. Kaminski, for the NordICC Study Group*



Tamización 42% invitados

**29% Endoscopistas
ADR <25%**

**Tasa Intubación del ciego
< Exigido**



State of the Science on Quality Indicators for Colonoscopy and How to Achieve Them

Folasade P. May, MD, PhD^{1,2} and Aasma Shaukat, MD, MPH^{3,4}

Am J Gastroenterol 2020;115:1183–1190



UNITED EUROPEAN
GASTROENTEROLOGY
ueg journal

Review Article

Performance measures for lower gastrointestinal endoscopy: a European Society of Gastrointestinal Endoscopy (ESGE) quality improvement initiative

Michal F Kaminski^{1,2,3,4}, Siwan Thomas-Gibson⁵, Marek Bugajski^{1,2}, Michael Bretthauer^{3,4}, Colin J Rees⁶, Evelien Dekker⁷, Geir Hoff^{3,8,9}, Rodrigo Jover¹⁰, Stepan Suchanek¹¹, Monika Ferlitsch¹², John Anderson¹³, Thomas Roesch¹⁴, Rolf Hultcranz¹⁵, Istvan Racz¹⁶, Ernst J Kuipers¹⁷, Kjetil Garborg³, James E East¹⁸, Maciej Rupinski^{1,2}, Birgitte Seip¹⁹, Cathy Bennett²⁰, Carlo Senore²¹, Silvia Minozzi²¹, Raf Bisschops²², Dirk Domagk²³, Roland Valori²⁴, Cristiano Spada²⁵, Cesare Hassan²⁶, Mario Dinis-Ribeiro^{27,28} and Matthew D Rutter^{29,30}

United European Gastroenterology Journal 2017, Vol. 5(3) 309–334
This article is published simultaneously in the journals Endoscopy and the United European Gastroenterology Journal.
Copyright 2017© Georg Thieme Verlag KG and © by the United European Gastroenterology
Reprints and permissions:
sagepub.co.uk/journalsPermissions.nav
DOI: 10.1177/2050640617700014
journals.sagepub.com/home/ueg



U Eur Gastroenterol J 2017;5:309-34

Measuring and Improving Quality of Colonoscopy for Colorectal Cancer Screening

Christopher V. Almario,^{1,2,3,4,5,6} Jaspreet Shergill,¹ and Janice Oh¹

Tech Inn Gastrointest Endosc 2022; 269283

REVIEW ARTICLE

Key quality indicators in colonoscopy


Douglas K. Rex* Gastroenterol Rep 2023; 11: goad009

Gastroenterology 2021;161:701–711

CLINICAL PRACTICE UPDATE: EXPERT REVIEW

AGA Clinical Practice Update on Strategies to Improve Quality of Screening and Surveillance Colonoscopy: Expert Review

Rajesh N. Keswani,¹ Seth D. Crockett,² and Audrey H. Calderwood³



Standards of diagnostic colonoscopy for early-stage neoplasia: Recommendations by an Asian private group

Yasushi Sano,¹ Han-Mo Chiu,⁹ Xiao-bo Li,¹⁰ Supakij Khomvilai,¹³ Pises Pisespongsa,¹⁴ Jonard Tan Co,¹⁵ Takuji Kawamura,² Nozomu Kobayashi,⁴ Shinji Tanaka,⁵ David G. Hewett,¹⁶ Yoji Takeuchi,⁶ Kenichiro Imai,⁷ Takahiro Utsumi,³ Akira Teramoto,¹ Daizen Hirata,¹ Mineo Iwatate,¹ Rajvinder Singh,¹⁷ Siew C. Ng,¹¹ Shiaw-Hooi Ho,¹⁸ Philip Chiu¹² and Hisao Tajiri⁸

Digestive Endoscopy 2019; 31: 227-44

CLINICAL PRACTICE UPDATE: EXPERT REVIEW

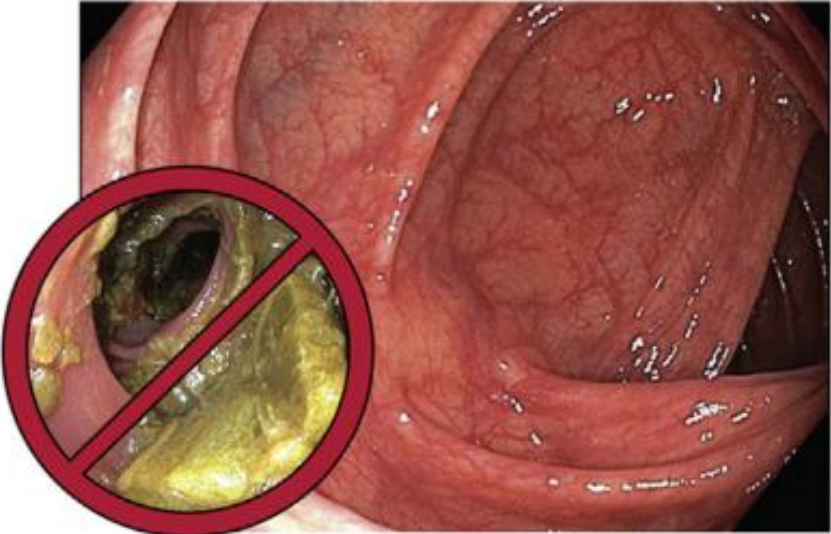
AGA Clinical Practice Update on Strategies to Improve Quality of Screening and Surveillance Colonoscopy: Expert Review

Rajesh N. Keswani,¹ Seth D. Crockett,² and Audrey H. Calderwood³

Keswani RN, et al. *Gastroenterology* 2021;161:701–711

Bowel prep adequacy rate
Goal: $\geq 90\%$, aspirational $\geq 95\%$

Boston Bowel Prep Score: ≥ 6



The image shows an endoscopic view of the colon. A red circle with a diagonal slash is overlaid on a section of the colon that contains yellowish stool, indicating that this area is not adequately prepared. The rest of the colon shown is clear.

Use split prep




The diagram illustrates a split bowel prep regimen. It shows two identical bottles, each labeled '1/2'. The first bottle is set against a night background with a crescent moon and stars, with the text '1st half: night before procedure' below it. The second bottle is set against a morning background with a sun, with the text '2nd half: morning of procedure' below it.

1st half: night before procedure

2nd half: morning of procedure

Keswani RN, et al. Gastroenterology 2021;161:701–711

**Colon mal
Preparado**

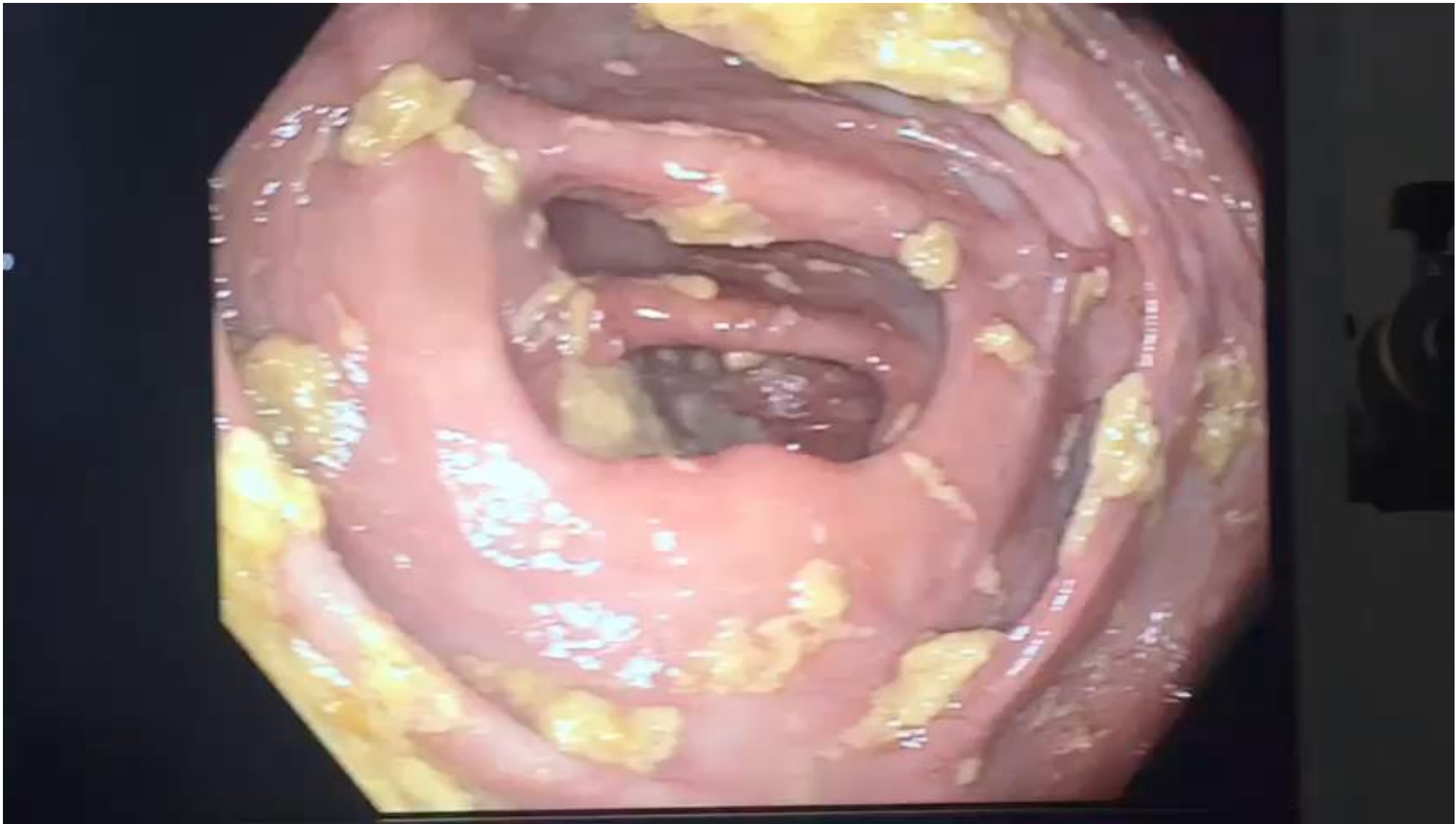

**Impacta negativamente
los principales
Indicadores de calidad**

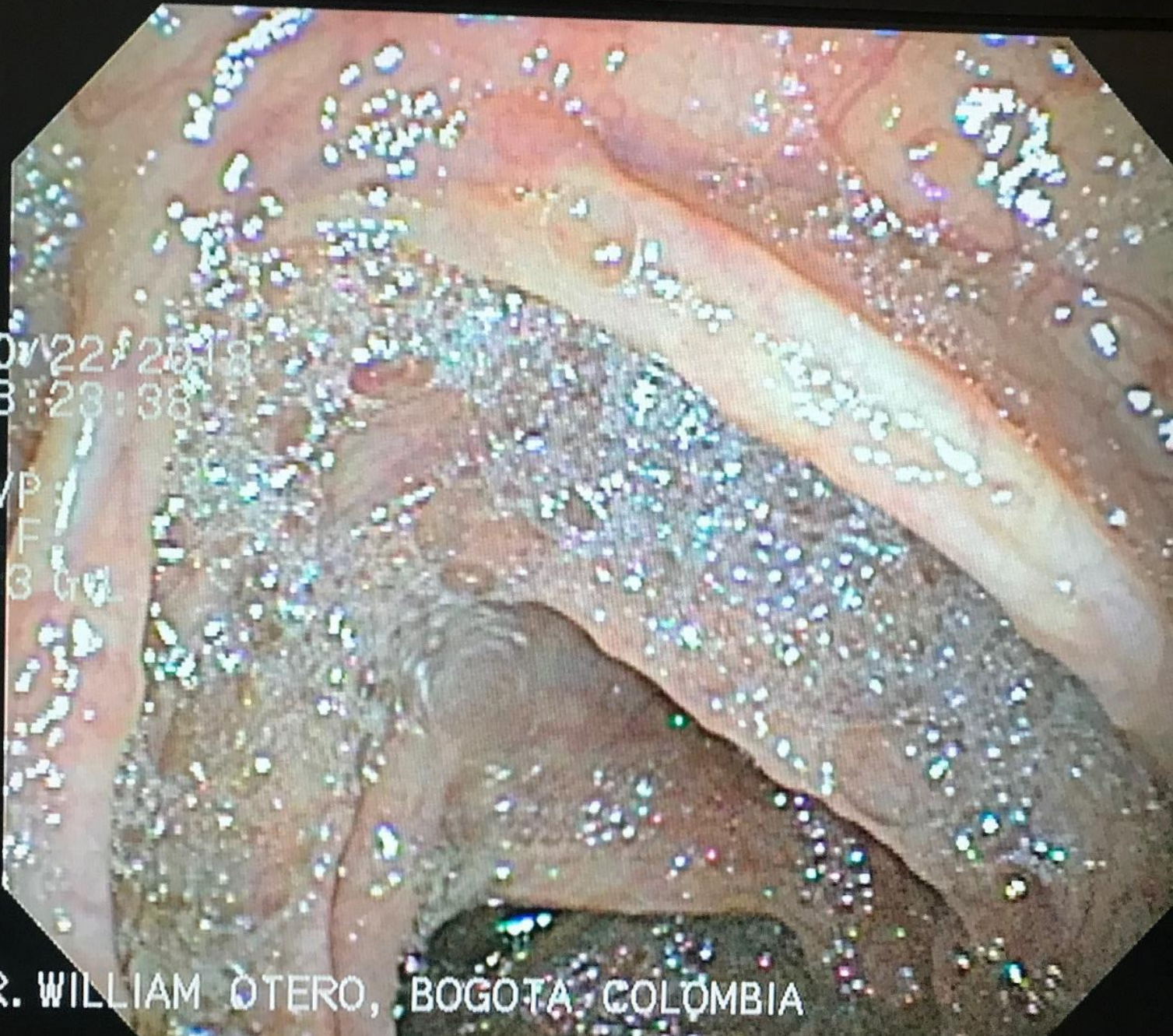
> Colonoscopias

Más costos

ASGE 2016, AGA 2021, ESGE 2019



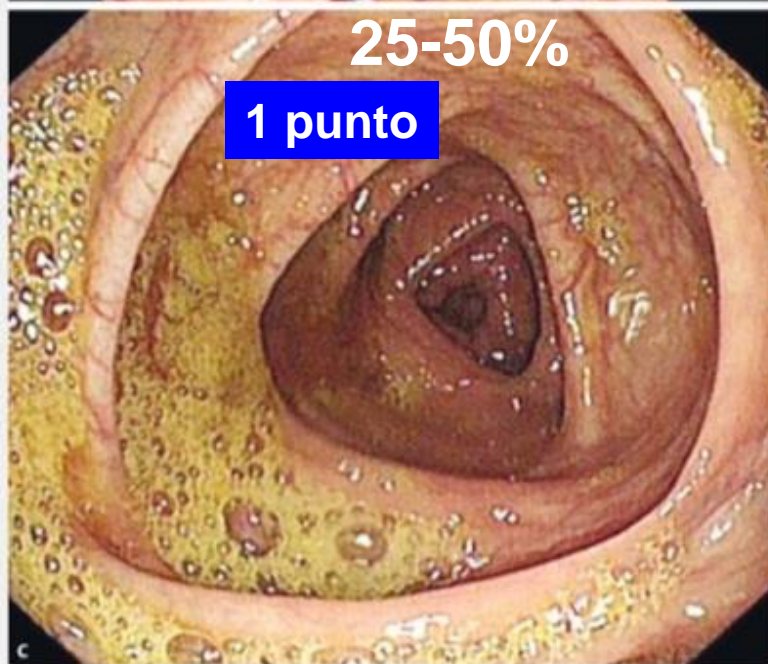
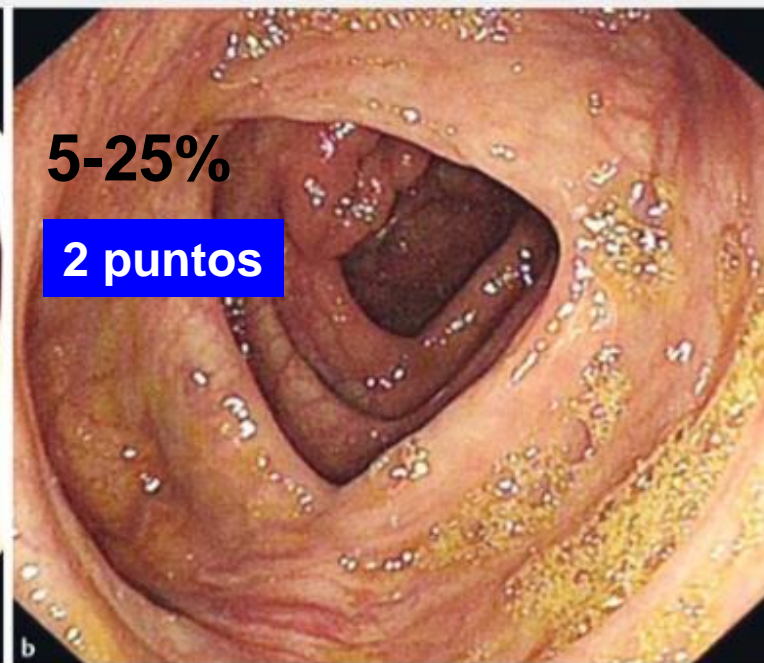
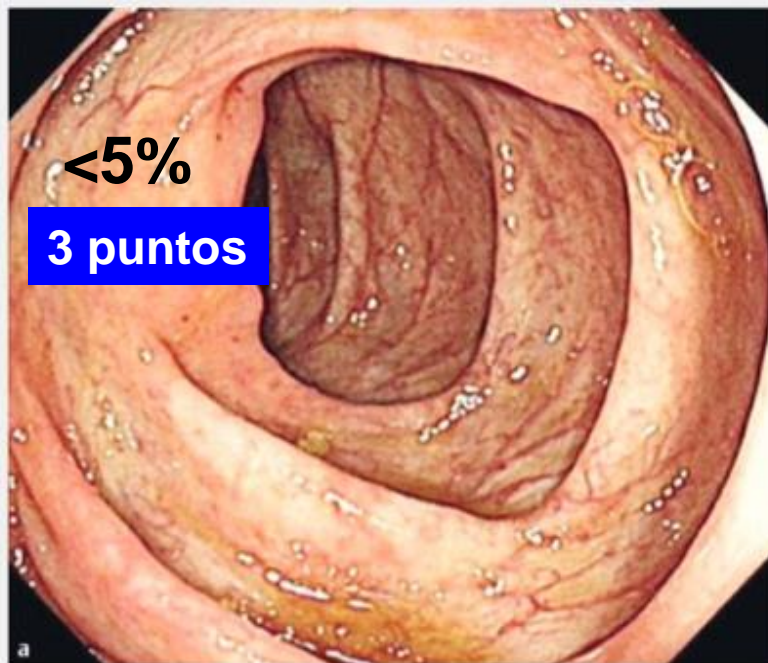
**Cortesía profesor Martín Gómez
Hospital Universitario Nacional**

An endoscopic view of the gastrointestinal tract showing a mucosal surface with a large, dark, lobulated polypoid lesion. The lesion is covered with a dense layer of small, dark, granular material. The surrounding mucosa is pinkish and shows some vascular patterns. The image is overlaid with white text in the lower-left corner.

10/22/2018
08:23:38

CVP
D. F.
Et: 3 Gr

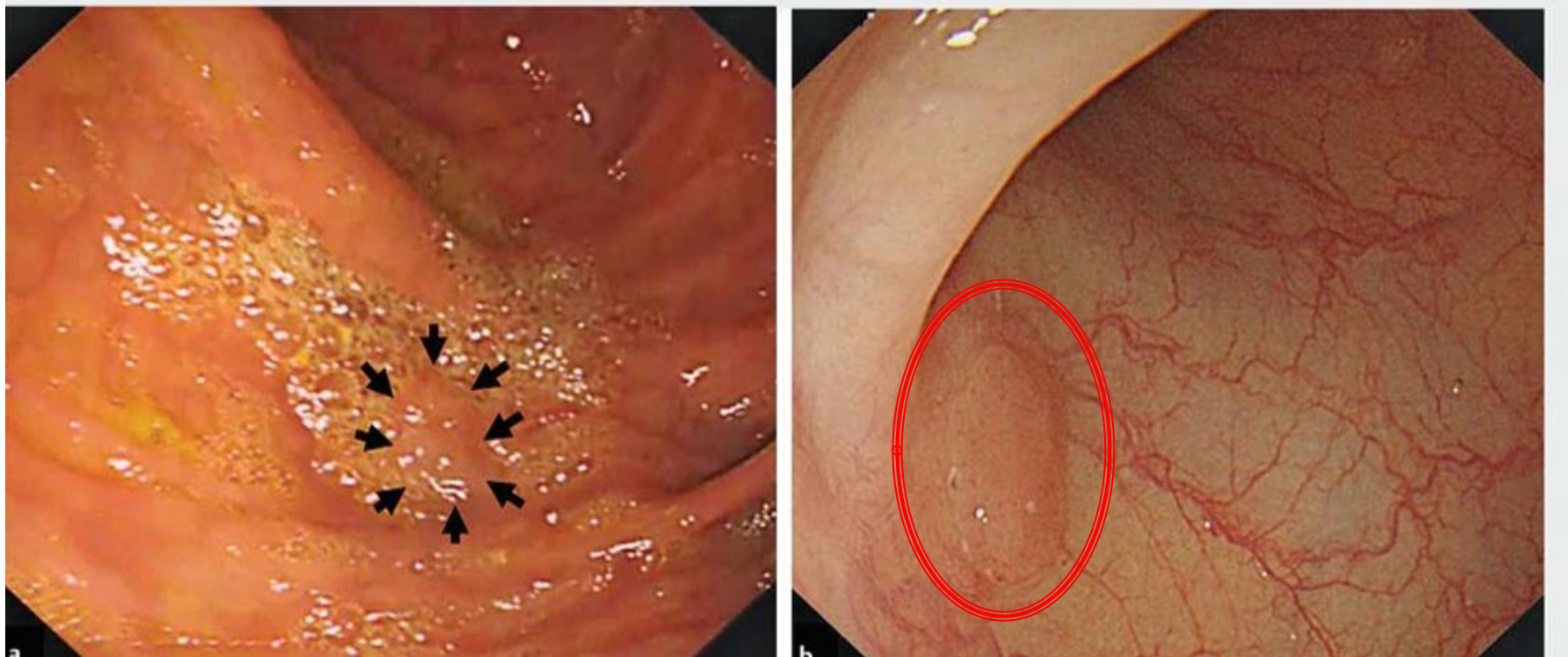
DR. WILLIAM OTERO, BOGOTA, COLOMBIA



Impact of preprocedure simethicone on adenoma detection rate during colonoscopy: a multicenter, endoscopist-blinded randomized controlled trial

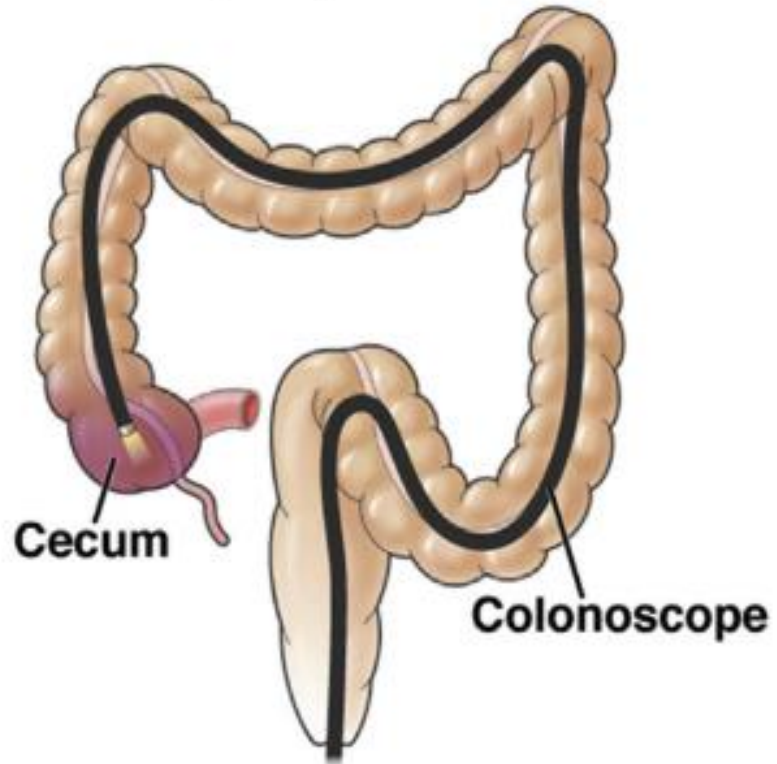
Authors

Yu Bai^{1,*}, Jun Fang^{1,2,*}, Sheng-Bing Zhao¹, Dong Wang¹, Yan-Qing Li³, Rui-Hua Shi⁴, Zi-Qin Sun⁵, Ming-Jun Sun⁶, Feng Ji⁷, Jian-Min Si⁸, Zhao-Shen Li¹



Cecal intubation rate

Goal: $\geq 90\%$, aspirational $\geq 95\%$



Withdrawal time

Goal: ≥ 6 min, aspirational ≥ 9 min



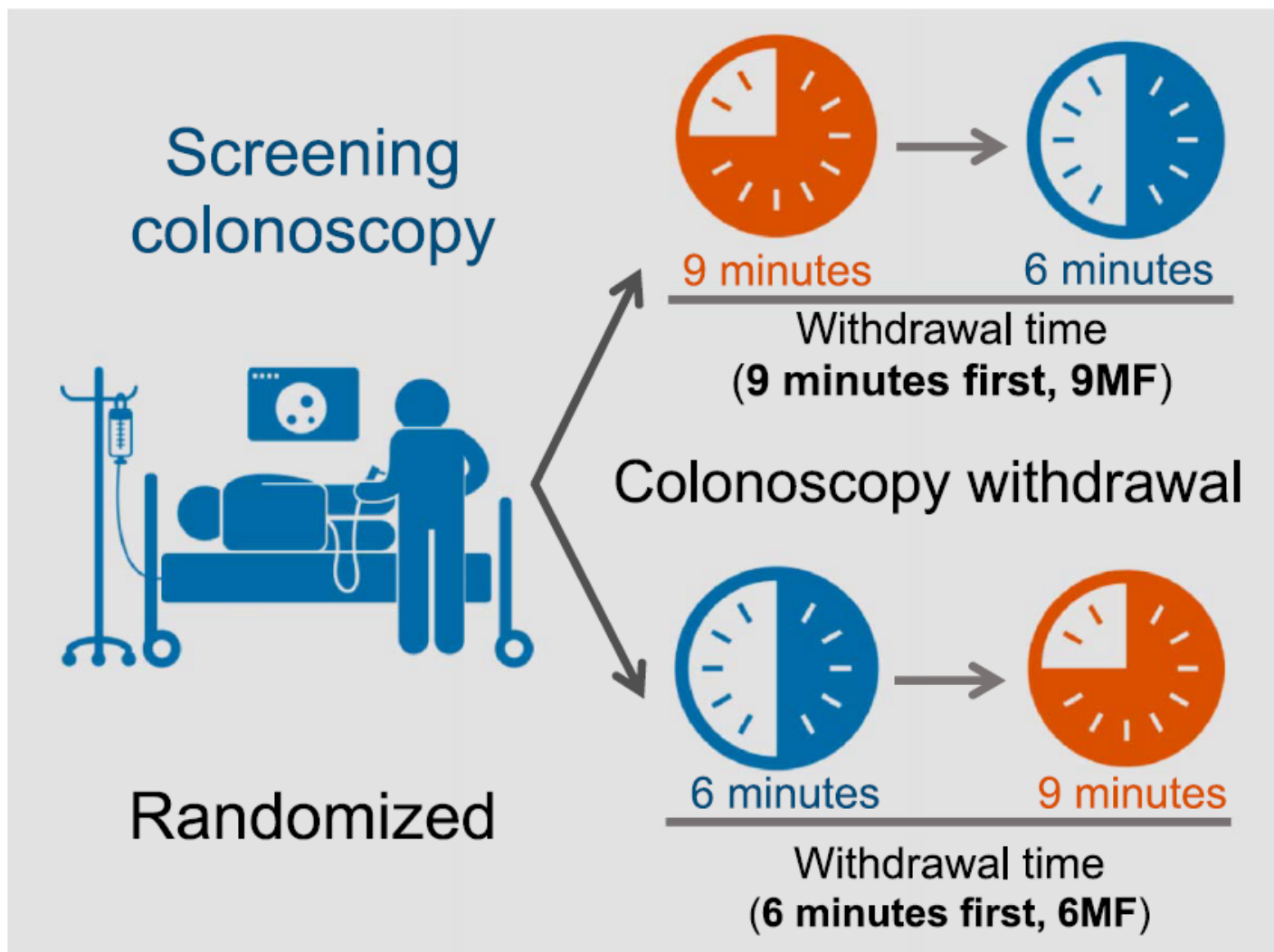
9-Minute Withdrawal Time Improves Adenoma Detection Rate Compared With 6-Minute Withdrawal Time During Colonoscopy

A Meta-analysis of Randomized Controlled Trials

Muhammad Aziz, MD, Hossein Haghbin, MD,†
Manesh Kumar Gangwani, MD,‡ Mohamad Nawras, BSc,‡
Yusuf Nawras, BSc,‡ Dushyant Singh Dahiya, MD,§
Amir Humza Sohail, MD,|| Wade Lee-Smith, MLS, BS,¶
Faisal Kamal, MD,# and Aasma Shaukat, MD, MPH***

Conclusion: The 9-minute withdrawal time improved ADR and APC compared with the 6-minute withdrawal. Given the high-quality evidence, we recommend that clinicians at least perform a 9-minute withdrawal to achieve higher quality metrics including ADR to reduce interval CRC.

9-minute withdrawal time reduces adenoma miss rate of screening colonoscopy



9 MF versus 6 MF

Reduced adenoma miss rate
14.5% vs. 36.6%, $p < 0.001$

Reduced advanced
adenoma miss rate
5.3% vs. 46.9%, $p < 0.001$

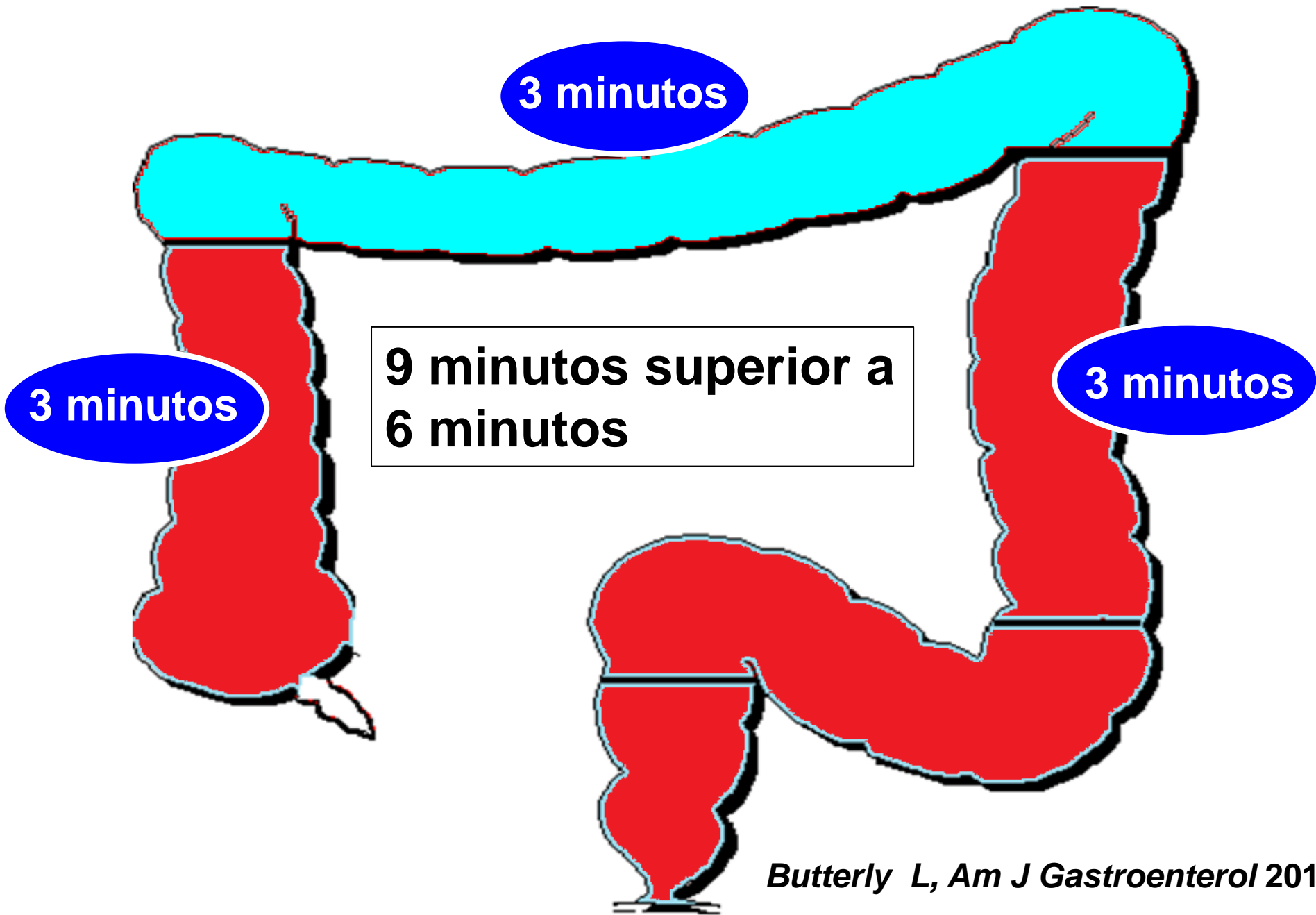
Lower rate of shortening
surveillance interval
7.7% vs. 16.1%, $p < 0.001$

6 minutos



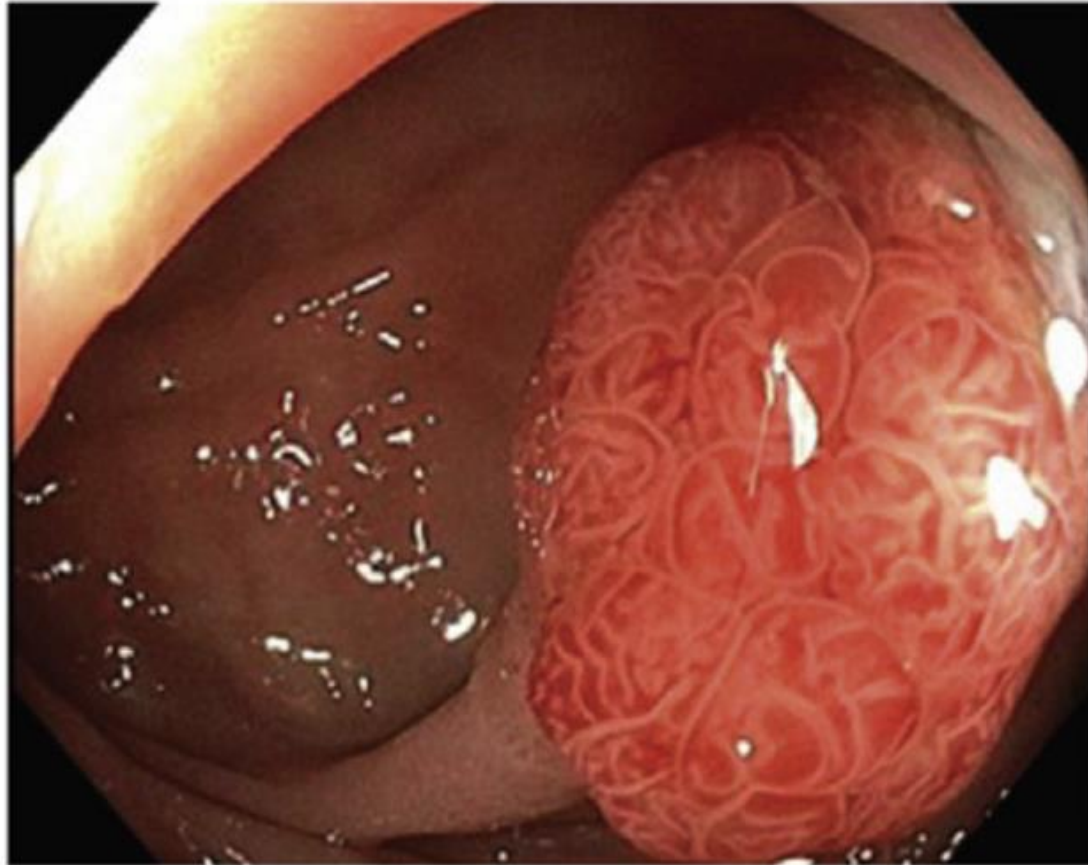
2023

9 minutos



Adenoma detection rate

Goal: $\geq 30\%$, aspirational $\geq 35\%$



Adenoma Detection Rate and Risk of Colorectal Cancer and Death

Douglas A. Corley, M.D., Ph.D., Christopher D. Jensen, Ph.D., Amy R. Marks, M.P.H.,
Wei K. Zhao, M.P.H., Jeffrey K. Lee, M.D., Chyke A. Doubeni, M.D., M.P.H.,
Ann G. Zauber, Ph.D., Jolanda de Boer, M.B., Bruce H. Fireman, Ph.D.,
Joanne E. Schottinger, M.D., Virginia P. Quinn, Ph.D., Nirupa R. Ghai, Ph.D.,
Theodore R. Levin, M.D., and Charles P. Quesenberry, Ph.D.

↓ **Incidencia CCR**

↓ **Mortalidad por CCR**

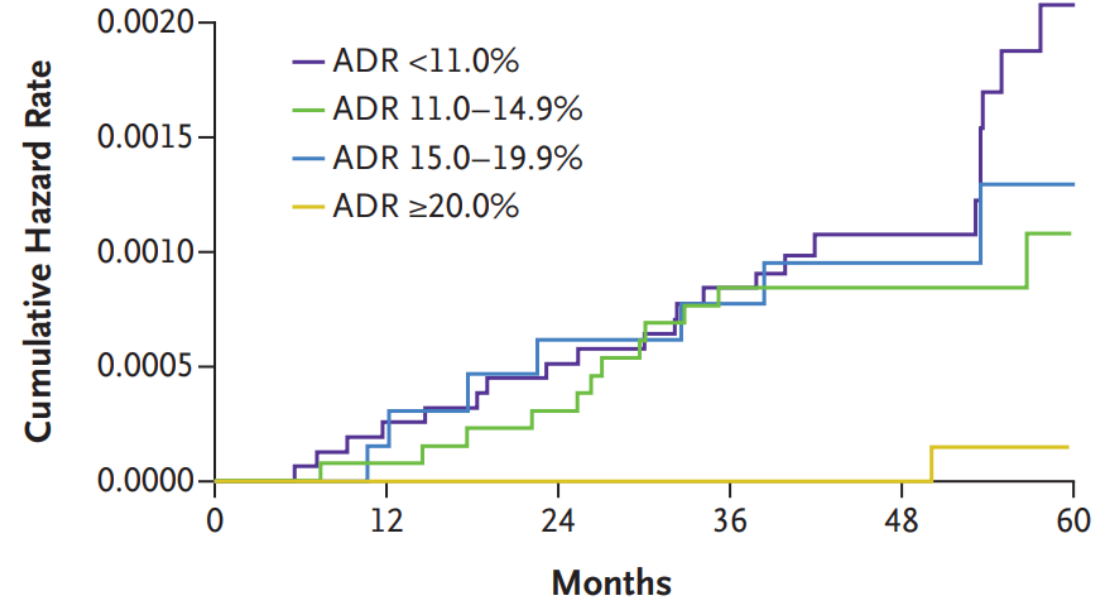
Cada 1% ADR

< Mortalidad CCR 3%

Quality Indicators for Colonoscopy and the Risk of Interval Cancer

Michal F. Kaminski, M.D., Jaroslaw Regula, M.D., Ewa Kraszewska, M.Sc.,
Marcin Polkowski, M.D., Urszula Wojciechowska, M.D., Joanna Didkowska, M.D.,
Maria Zwierko, M.D., Maciej Rupinski, M.D., Marek P. Nowacki, M.D.,
and Eugeniusz Butruk, M.D.

ADR >20% 0.011%
ADR < 20% 0.115%
10 veces !!



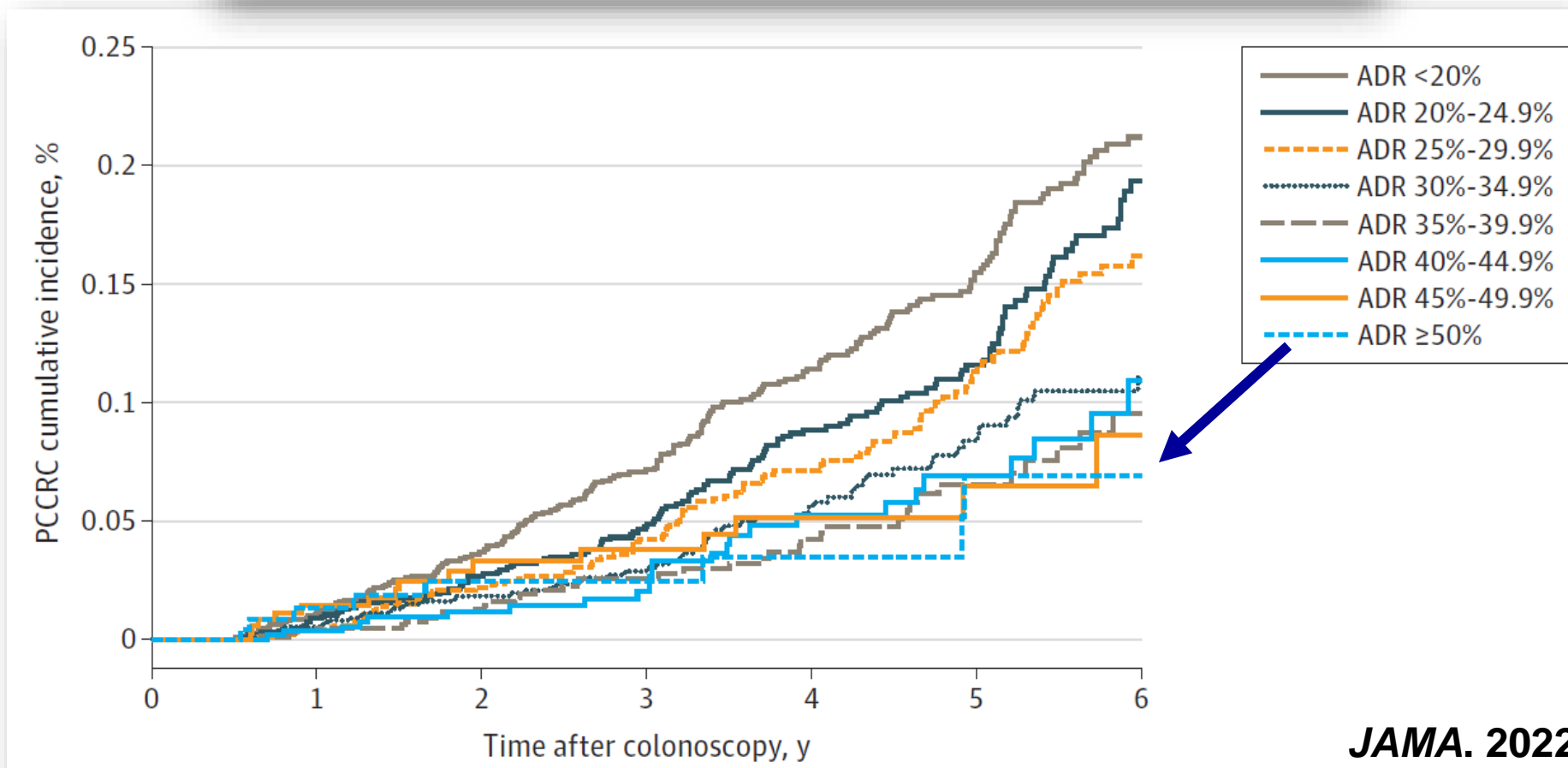
No. at Risk

ADR <11.0%	15,883	15,805	15,744	15,669	9355	4717
ADR 11.0-14.9%	13,281	13,223	13,182	13,120	7571	4003
ADR 15.0-19.9%	6,607	6,582	6,562	6,539	4022	2529
ADR ≥20.0%	9,255	9,235	9,202	9,166	7155	5548

Association of Physician Adenoma Detection Rates With Postcolonoscopy Colorectal Cancer

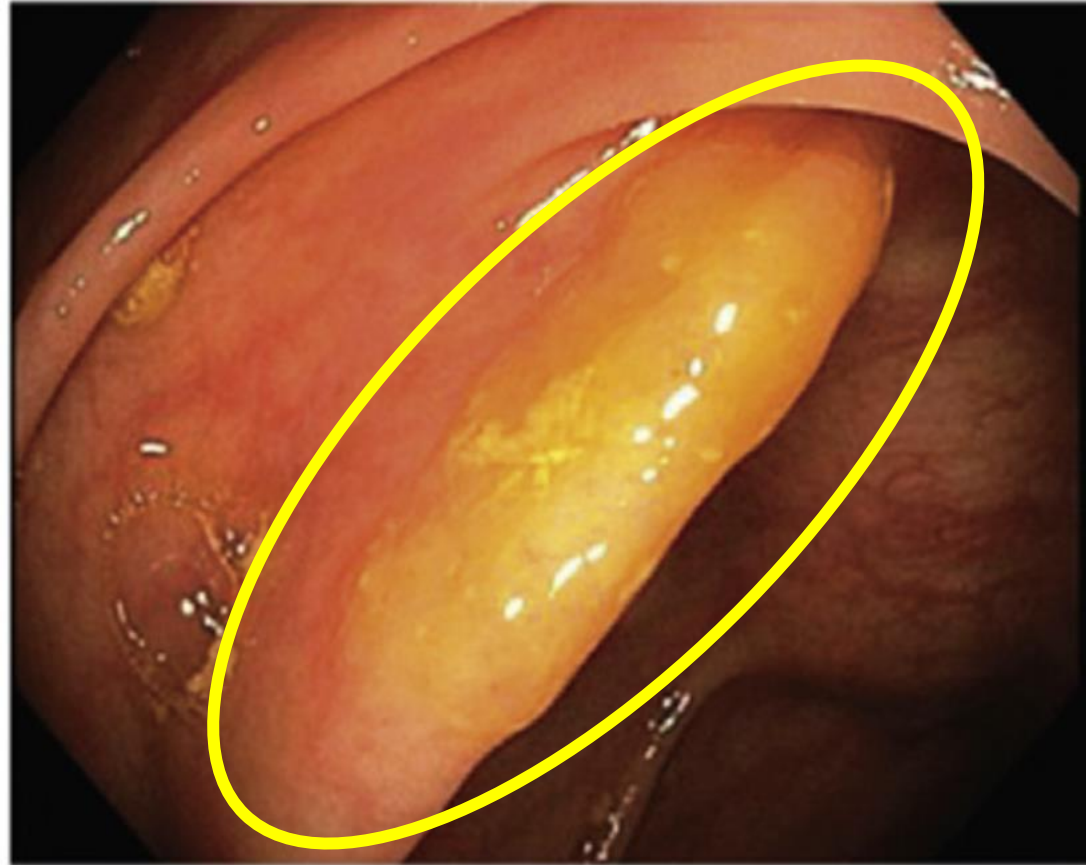
Joanne E. Schottinger, MD; Christopher D. Jensen, PhD; Nirupa R. Ghai, PhD; Jessica Chubak, PhD; Jeffrey K. Lee, MD; Aruna Kamineni, PhD; Ethan A. Halm, MD; Celette Sugg-Skinner, PhD; Natalia Udaltsova, PhD; Wei K. Zhao, MPH; Rebecca A. Ziebell, BS; Richard Contreras, MS; Eric J. Kim, MS; Bruce H. Fireman, MA; Charles P. Quesenberry, PhD; Douglas A. Corley, MD

Càncer
Pos colonoscopia



Serrated lesion detection rate

Goal: $\geq 7\%$, aspirational $\geq 10\%$



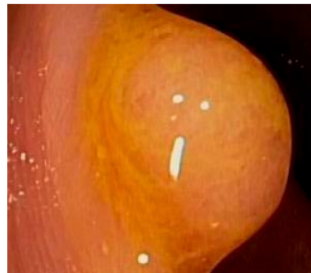
Keswani RN, et al. *Gastroenterology* 2021;161:701–711

Higher Serrated Polyp Detection Rates Are Associated With Lower Risk of Postcolonoscopy Colorectal Cancer: Data From the New Hampshire Colonoscopy Registry

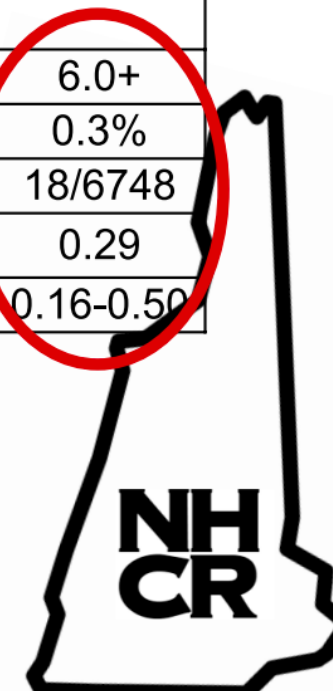
Joseph C. Anderson, MD^{1,2,3,4}, Douglas K. Rex, MD⁵, Todd A. Mackenzie, PhD¹, William Hisey, MSc^{3,6}, Christina M. Robinson, MS^{3,6} and Lynn F. Butterly, MD^{1,3,6}

Endoscopist SSLDR and Post Colonoscopy CRC Risk

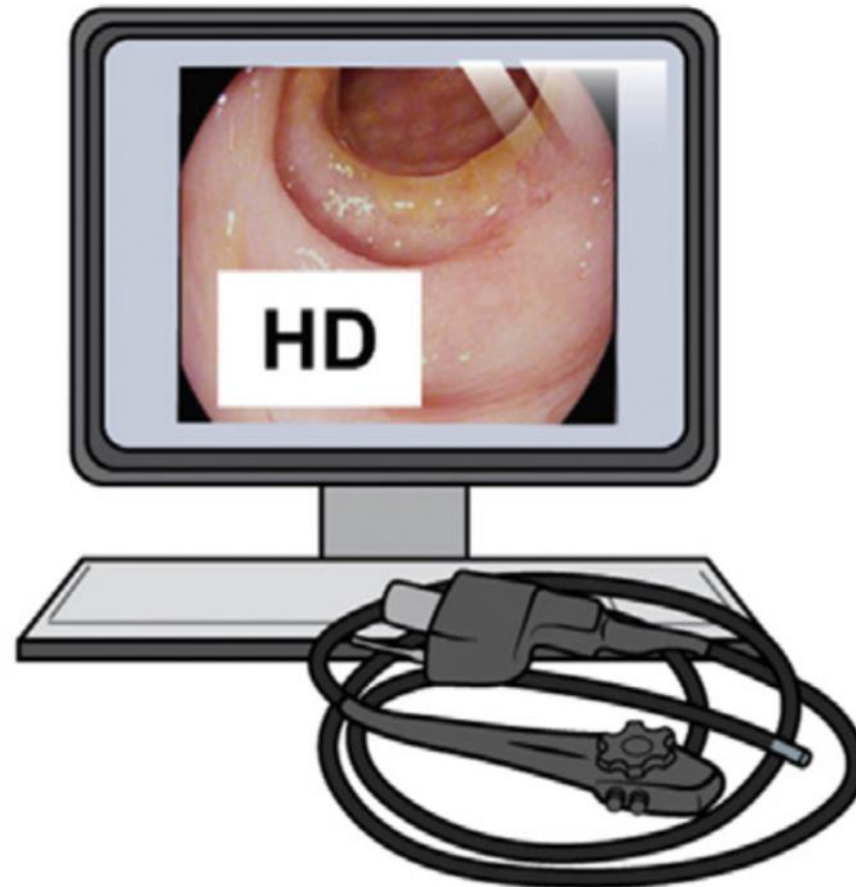		Sessile serrated lesion Detection Rate (SSLDR)				
		<1.0	1.0-<2.0	2.0-<4.0	4.0-< 6.0	6.0+
Unadjusted risk	%	1.4%	0.6%	0.6%	0.4%	0.3%
	N	58/4117	46/8075	22/3950	18/4011	18/6748
Adjusted Hazard	HR	1.0	0.41	0.45	0.38	0.29
	95% CI	Ref	0.28-0.61	0.27-0.75	0.22-0.66	0.16-0.50



SSLDR of 6% or greater provided optimal protection from PCCRC



Use high-definition colonoscopes



**Colonoscopia menos eficaz
para prevenir CCR derecho**



Pálidas, Planas, entre haustras



Colono360° ,

“Endocuff”



**Cambios
Posición**



**Segunda
Mirada**



**Retroflexion
Proximal**

Baxter NN,. J Clin Oncol 2012; 30: 2664-9.

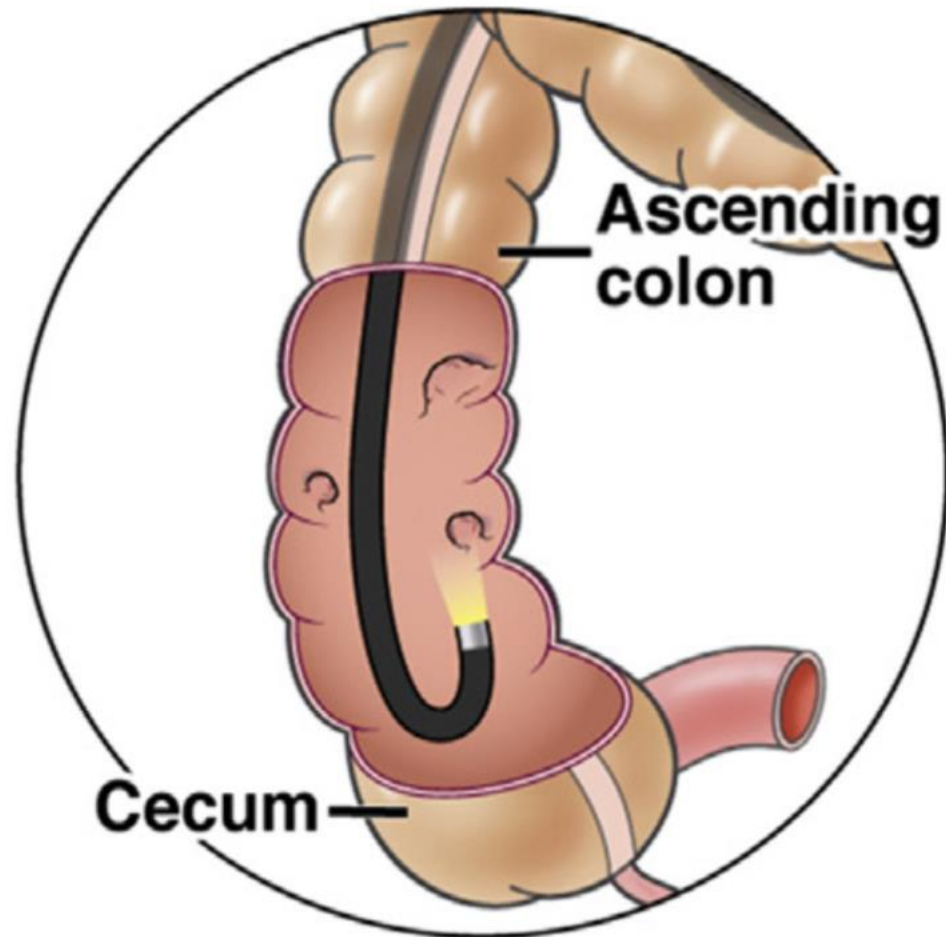
Brenner H, J Natl Cancer Inst 2010; 102: 89-95.

Rex DK. Endoscopy 2010; 42: 320–323.

Singh H, Gastroenterology 2010; 139: 1128-37.

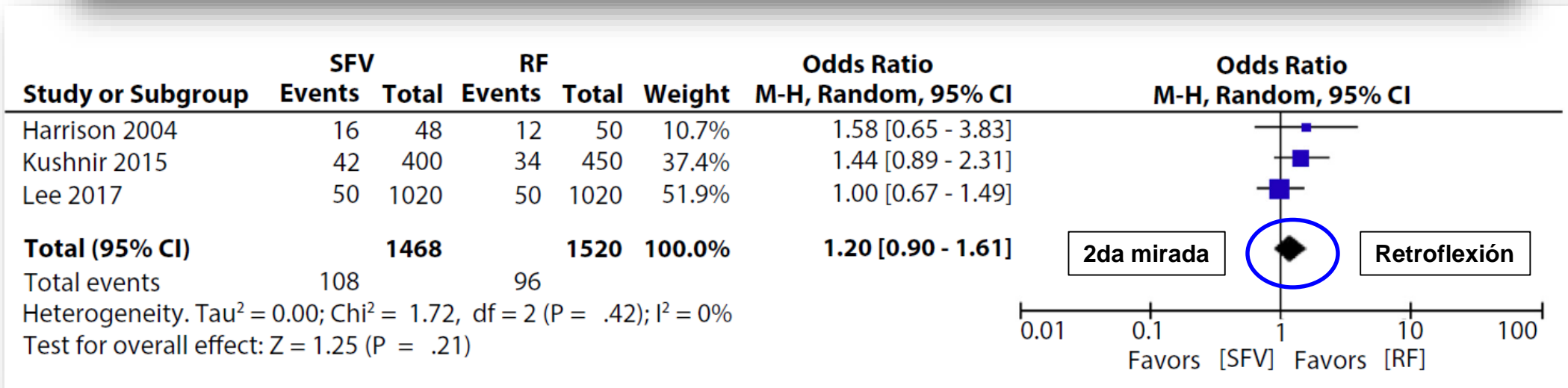
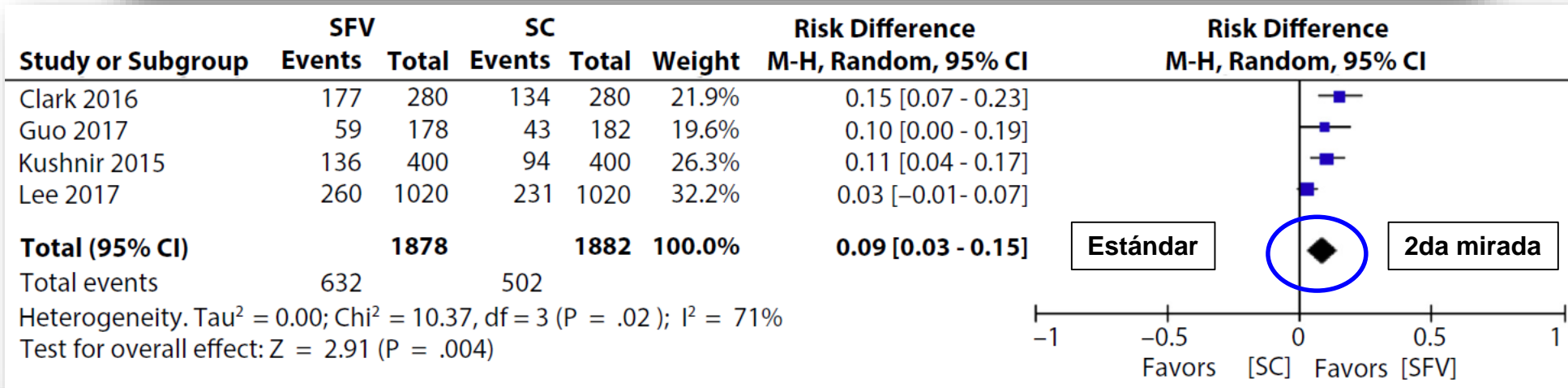
Rex DK, Clin Gastroenterol Hepatol 2020;18:158-62

Perform 2nd look in right colon

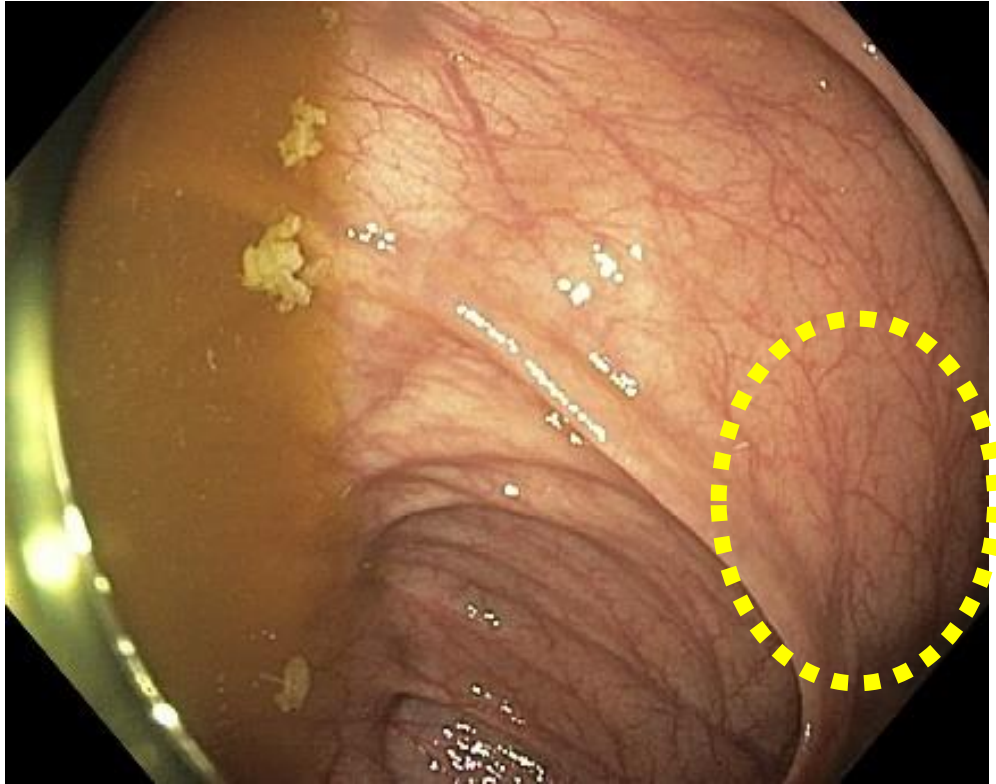


Increasing adenoma detection rates in the right side of the colon comparing retroflexion with a second forward view: a systematic review

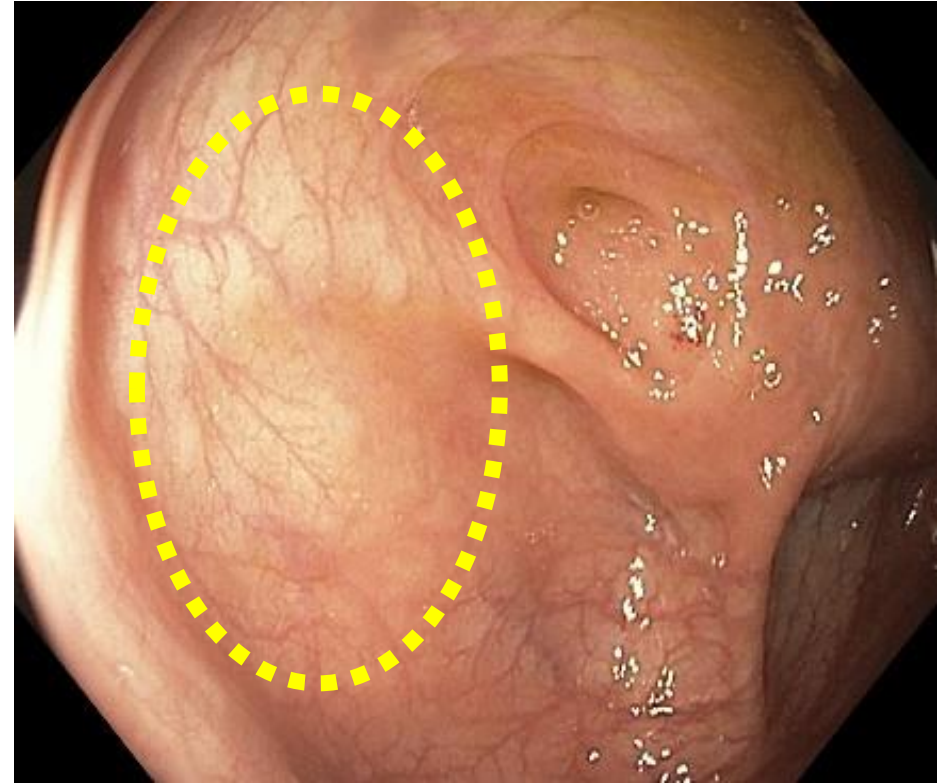
Madhav Desai, MD, MPH,¹ Mohammad Bilal, MD,⁶ Nour Hamade, MD,¹ Venkata Subhash Gorrepati, MD,⁵ Viveksandeep Thoguluva Chandrasekar, MD,¹ Ramprasad Jegadeesan, MD,¹ Neil Gupta, MD,³ Pradeep Bhandari, MD,² Alessandro Repici, MD,⁴ Cesare Hassan, MD,⁴ Prateek Sharma, MD¹



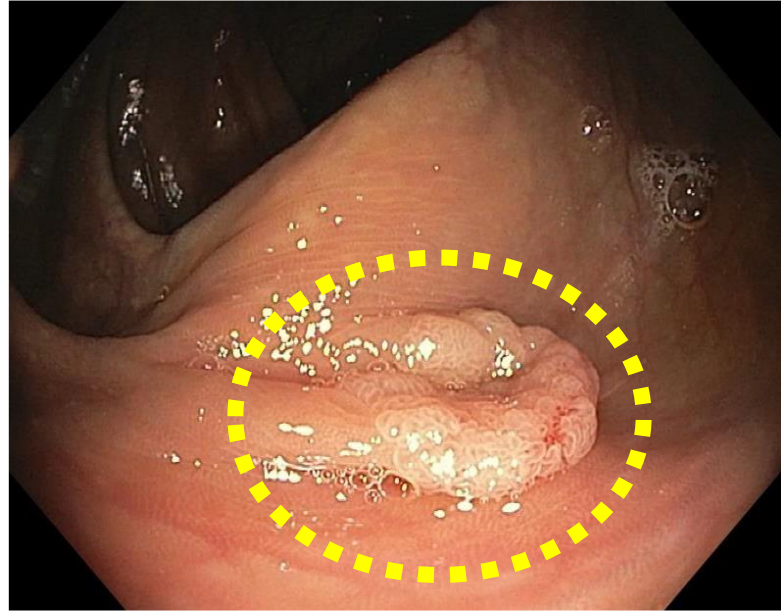
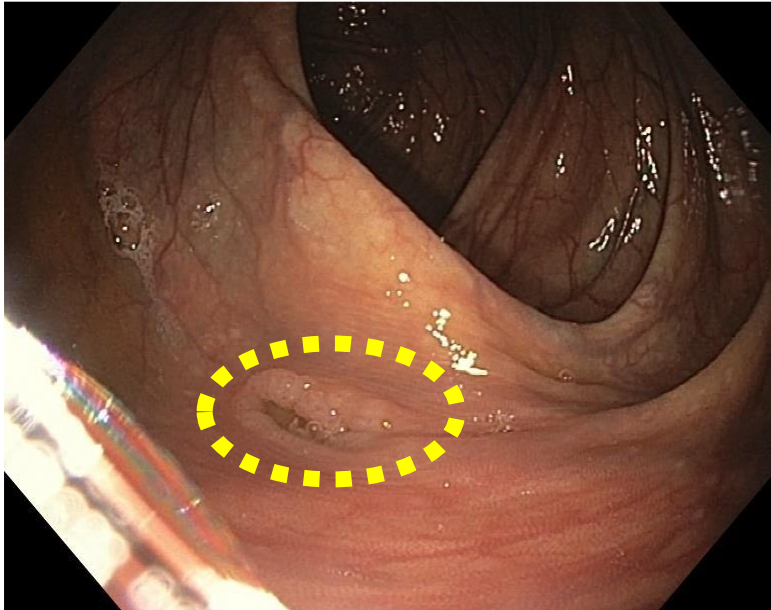
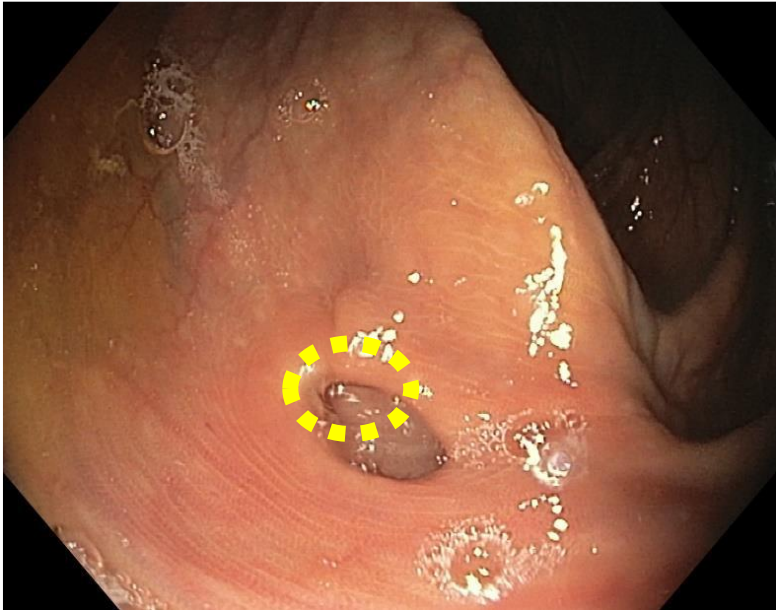
Ciego parcialmente visto



Ciego completamente visto

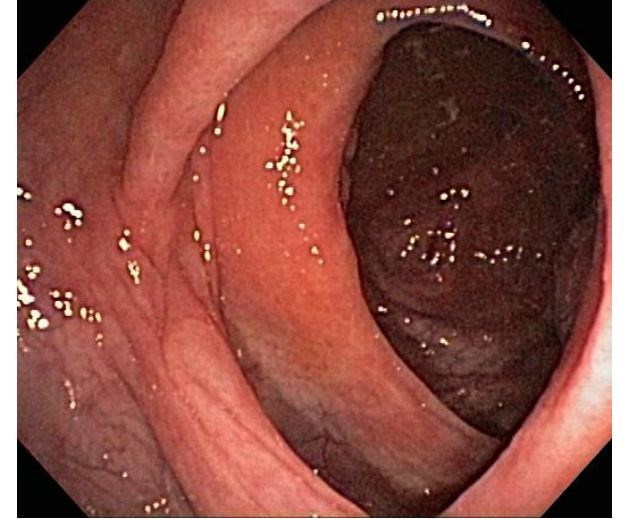
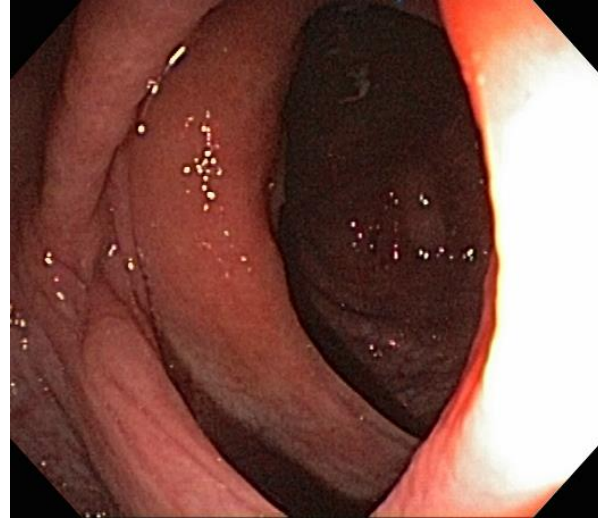


Febrero 2022

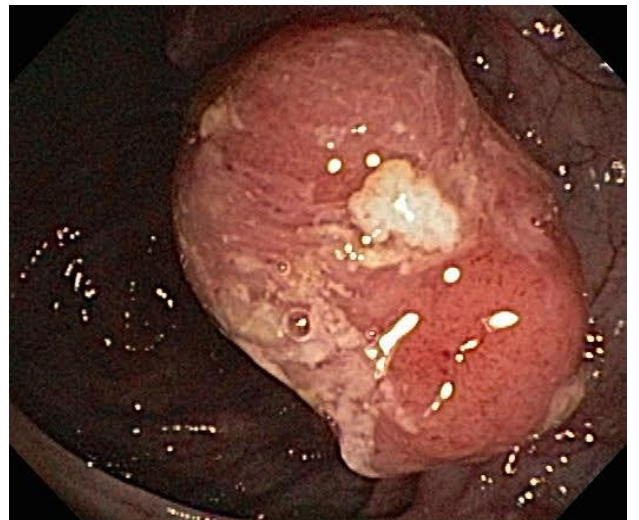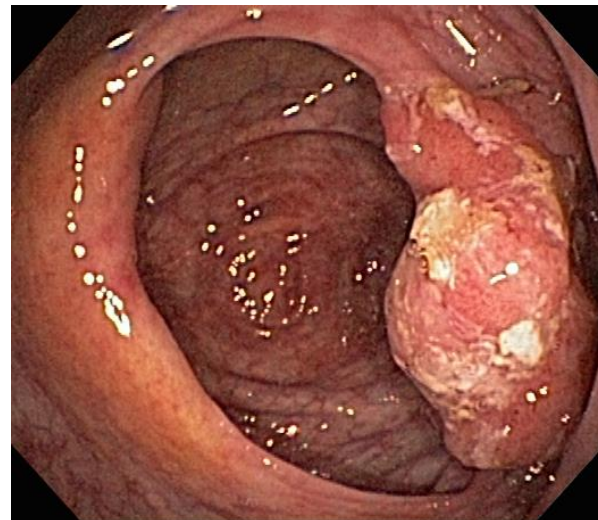



W. Otero 2022

Ciego parcialmente visto





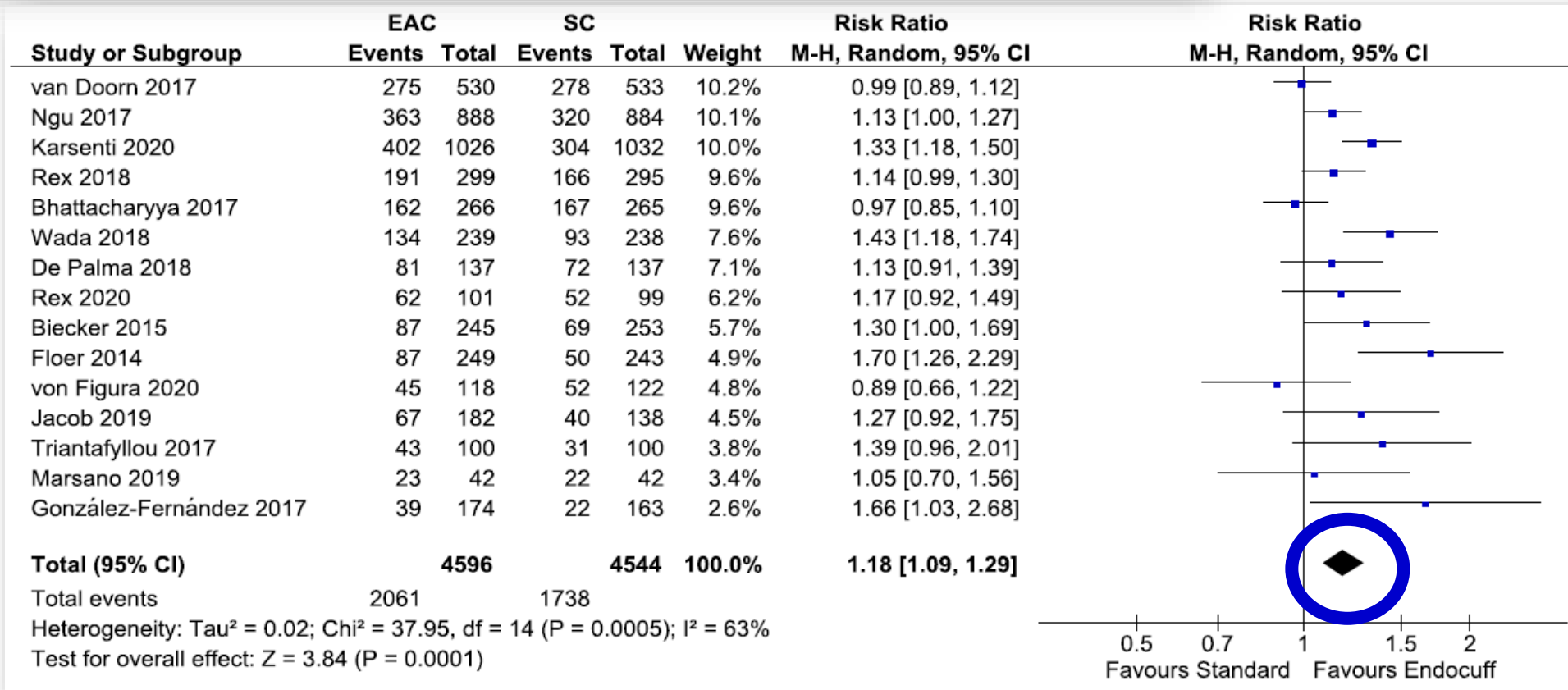
Ciego Completamente visto



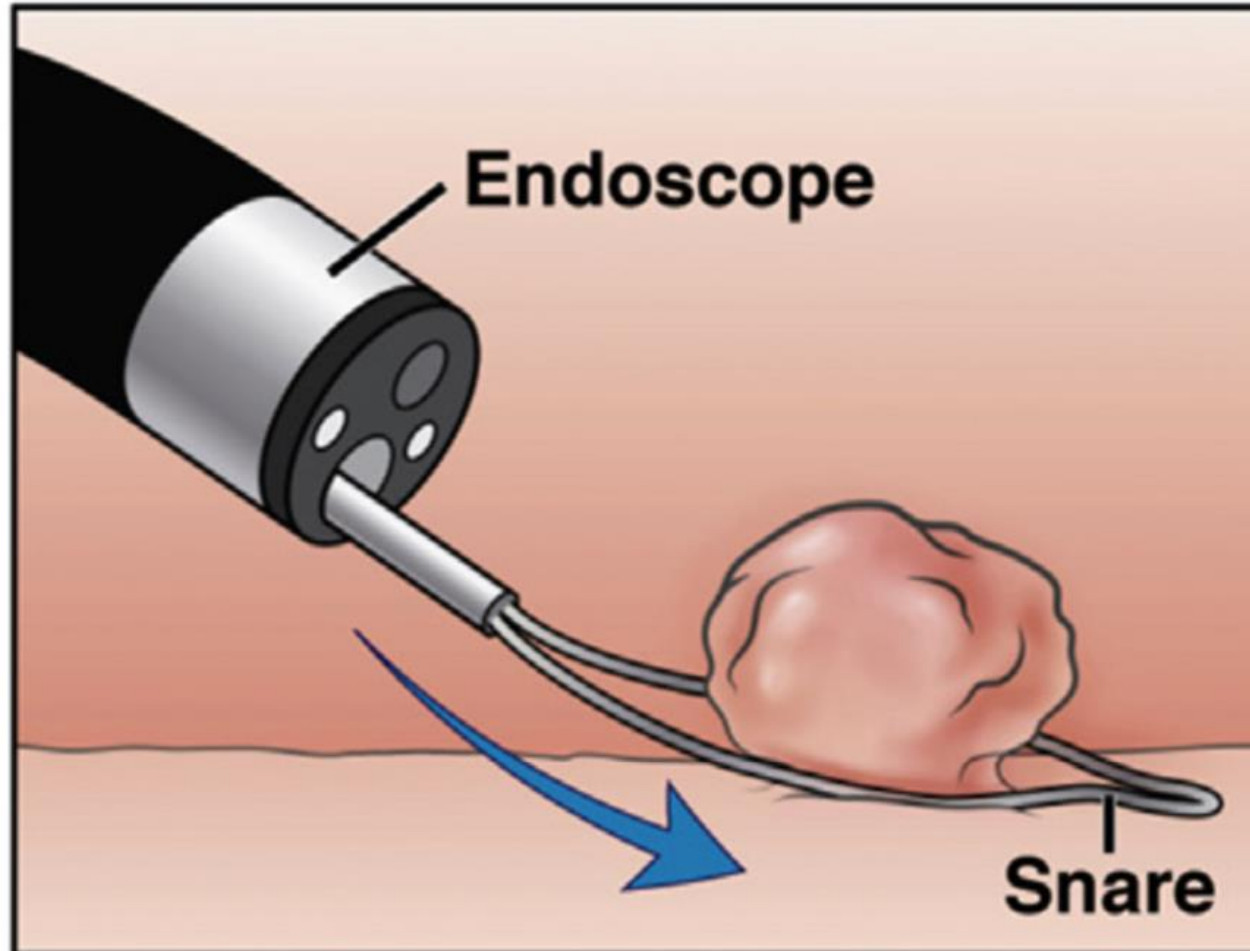


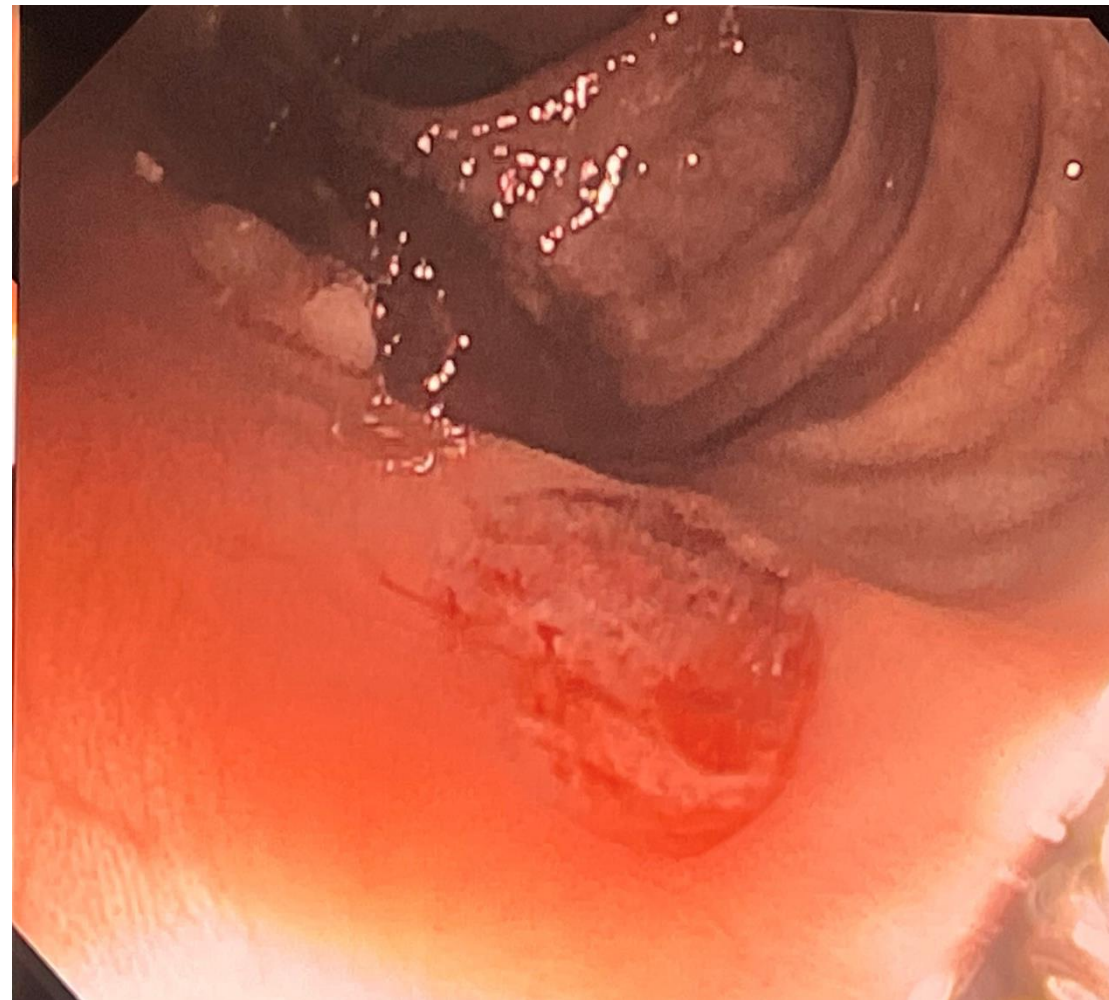
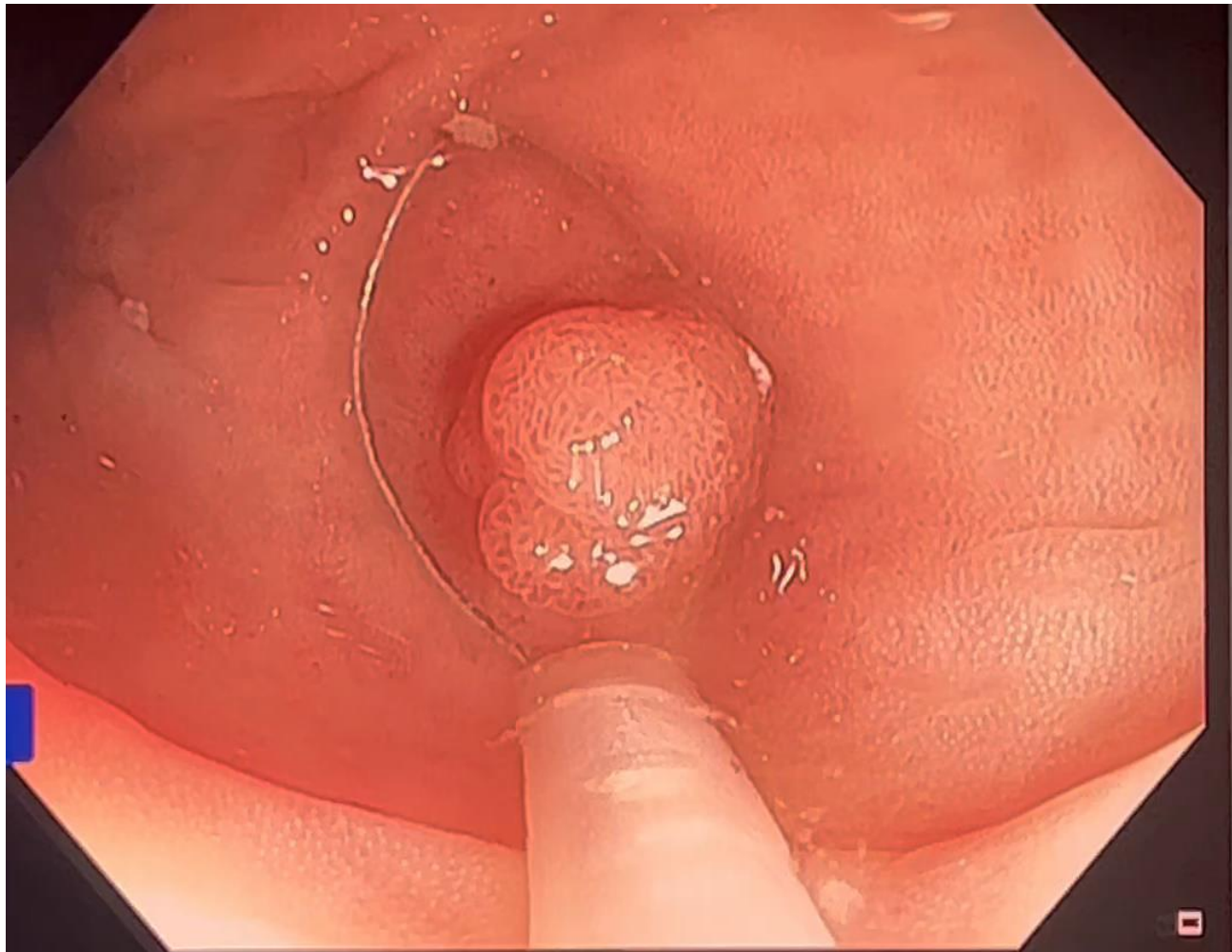
The effect of the endoscopic device Endocuff™/Endocuff vision™ on quality standards in colonoscopy: A systematic review and meta-analysis of randomized trials

Martin Walls^{1,2}  | Britt B. S. L. Houwen³ | Stephen Rice² | Alexander Seager^{1,2}  |
 Evelien Dekker³ | Linda Sharp² | Colin J. Rees^{1,2}

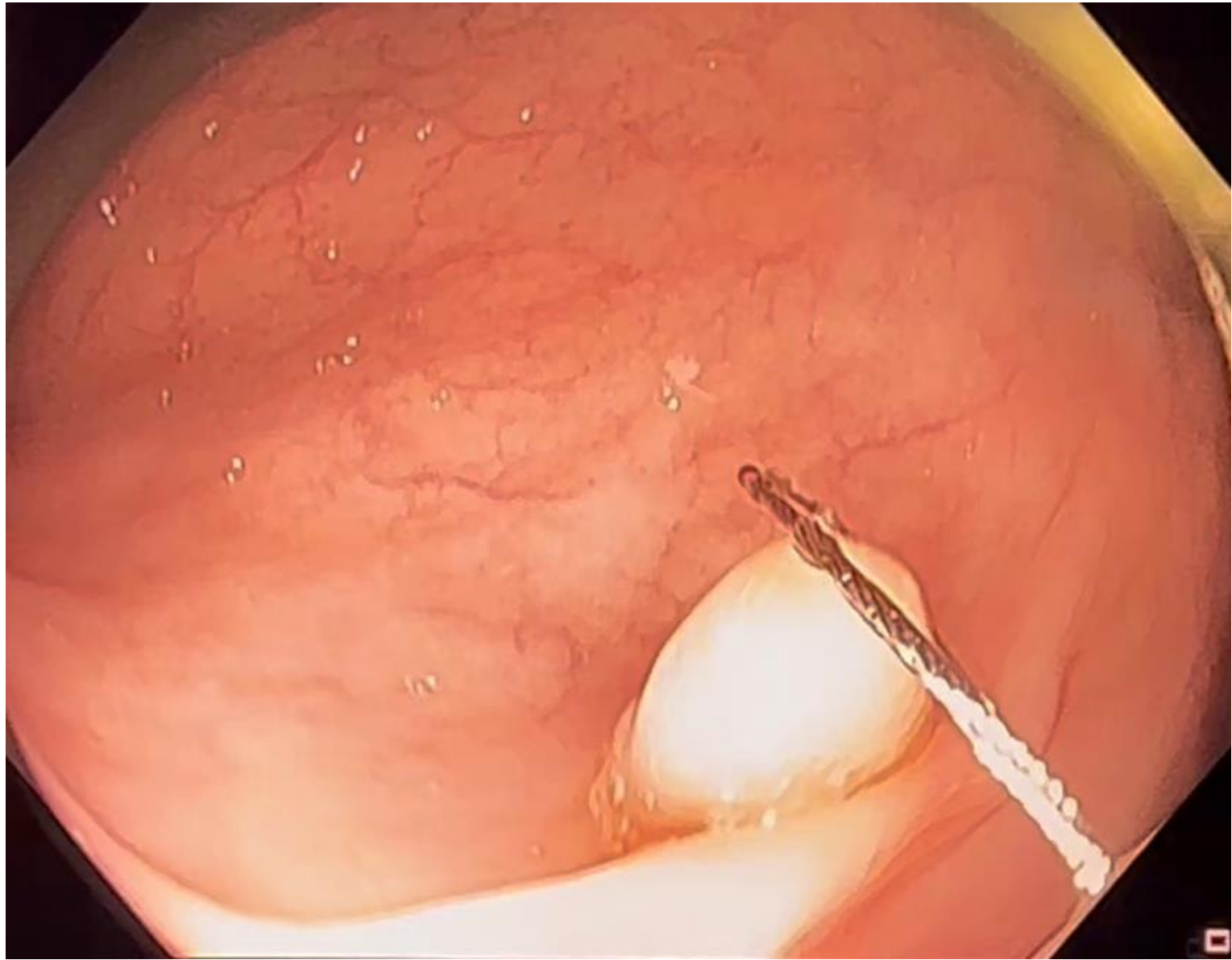


Use cold snares for all sessile polyps 3–9 mm

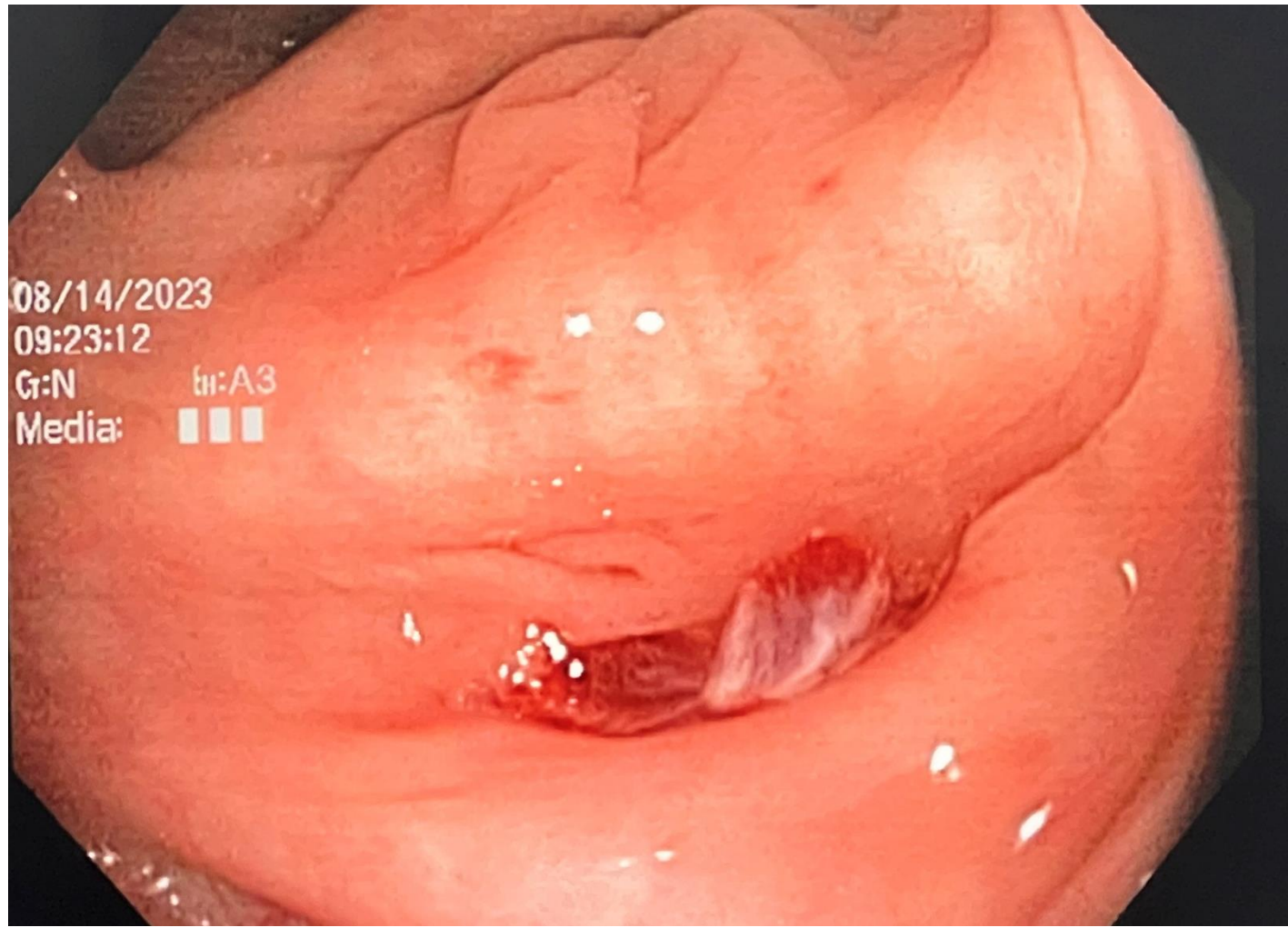




W Otero/23



W Otero/23



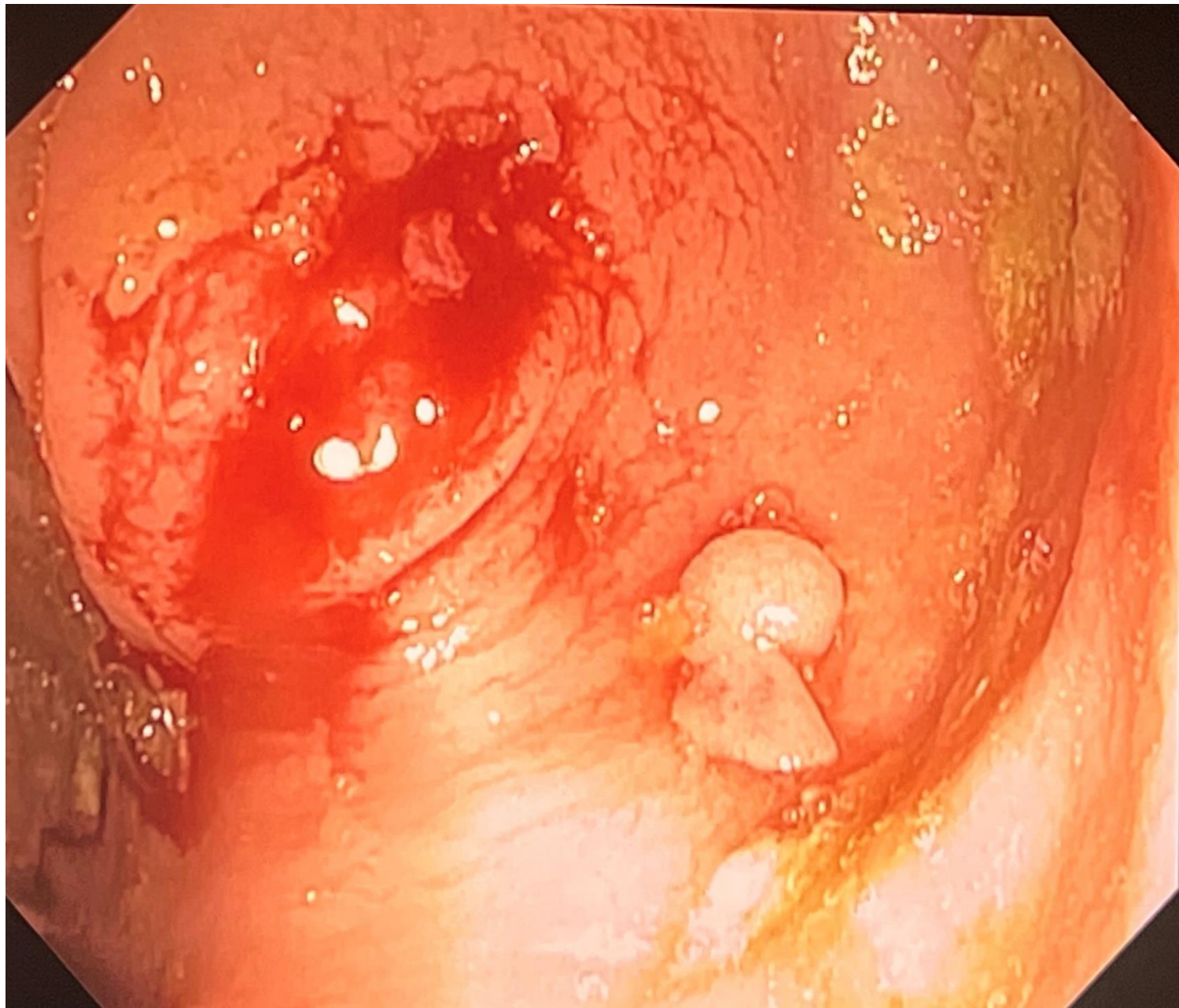
08/14/2023

09:23:12

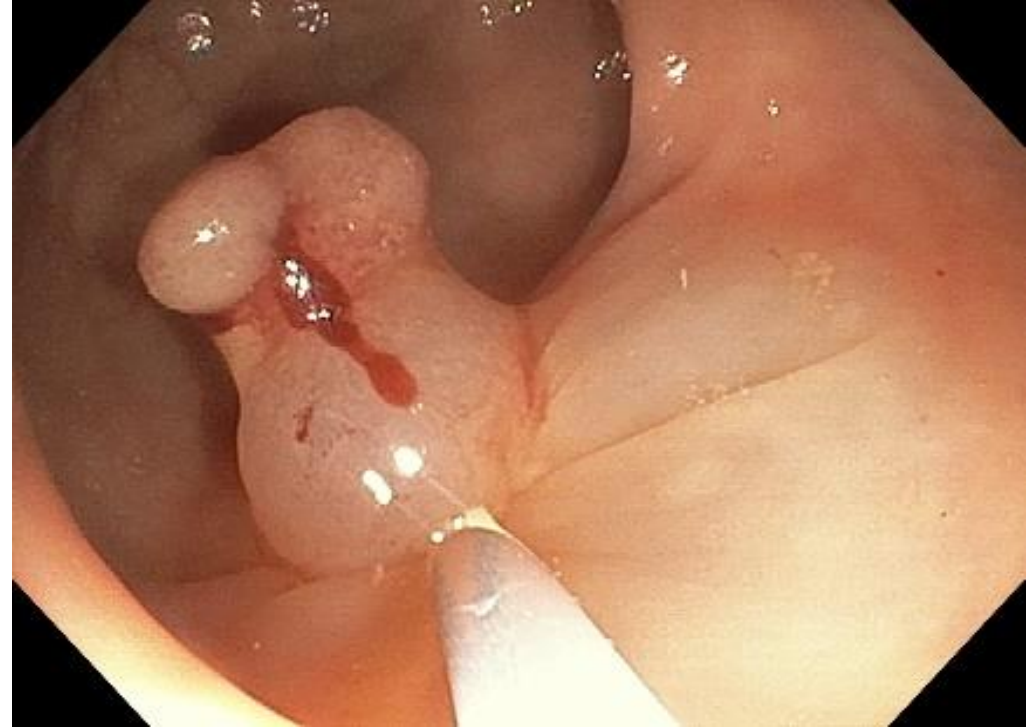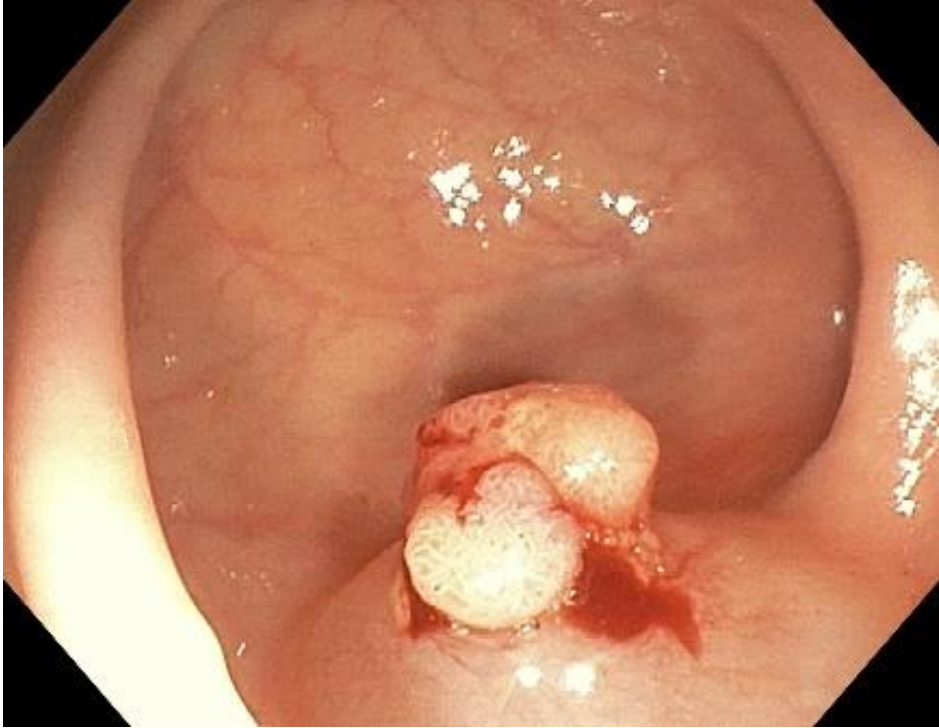Gr:N

Media: ■■■

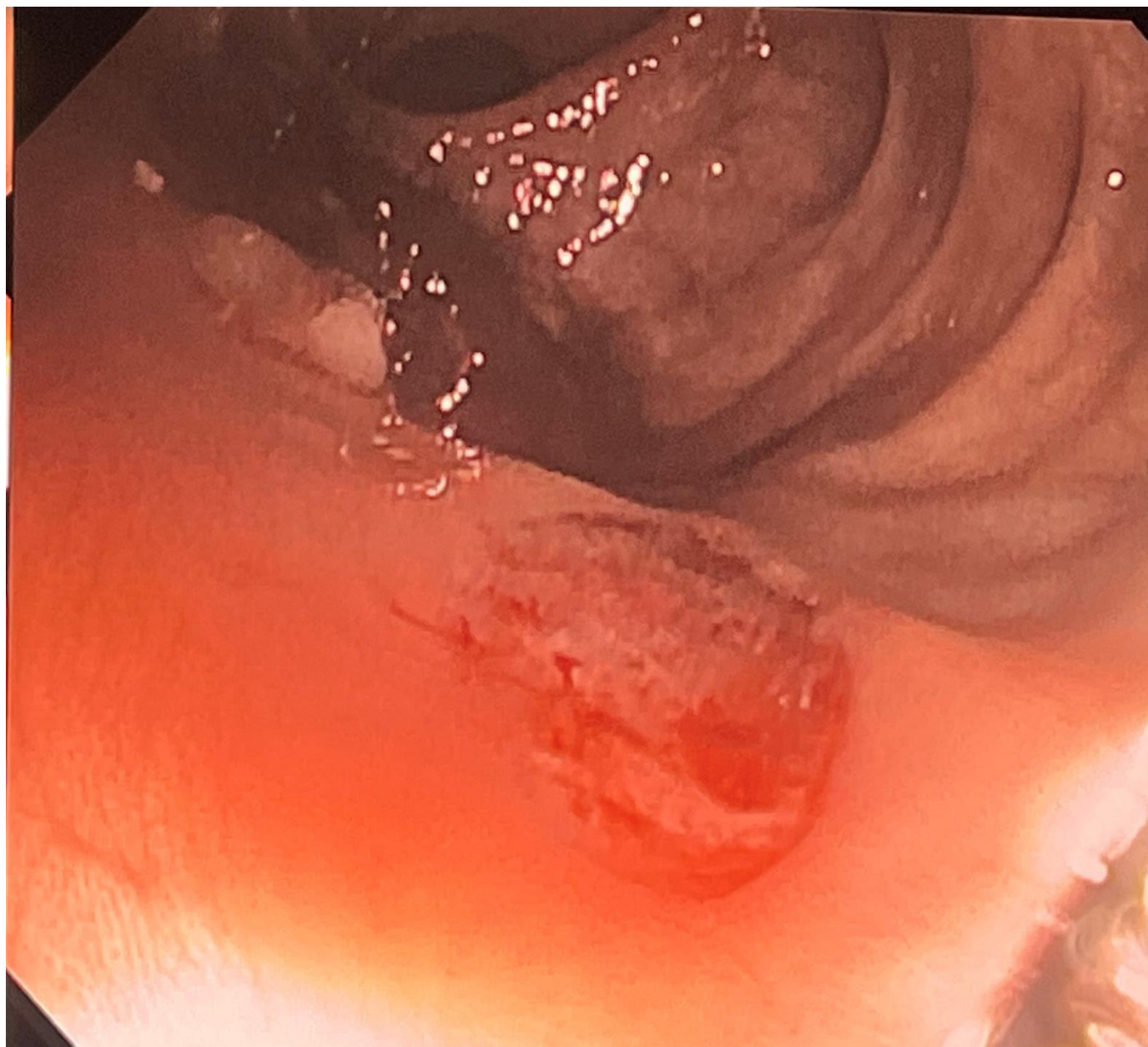tr:A3

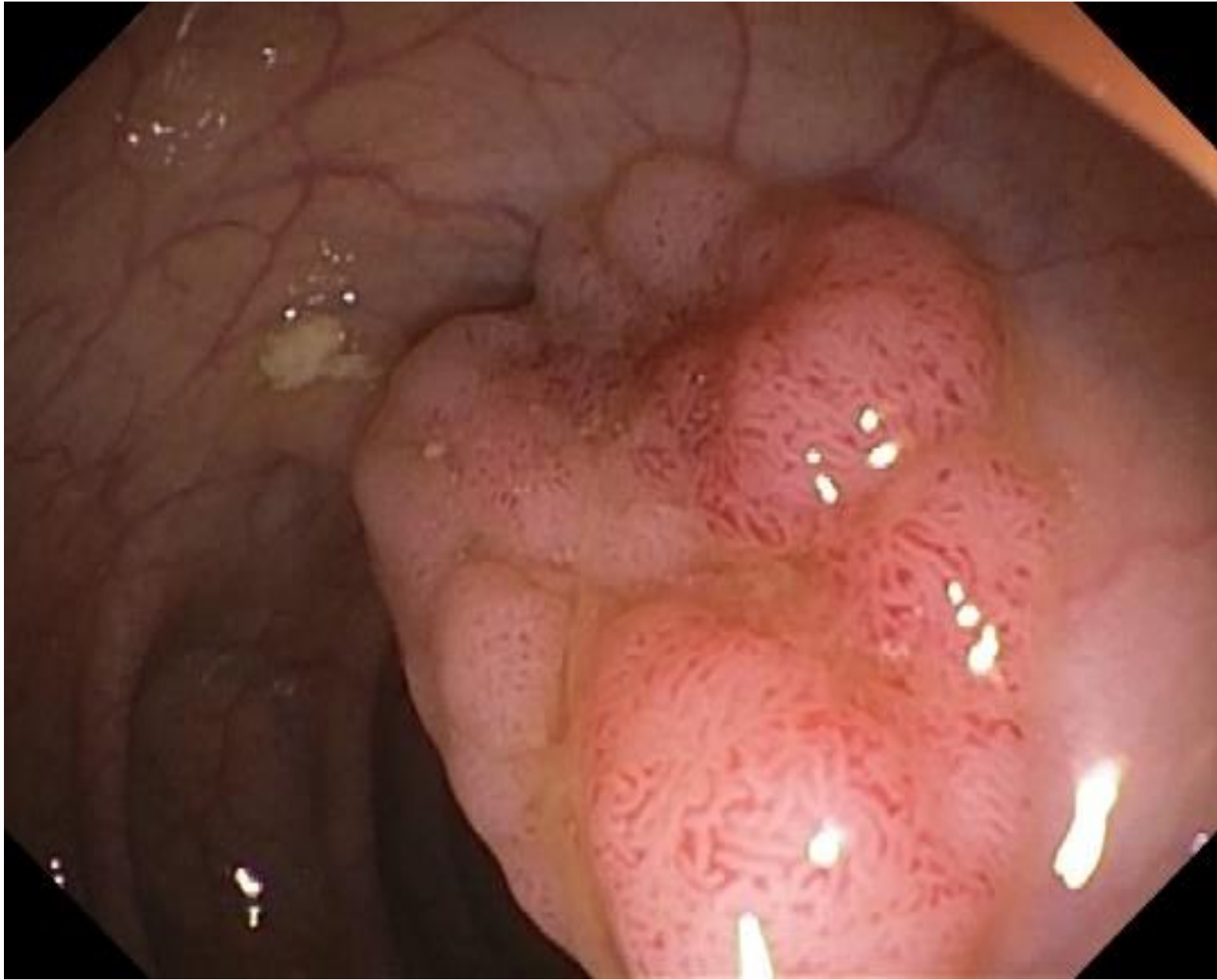


W Otero/23



W Otero/23





W Otero/23

11/08/2022
02:54:23PM
001:31

*1/100
AUTO

FR: F+T
MM: FICE
RC:

3.8 12.0
12.0

EC-600WL
3C688K197

CNC

*
HT NR
SE

GASTRO-COLONO

F 51 13/03/1971

Dr. Navarro
PABLO NAVARRO

BL-7000

12

**Dr Pablo Navarro
Costa Rica**

11/08/2022
02:57:03PM
004:10

*1/100
AUTO

FR: F+T
MM: FICE
RC:
3.8 12.0
12.0
EC-600WL
3C688K197
CNC

*
HT NR
SE
f

GASTRO-COLONO

F 51 13/03/1971

Dr. Navarro
PABLO NAVARRO

BL-7000

16

**Dr Pablo Navarro
Costa Rica**

11/08/2022
03:02:16PM
009:23

*1/100 ⊗
AUTO ⊙

FR: F+T
MM: FICE
RC:
3.8 12.0
12.0
EC-600WL
3C688K197

* ⊞
HT NR
SE ↗
↘

GASTRO-COLONO

**Dr Pablo Navarro
Costa Rica**

Provide clear and detailed post-procedure documentation

NOMBRE: OLGA LUCIA ARDILA OSPINA
EDAD: 49 AÑOS
IDENTIFICACIÓN: 52049147
TELÉFONO: 3133025443
OCUPACIÓN: PSICOLOGA
EMPRESA: SERVISALUD
REMISIÓN: CONSULTA EXTERNA
FECHA: 2 febrero 2022
PROCEDIMIENTO: POLIPECTOMÍA
INDICACIÓN: PÓLIPO DE COLON ASCENDENTE
ESPECIALIDAD: MD GASTROENTEROLOGO
LOCALIDAD: ENGATIVA
CORREO ELECTRONICO: OLARDILAS@GMAIL.COM
CALIDAD DE LA PREPARACION: BOSTON 3/9 (1-1-1)
PUNTAJE DE BURBUJAS: 1-1-1
TIEMPO DE LLEGADA AL CIEGO: 2 MINUTOS
TIEMPO DE RETIRADA: 9 MINUTOS

Previo al examen se realizó encuesta epidemiológica y al ingreso del consultorio sobre síntomas de COVID-19. Se realiza lavado de manos según recomendaciones de la OMS, y se hace uso de los EPP).
Previo consentimiento informado con la respectiva información de cuestionario Covid-19 y siguiendo las recomendaciones de seguridad para mitigar el contagio de Covid 19, se realizó el examen bajo sedación administrada por la Dra. Maryori Herrera, anesthesiologa

Hallazgos:

INSPECCIÓN: normal.
TACTO RECTAL: normal.
ANO RECTO: hemorroides internas grado I
SIGMOIDES: NORMAL
COLON DESCENDENTE: NORMAL
COLON TRANSVERSO: materia fecal, áreas examinadas normales
COLON ASCENDENTE: CINCO cm antes de la válvula ileocecal, del mismo lado de la misma, se encontró pólipo sésil de aproximadamente 20-25 mm, de apariencia vellosa. El pólipo está dentro de un divertículo. Por la complejidad de este pólipo, se decide remitirla a un hospital de tercer nivel para su resección. No se le tomaron biopsias para evitar que se llegara a producir fibrosis que impidiera su elevación al momento de mucosectomía. En la institución de tercer nivel se decidiría la forma de la resección (endoscópica o quirúrgica)..

DIAGNOSTICO.

- HEMORROIDES INTERNAS GRADO I
- POLIPO EN COLON ASCENDENTE EN ESTUDIO

SE REMITE A UN HOSPITAL DE TERCER NIVEL PARA LA MUCOSECTOMIA DEL PÓLIPO ENCONTRADO

Solicitar cita después de la resección

Recomendaciones:

Estas son las recomendaciones que usted debe tener en cuenta las próximas 24 horas después de haberse realizadas un examen de COLONOSCOPIA TOTAL.

- Después de 30 minutos del procedimiento debe iniciar dieta normal.
- Si presenta dolor abdominal intenso, vómito o deposiciones negras o sangrado rectal abundante, debe dirigirse al servicio de urgencias de su centro de salud más cercano y en lo posible llevar el resultado endoscópico. Además, Llamar al servicio de gastroenterología para informar teléfono: 3505210870.

Recomendación post venopunción:

- Inmediatamente después del retiro del catéter debe hacerse presión constante por 5 minutos.
- Si después de 5 minutos presenta sangrado en el sitio de la venopunción debe continuar con presión constante y elevar la extremidad (brazo).
- Si después de 5 horas presenta dolor, inflamación y enrojecimiento en el sitio de la venopunción, debe ponerse un paño limpio y humedecido en agua tibia, sobre la zona afectada.

Recomendación pos-sedación.

El día de hoy no puede conducir y no debe realizar trabajos que requieran concentración. No tomar licor. No consumir sedantes

Control: llevar los resultados de su examen a su médico tratante.

Quality Endo Unit

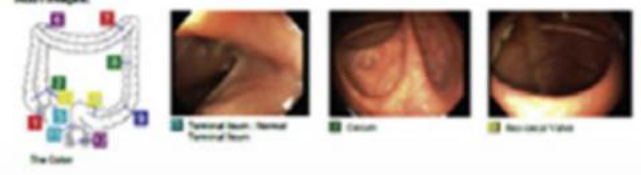
Patient Name: Your Patient	Procedure Date: 11/20/20 2:00 PM
MRN: 123456789	Date of Birth: 1/1/1965
Admit Type: Outpatient	Age: 55
Room: Q 1	Gender: Male
Room Status: Finalized	Instrument Name: HC Colonoscope #1

Procedure: Colonoscopy
Indications: High risk colon cancer surveillance; Personal history of non-advanced adenoma, Last colonoscopy: December 2014
Providers: ENDOSCOPIST MD, Endonurse, RN, Endoscopy RT
Patient Profile: Refer to note in patient chart for documentation of history and physical
Referring MD: Primary Care Doctor, MD
Medicines: Propofol per Anesthesia
Complications: No immediate complications.

Requesting Provider:
Procedure: Pre-anesthesia Assessment
- Prior to the procedure, a history and Physical was performed, and patient medications and allergies were reviewed. The patient's tolerance of previous anesthesia was also reviewed. The risks and benefits of the procedure and the sedation options and risks were discussed with the patient. All questions were answered, and informed consent was obtained. Prior Anticoagulants: The patient has taken no previous anticoagulant or antiplatelet agents. ASA Grade Assessment: II - A patient with mild systemic disease. After reviewing the risks and benefits, the patient was deemed in satisfactory condition to undergo the procedure.
- Patient identification and proposed procedure were verified prior to the procedure by the physician, the nurse and the anesthesiologist. The procedure was verified in the procedure room.
After I obtained informed consent, the scope was passed under direct vision. Throughout the procedure, the patient's blood pressure, pulse, and oxygen saturations were monitored continuously. The Colonoscope was introduced through the anus and advanced to the terminal ileum, with identification of the appendiceal orifice and IC valve. The terminal ileum, ileocecal junction, appendiceal orifice, and rectum were photographed. The quality of the bowel preparation was excellent. The colonoscopy was performed without difficulty. The patient tolerated the procedure well.

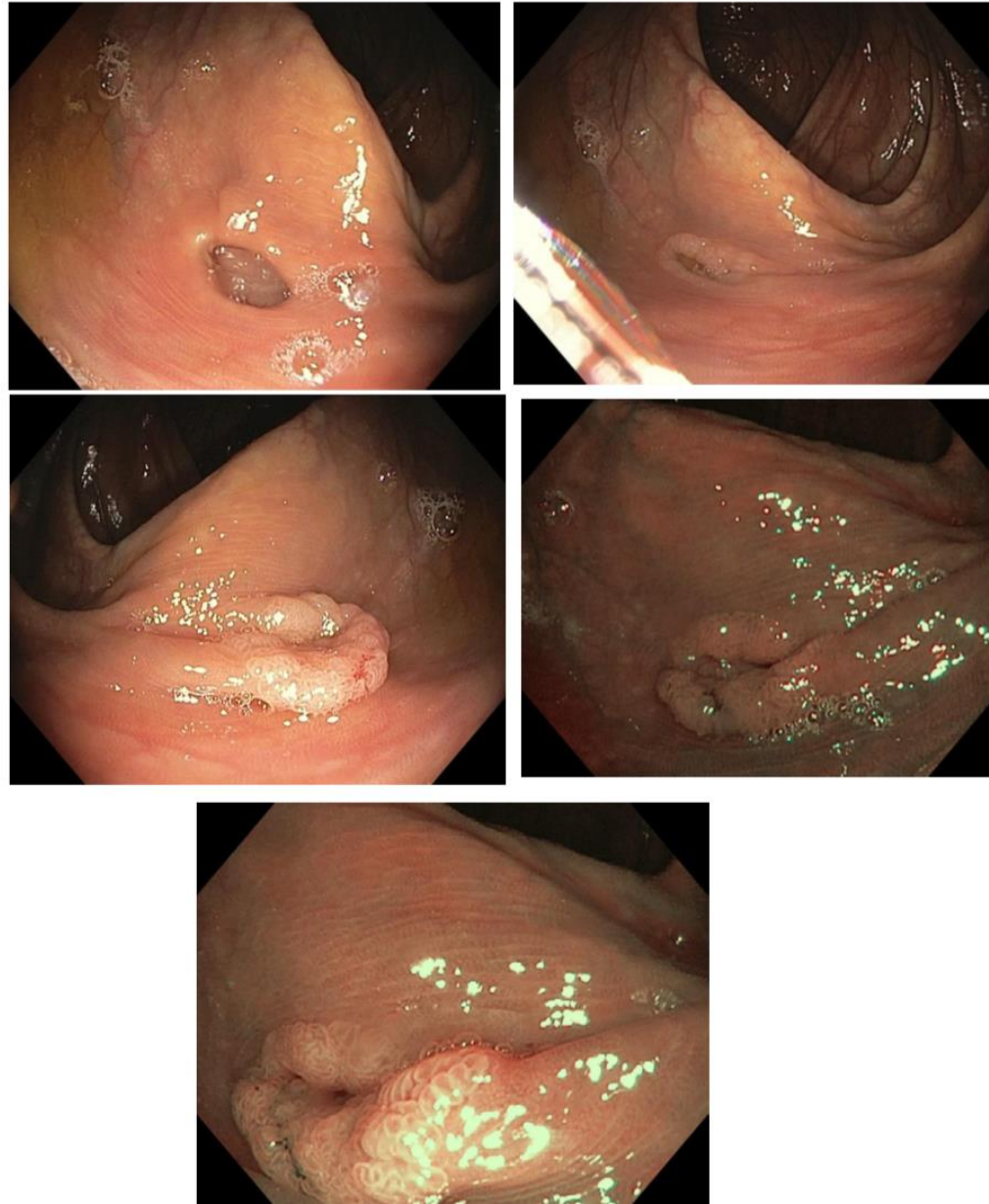
Findings:
- The perianal and digital rectal examinations were normal.
- The terminal ileum appeared normal.
- Normal mucosa was found in the entire colon.
- Internal hemorrhoids were found during retroflexion. The hemorrhoids were small.

Adult Images:

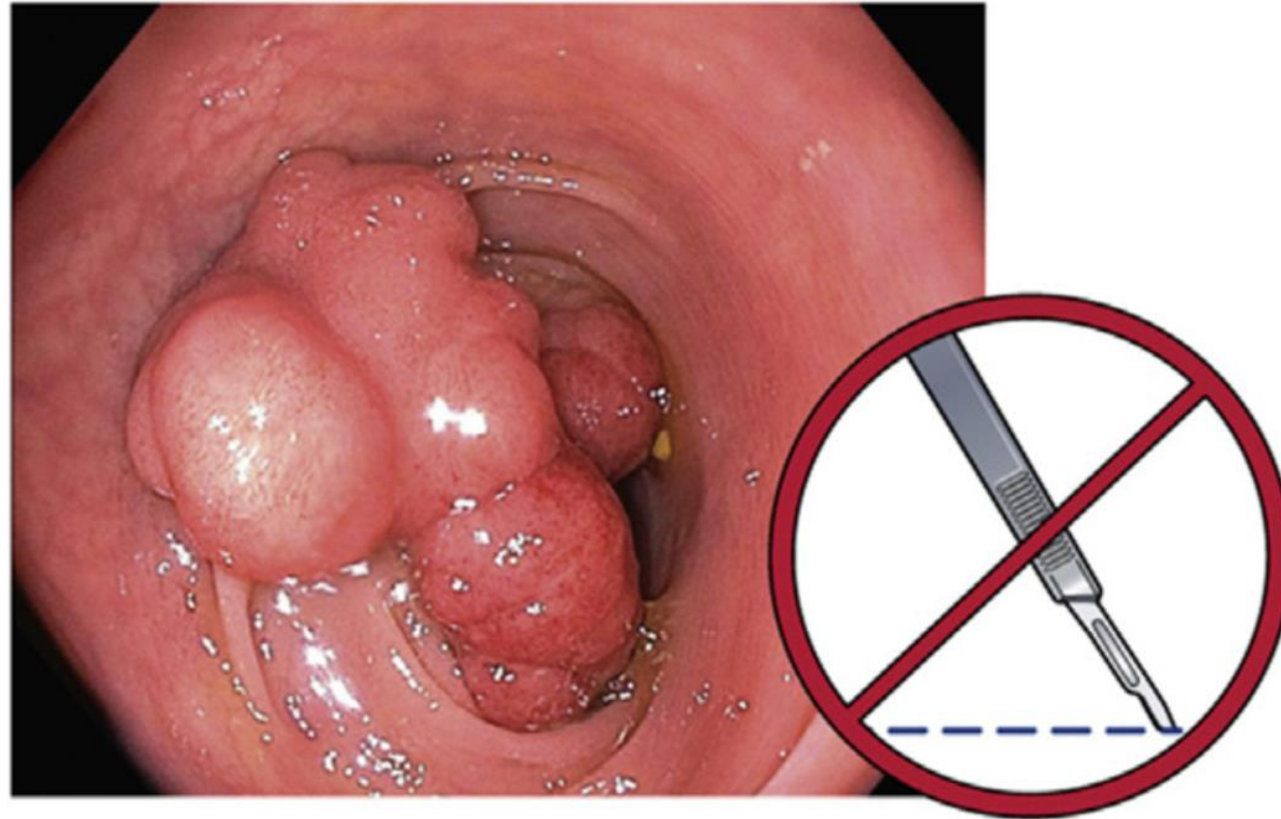


The Colon

Terminal Ileum - Normal
Cecum
Mucosal Folds



Refer patients with benign complex polyps for endoscopic resection not surgery



Follow guidelines when assigning screening or surveillance intervals

Normal colonoscopy	—————→	10 years
Small HP only	—————→	10 years
1–2 small adenomas	—————→	7–10 years
1–2 small SSLs	—————→	5–10 years
3–4 small adenomas/SSLs	—————→	3–5 years
5–10 small adenomas/SSLs	—————→	3 years
Advanced adenoma	—————→	3 years
Advanced SSL or TSA	—————→	3 years

Otros indicadores de calidad

Tacto rectal: **Siempre**

Tatuaje: pólipos **>20 mm (No recto o ciego)**

Diarrea crónica: **Biopsias de mucosa normal (Colon, ileon)**

Estudio histológico de pólipos: **90%**

Vigilancia en EI

Perforación: **0.07%**

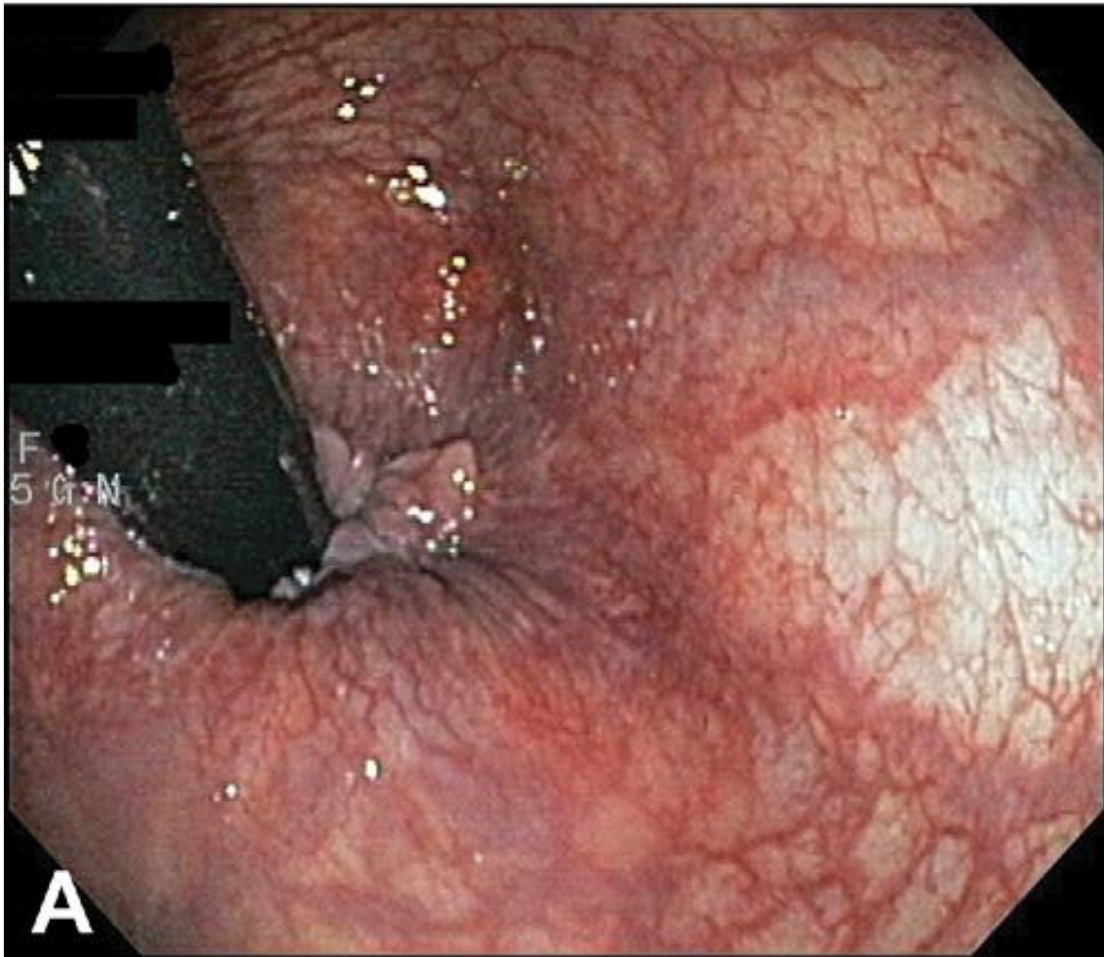
Indicador de calidad

Retrovisión del recto ?

Ruiz-Rebollo ML, GIE 2015;82:421-2
Rex DK, GIE 2015;82:22-3

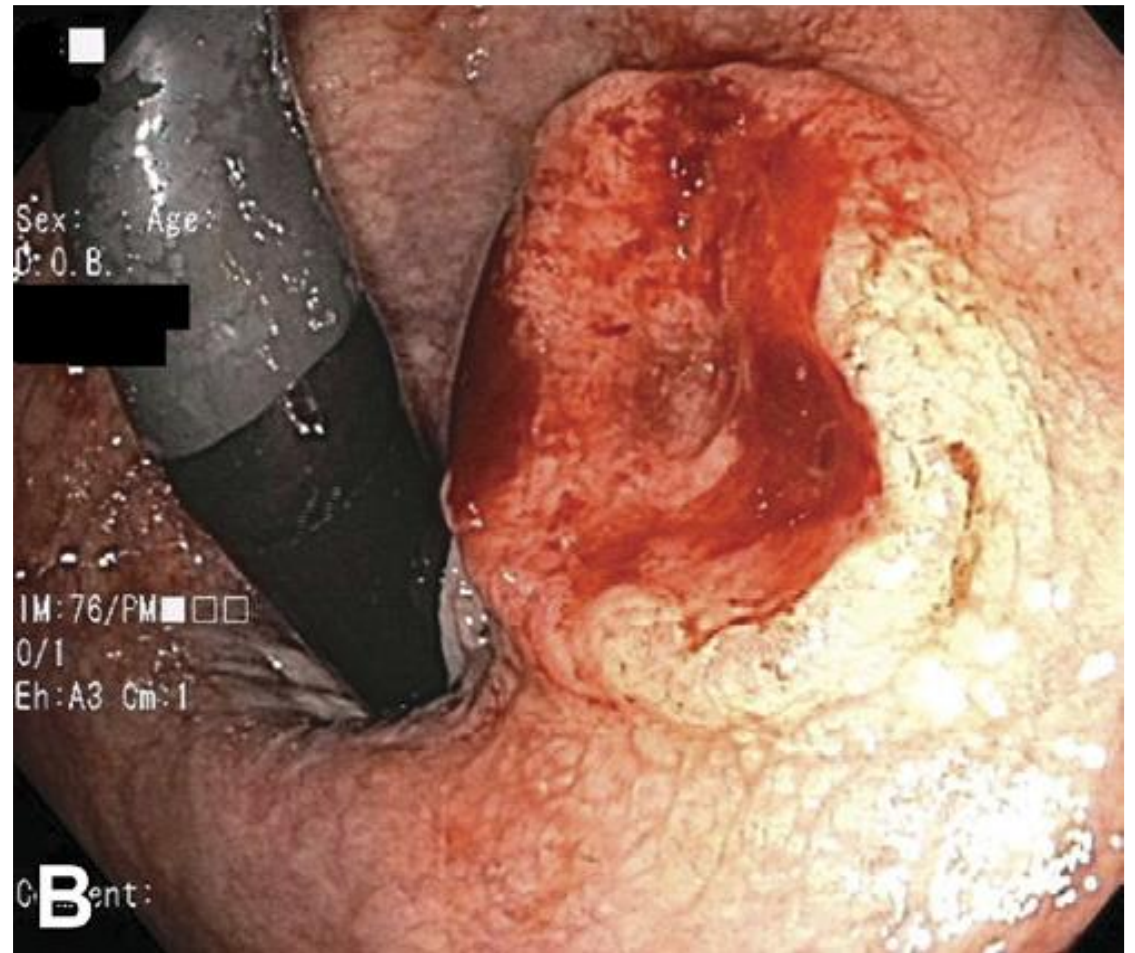Routine rectal retroflexion during colonoscopy has a low yield for neoplasia

1502 pacientes, Retrovisión exitosa **93.9%** (1411)
43 pólipos en recto distal
33 Se vieron con la inserción y la retroflexión
7 solo con retroflexión
6 hiperplásicos sésiles, 1 adenomatoso 4 mm
Ángulo de visión de **140°** y **170°** similares



Enero 2006

5 años después



Enero 2011

Rectal perforation during colonoscopic retroflexion: a large, prospective experience in an academic center

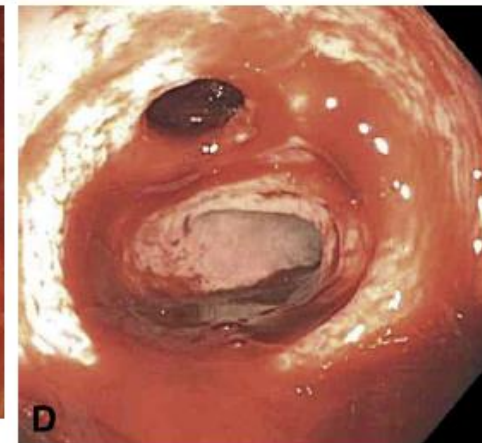
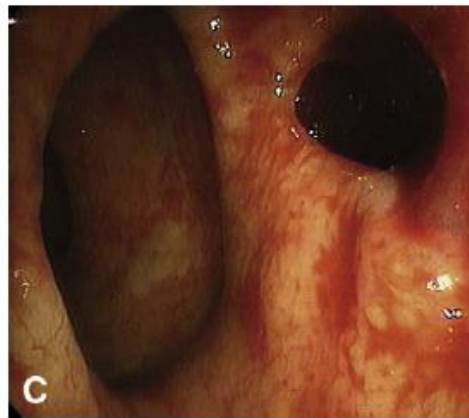
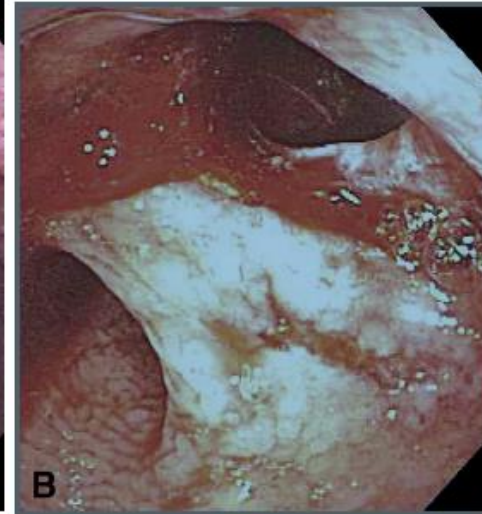
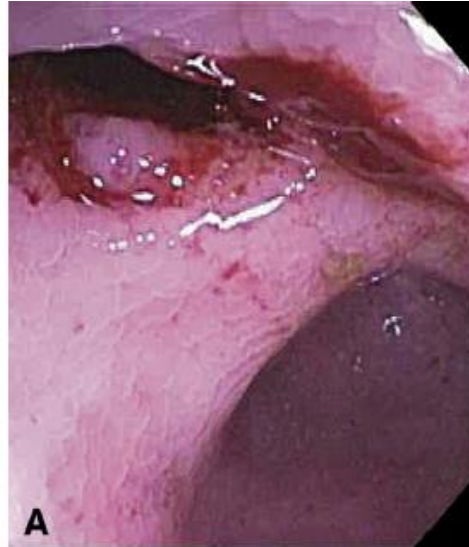Matthew R. Quallick, MD, William R. Brown, MD

Denver, Colorado, USA

39.054 Colonoscopies



**4 casos
0.10/1000**



GIE 2009;69: 960-3

Otros indicadores

Tasa de cáncer colo-rectal pos colonoscopia (PCCRC)

Tasa de pérdida de adenomas (AMR)

Adenomas pos-colonoscopia

Tasa de detección de adenomas


Tasa de detección de pólipos (PDR)

Tasa de pérdida de adenomas avanzados (AAMR)

>10mm, displasia de alto grado y/o componente vellosa

Mensajes para la casa

**La protección contra CCR depende colonoscopista.
Indicadores calidad impactan incidencia mortalidad CCR
Colonoscopistas deben cumplir con indicadores
Retroalimentación y auditoria mejoran desempeño
Medir indicadores periódicamente (c/250 exámenes)**



Peter Drucker

“Si no lo puedes medir, no lo puedes mejorar”



Colonoscopia

No es un examen de rutina

No es un trabajo

Es una pasión!

Yo

Muchas gracias!



Muchas gracias!