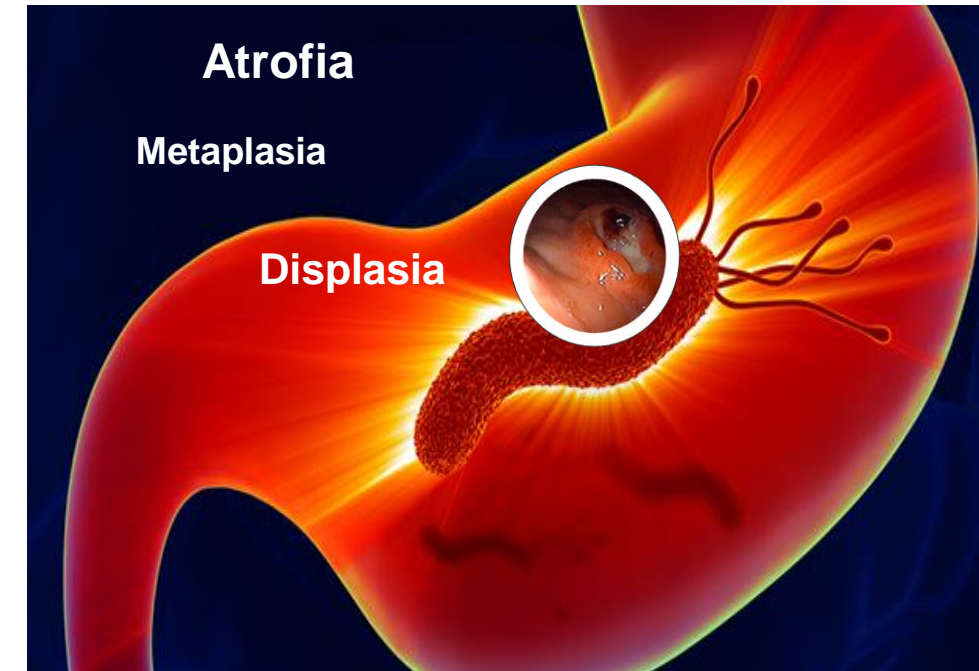


Quito, octubre 27, 2023



Monitoreo de los precursores de cáncer gástrico

“No *Hpylori* No cáncer”

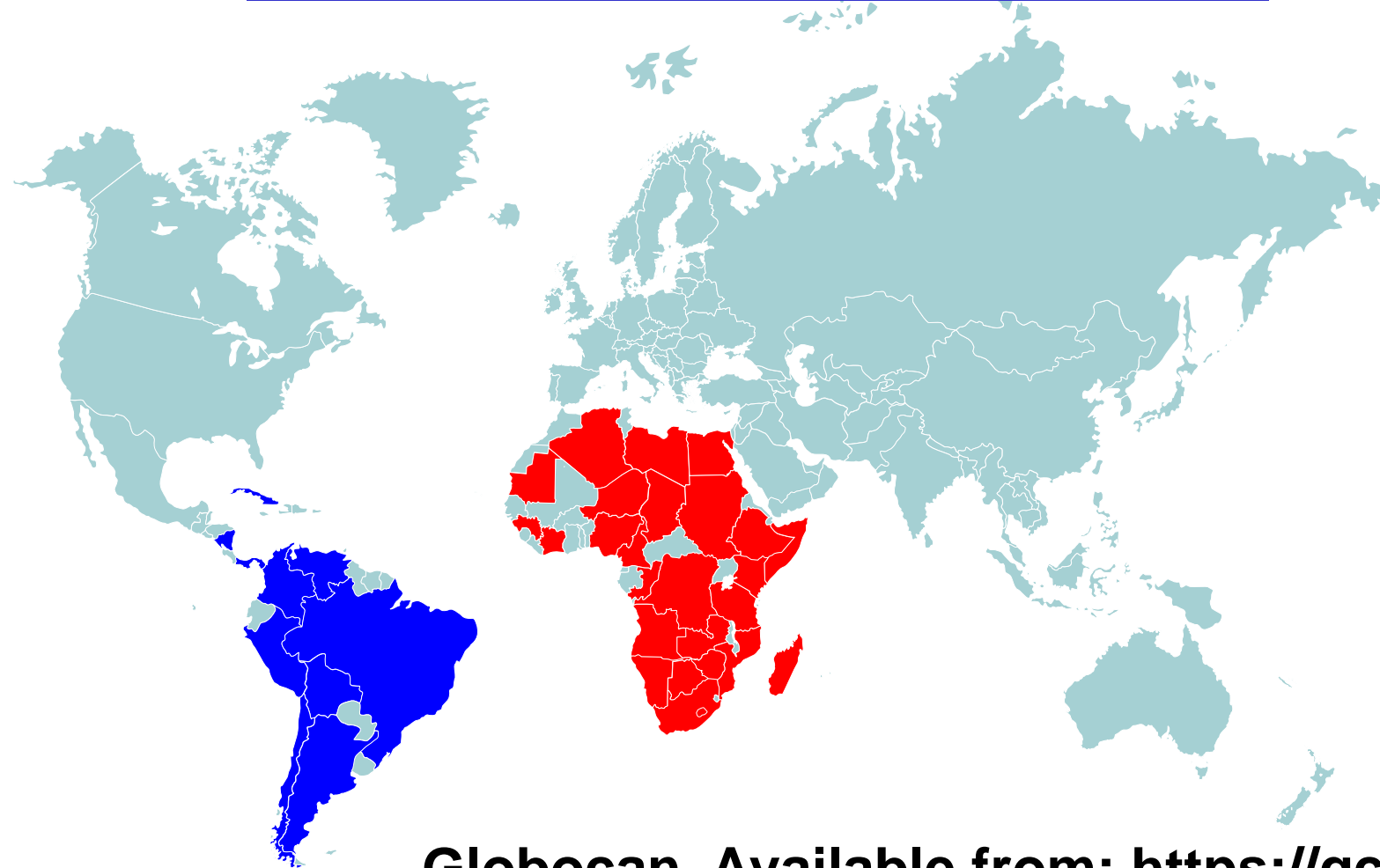

William Otero MD, FAGA, FASGE, FACP
Profesor Titular de Medicina
Unidad de Gastroenterología
Universidad Nacional de Colombia
Hospital Universitario Nacional de Colombia

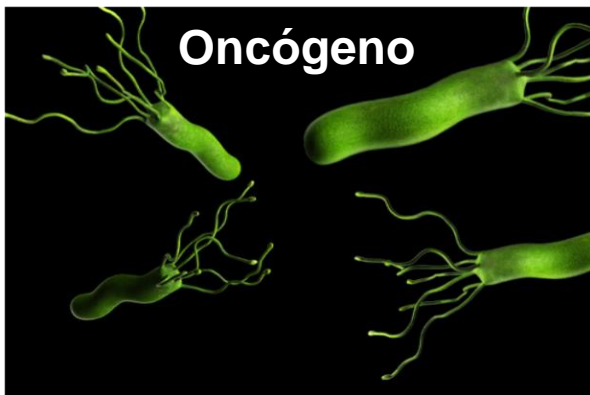


Cáncer Gástrico

**5^o cáncer más común
3^a causa muerte por cáncer
Llegan avanzados**



Globocan. Available from: <https://gco.iarc.fr/>. 2018



H.pylori
OMS IARC1994/2009
Carcinógeno tipo I

40-50% mundo
Tiene *H.pylori*

1.220.000 casos
2017
800.000 muertes

1-3%

Riesgo atribuible
Global 85-90%
Japón Korea 90-95%

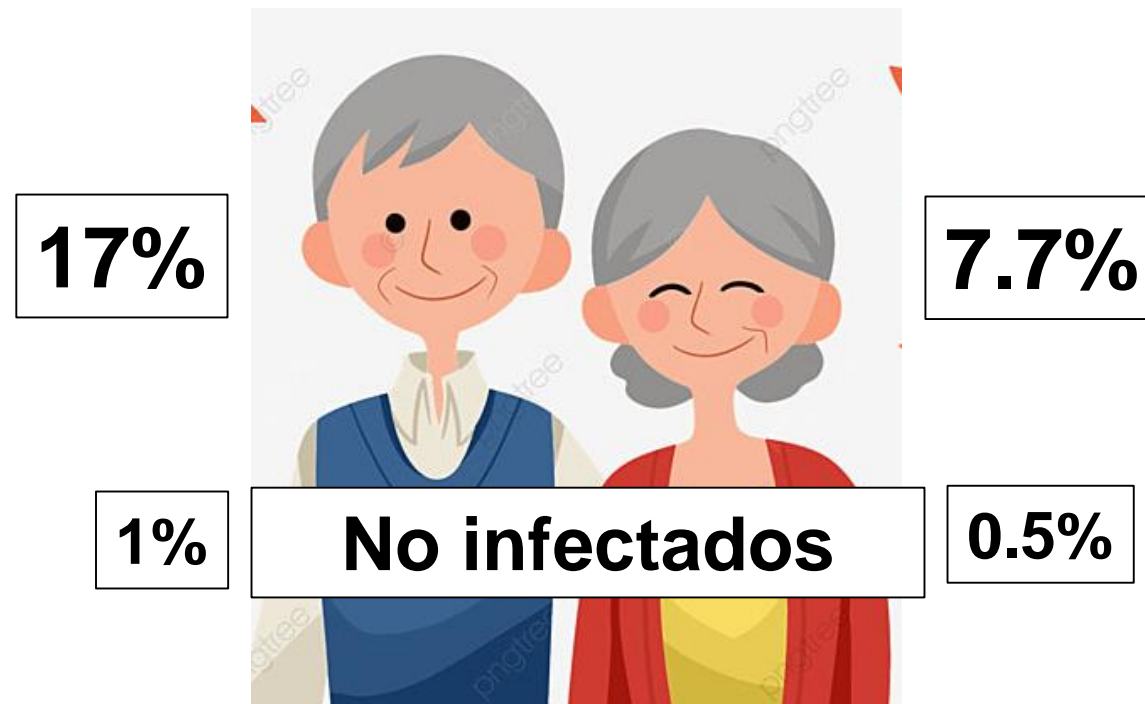Graham DY, Gastroenterology 2015;148:719-31
Tsuda M, Helicobacter 2017;e12415

Lancet Gastroenterol Hepatol 2020;5:42-54
Global Burden Disease. JAMA Oncol 2017;3:524-41

Lifetime incidence risk for gastric cancer in the *Helicobacter pylori*-infected and uninfected population in Japan: A Monte Carlo simulation study

Sayo Kawai¹ | Chaochen Wang¹ | Yingsong Lin¹ | Tae Sasakabe¹ |
Masumi Okuda² | Shogo Kikuchi¹

Incidencia de cáncer gástrico a los 85 años Infeccionados por *H.pylori*



Descubrimiento del agente causal de la mayoría de las gastritis

1982

THE LANCET

[Volume 321, Issue 8336](#), 4 June 1983, Pages 1273-1275

[doi:10.1016/S0140-6736\(83\)92719-8](https://doi.org/10.1016/S0140-6736(83)92719-8)  Cite or Link Using DOI

Copyright © 1983 Published by Elsevier Science Ltd.

Letters to the Editor


**Gastritis crónica
Una enfermedad infecciosa**

^a Department of Pathology, Royal Perth Hospital, Perth, Western Australia 6001, United Kingdom


^b Department of Gastroenterology, Royal Perth Hospital, Perth, Western Australia 6001, United Kingdom

Available online 22 September 2003.

Sugano K, Gut 2015;64:1353-67



Malfertheiner P, et al. Gut 2022;71:1724-62



“La gastritis crónica por *H.pylori* es una enfermedad infecciosa”



ICD 11th (International Classification of Disease)

Cáncer Gástrico modelo Pelayo Correa

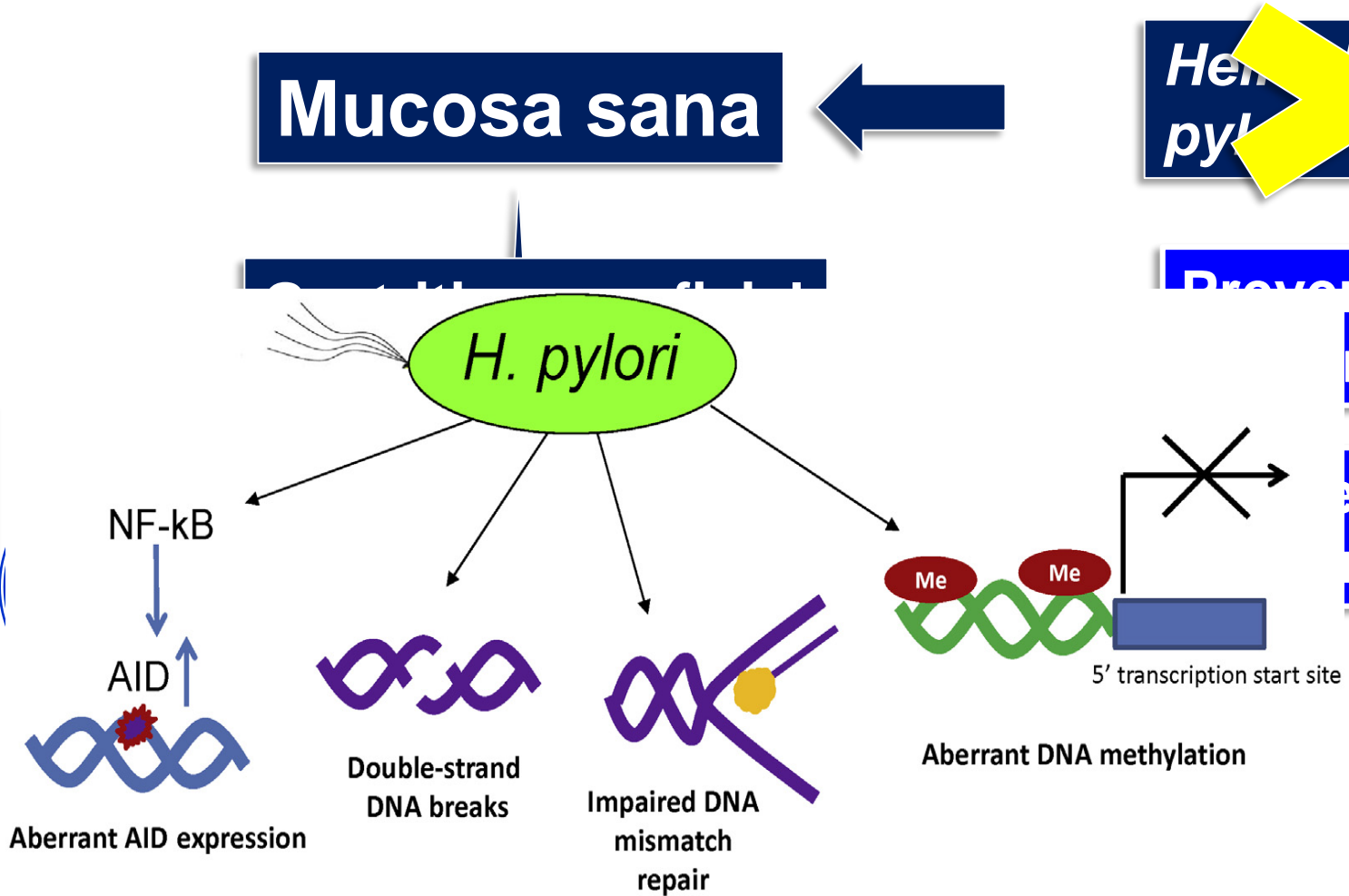


Mucosa sana

~~Helicobacter pylori~~

Prevencción
ria

esis
robada



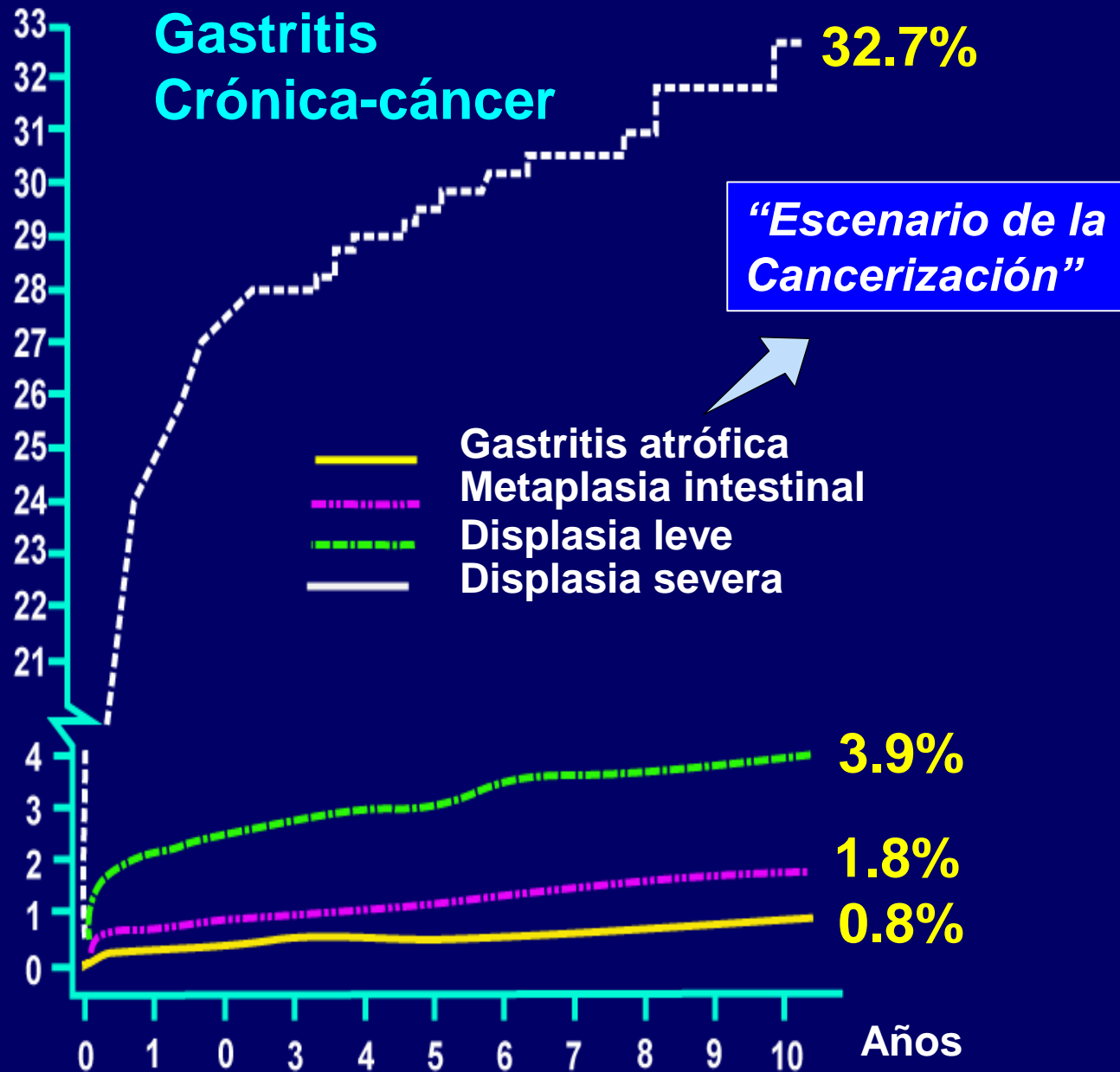
Estratificando
severidad

Vigilancia
Prevencción
Secundaria


Cáncer gástrico

Correa P. Cancer Res 1992; 52:6735–6740
 Correa P. J Dig Dis 2012;13:2-9
 Chen HN, Gastric Cancer 2016;19:166-7

Holanda
Seguimiento
10 años

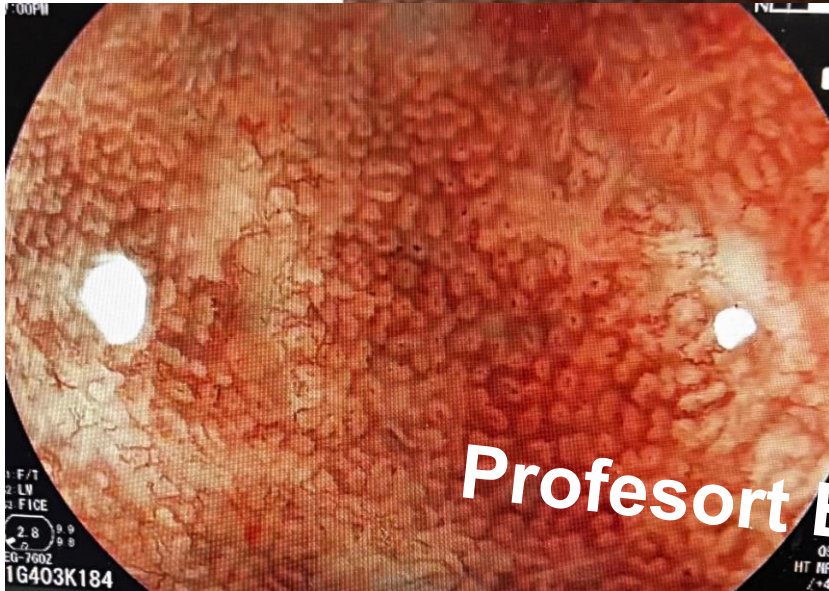

Prevención secundaria



**Identificar y vigilar
Condiciones precursoras de CG
Atrofia –Metaplasia-Displasia**

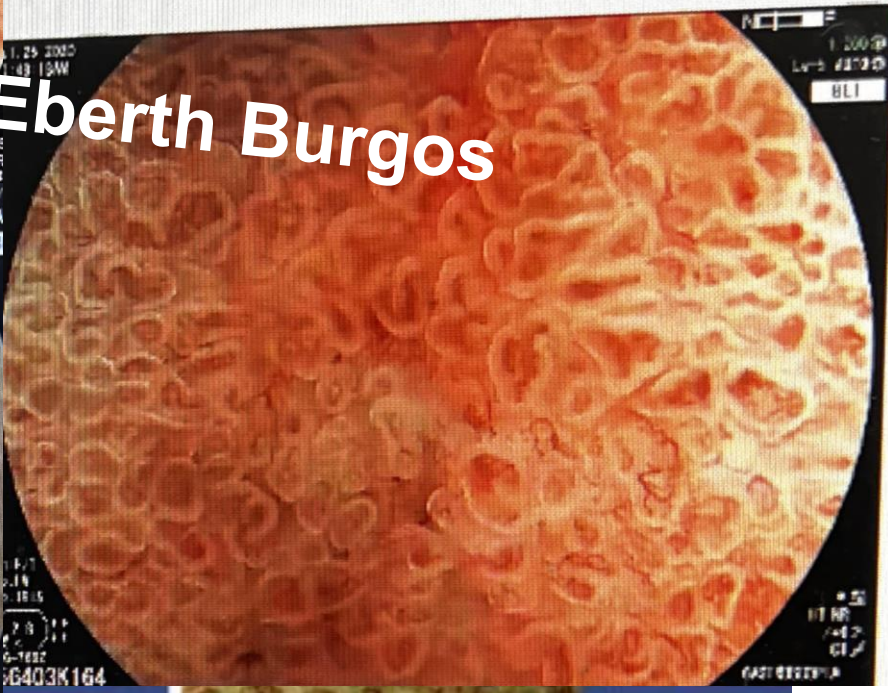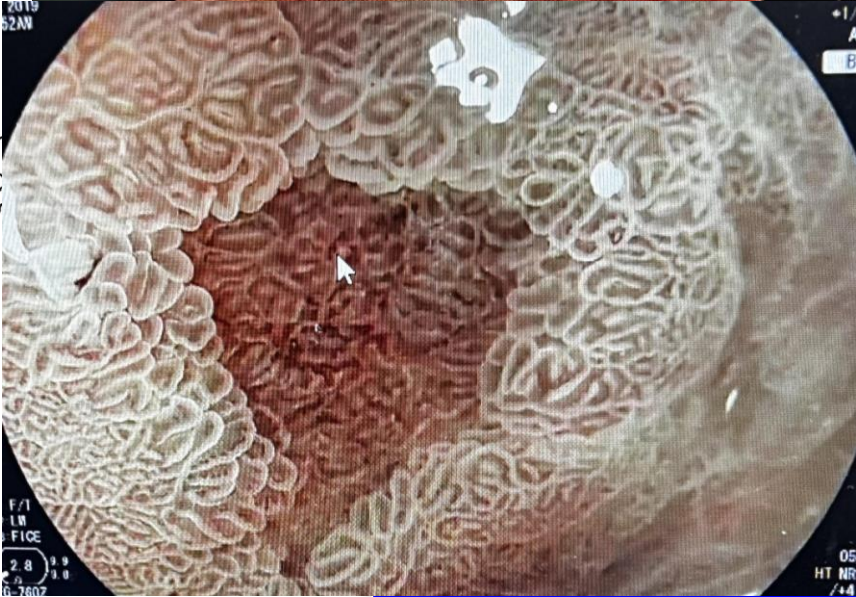
Endoscopios avanzados



TECNOLOGIA DIAGNÓSTICA

Profesort Eberth Burgos

Gastritis Crónica leve”



Gastritis Crónica severa con erosión y metaplasia intestinal”


“Gastritis Crónica moderada”

Type 2

Type 3

An explainable artificial intelligence system for diagnosing *Helicobacter Pylori* infection under endoscopy: a case-control study

Mengjiao Zhang*, Jie Pan*, Jiejun Lin, Ming Xu, Lihui Zhang, Renduo Shang, Liwen Yao, Yanxia Li, Wei Zhou, Yunchao Deng, Zehua Dong, Yijie Zhu, Xiao Tao, Lianlian Wu and Honggang Yu 

OPEN  Check for updates












Application of artificial intelligence in endoscopic image analysis for the diagnosis of a gastric cancer pathogen-*Helicobacter pylori* infection

Chih-Hsueh Lin^{1,2,11}, Ping-I Hsu^{3,11}, Chin-Dar Tseng^{1,2}✉, Pei-Ju Chao^{1,2}, I-Ting Wu³, Supratip Ghose⁴, Chih-An Shih^{5,6}, Shen-Hao Lee^{1,2,7}, Jia-Hong Ren^{1,2}, Chang-Bih Shie³ & Tsair-Fwu Lee^{1,10,2,8,9}✉

Exactitud 90%
Sensibilidad 100%
Especificidad 81%
VPP 82%
VPN 100%

Lin CH, et al. Sci Rep 2023;13:13380

Management of *Helicobacter pylori* infection: the Maastricht VI/Florence consensus report

Peter Malfertheiner ,^{1,2} Francis Megraud ,³ Theodore Rokkas ,^{4,5}
Javier P Gisbert ,^{6,7} Jyh-Ming Liou ,⁸ Christian Schulz ,^{1,9}
Antonio Gasbarrini,¹⁰ Richard H Hunt,^{11,12} Marcis Leja ,^{13,14} Colm O'Morain,¹⁵
Massimo Rugge ,^{16,17} Sebastian Suerbaum,^{9,18} Herbert Tilg ,¹⁹
Kentaro Sugano ,²⁰ Emad M El-Omar ,²¹ On behalf of the European
Helicobacter and Microbiota Study group

Statement 3: When endoscopy is indicated it should: (1) apply the best available technologies; (2) include biopsy sampling. Biopsy samples, as obtained in accordance with validated protocols, should result in both aetiological diagnosis and gastritis staging. Any focal lesions should be additionally sampled.

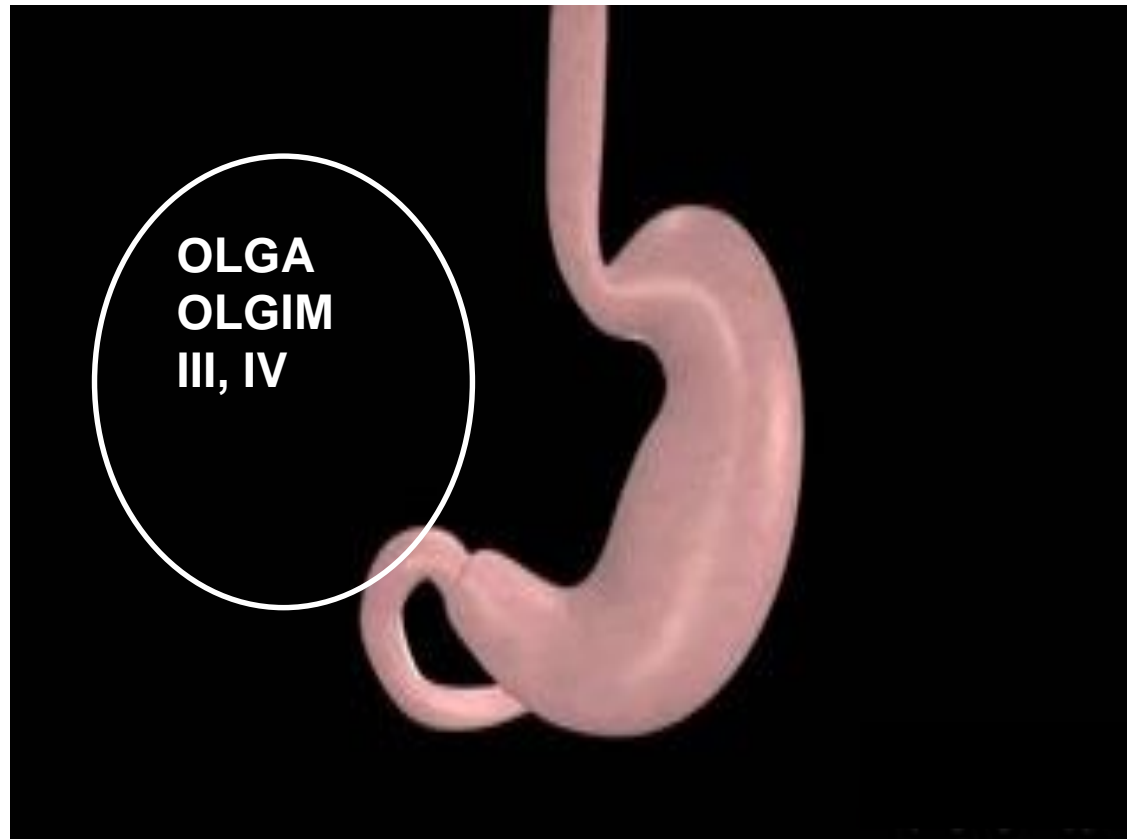
Agreement 100%

Grade A2

Malfertheiner P, et al. *Gut* 2022;71:1724–62

Estratificación de la atrofia o MI Biopsias

Identificar el “Estómago premaligno”



Sugano K, Gut 2015;64:1353-67

Take S, J Gastroenterol 2020;55:281-8

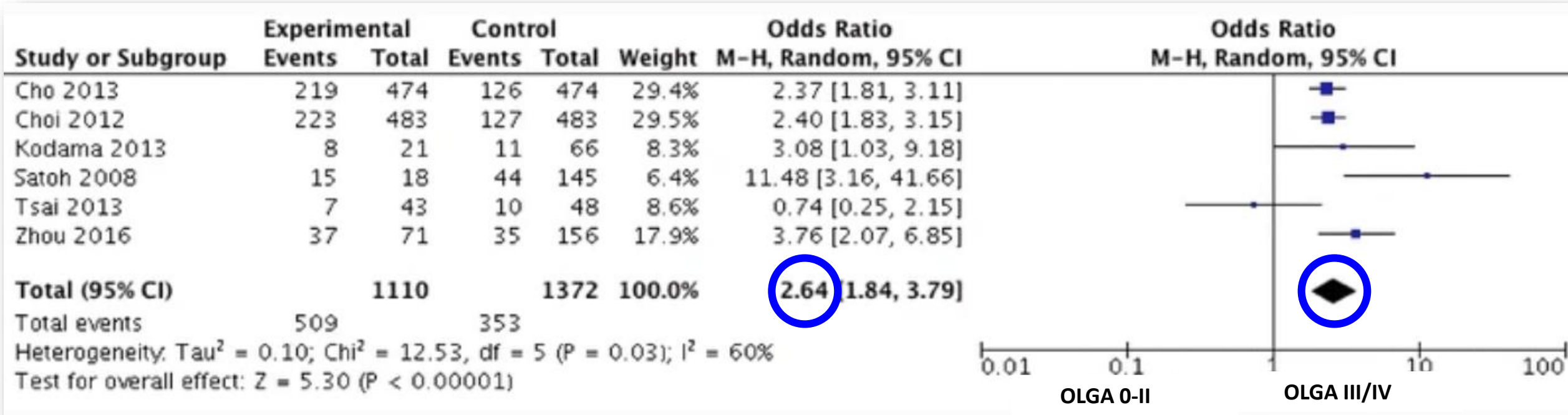
Malfertheiner P, Maastricht VI. Gut 2022 Online agosto 15

The significance of OLGA and OLGIM staging systems in the risk assessment of gastric cancer: a systematic review and meta-analysis



Hu Yue^{1,2} · Liu Shan¹ · Lv Bin^{1,2}

OLGA III/IV Casos y controles

Cáncer gástrico

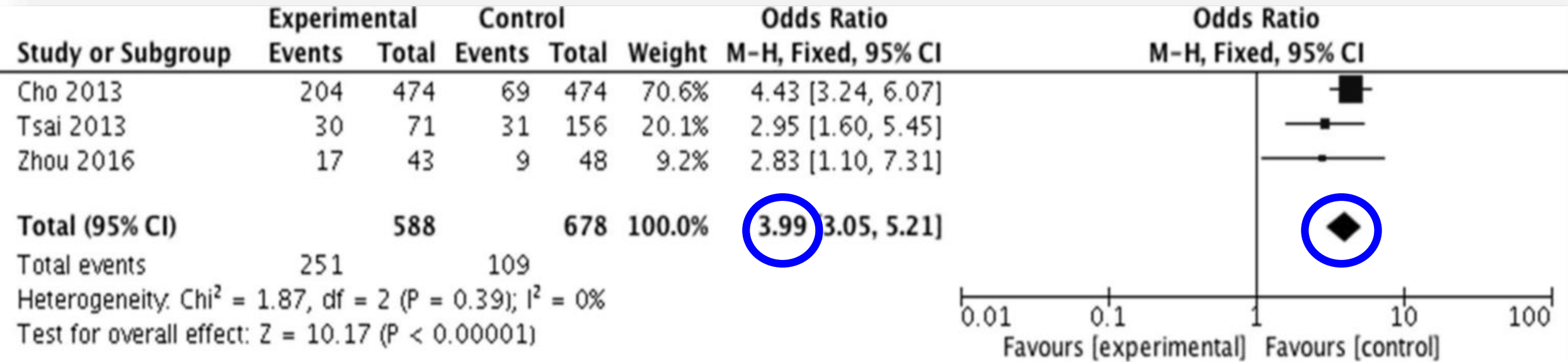


The significance of OLGA and OLGIM staging systems in the risk assessment of gastric cancer: a systematic review and meta-analysis

Hu Yue^{1,2}  · Liu Shan¹ · Lv Bin^{1,2} 

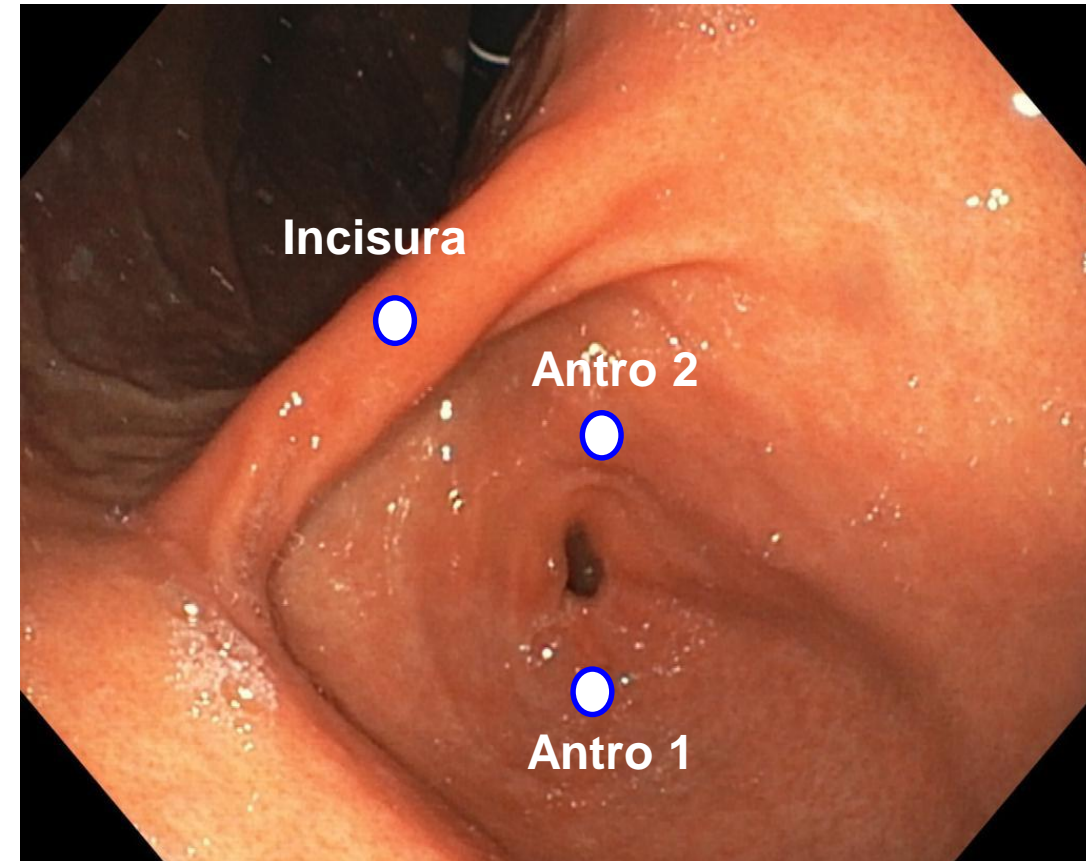
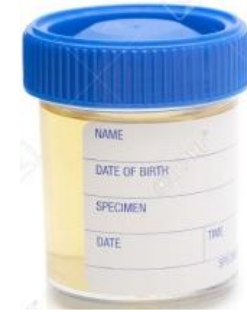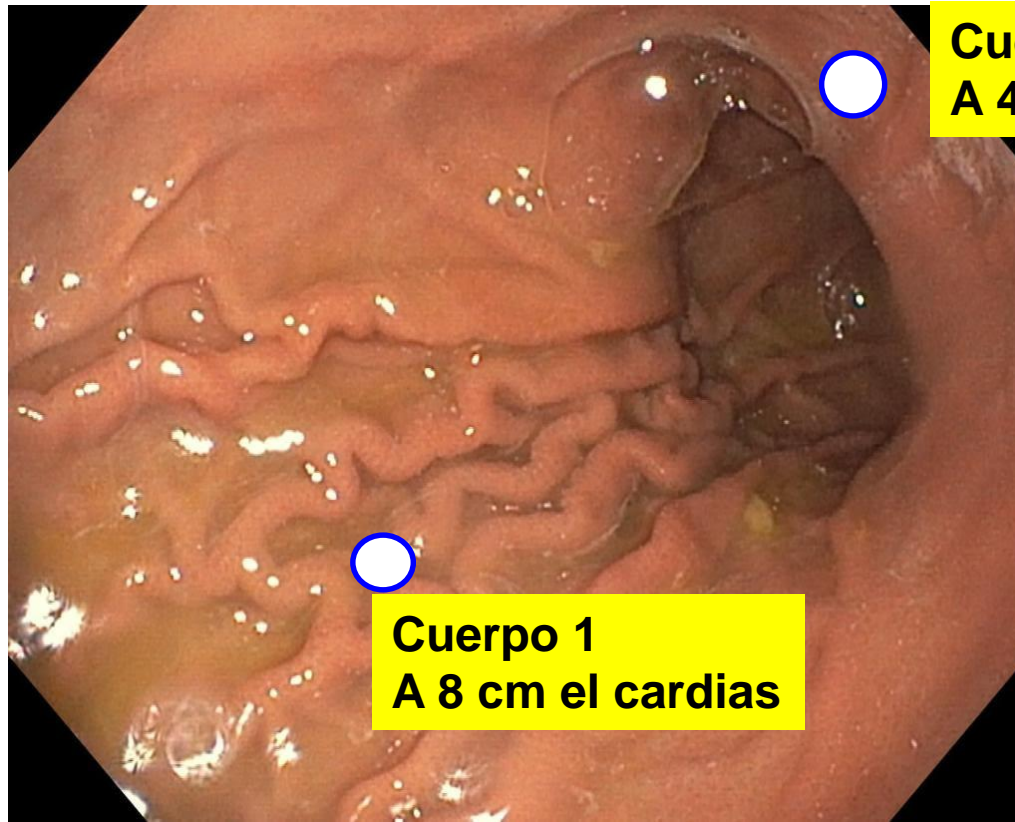
OLGIM III/IV, Casos y controles

Cáncer gástrico

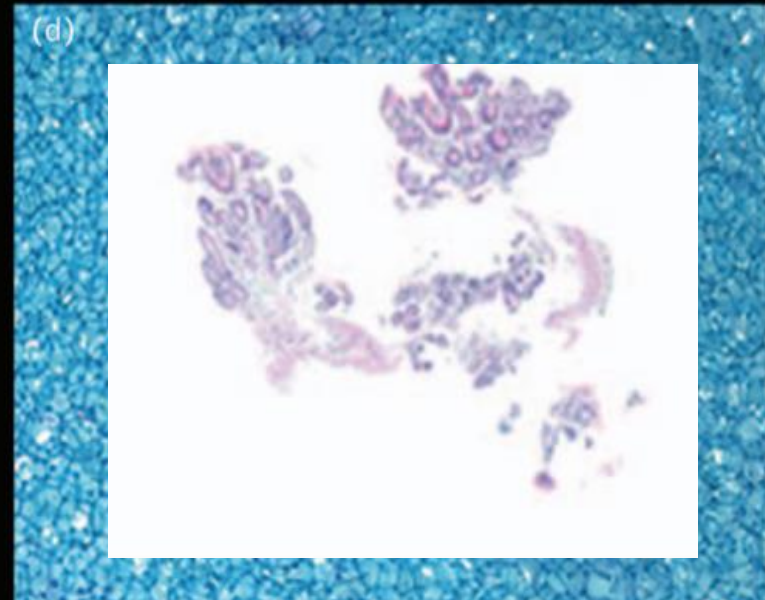
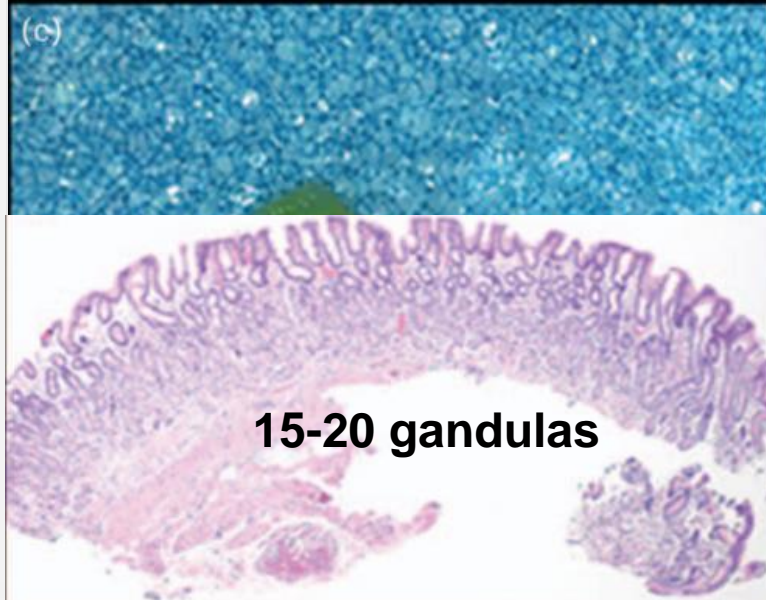
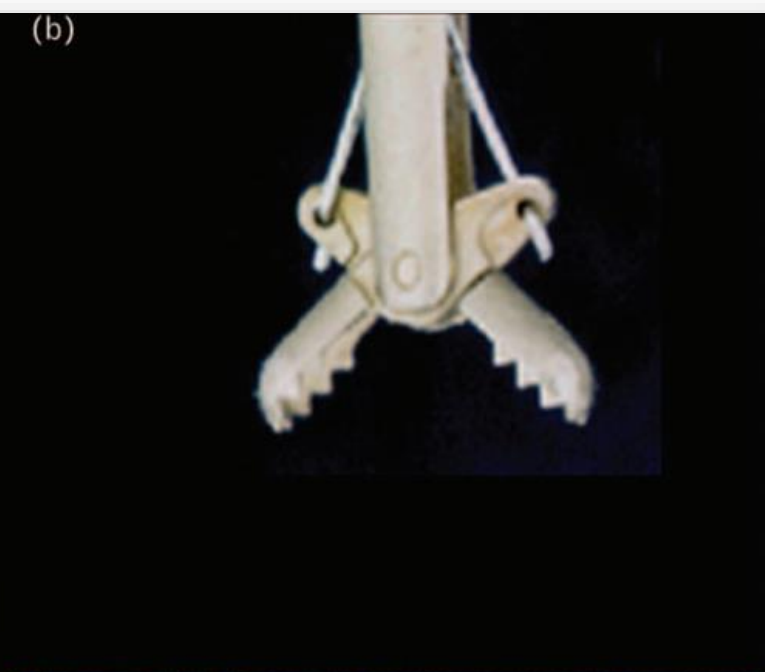


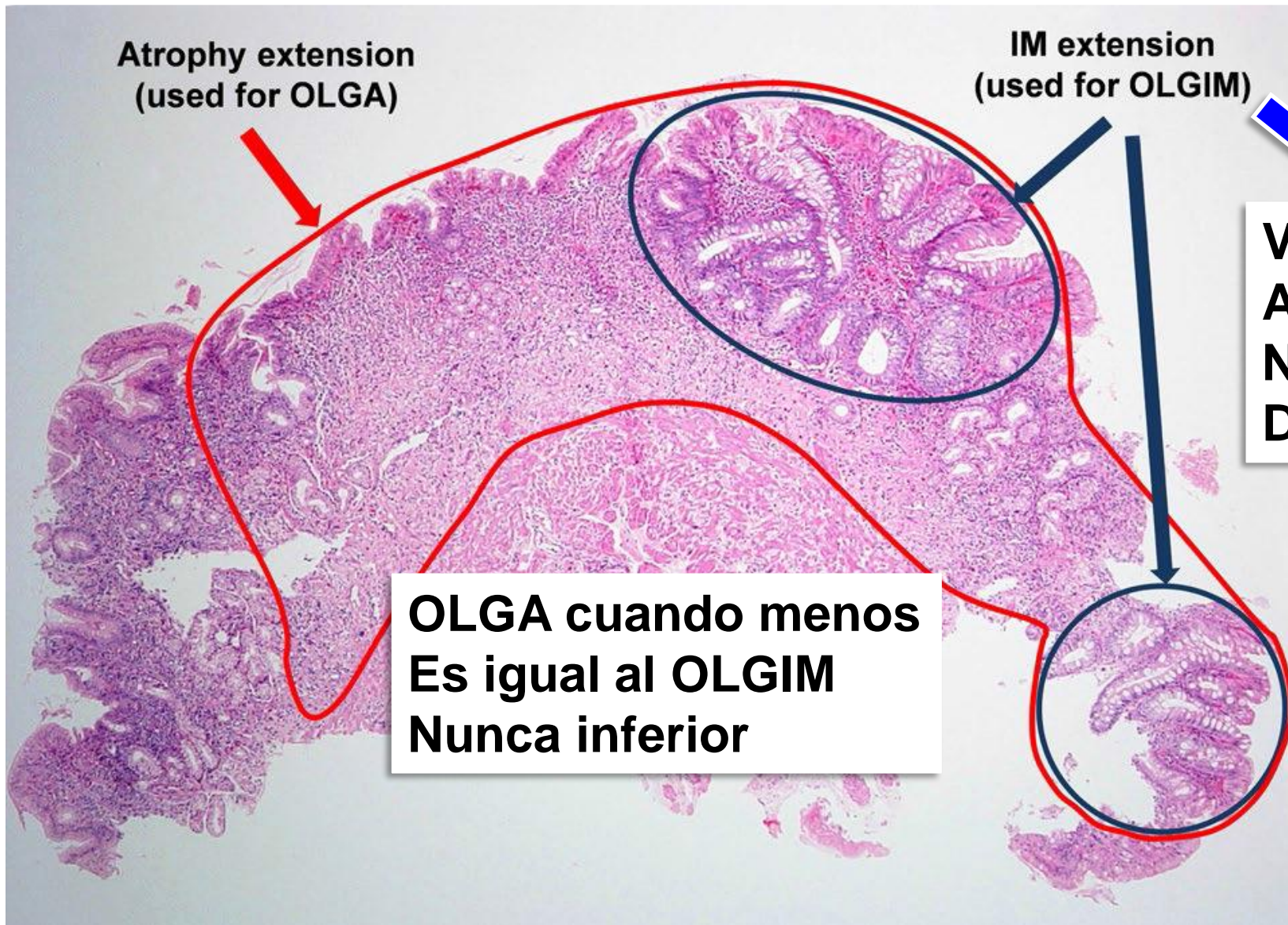
Yue H, et al. Gastric Cancer 2018;21: 579–87

Sídney



Kyoto 2015
Maastricht 2022





Atrophy extension
(used for OLGA)

IM extension
(used for OLGIM)

Variante de
Atrofia
No entidad
Diferente

**OLGA cuando menos
Es igual al OLGIM
Nunca inferior**

Matysiak-Budnik T, Dig Dis Sci 2020, abril 20
Rugge M, Gastrointest Endosc. 2011;73:411-2.

OLGA identifica todos Los tipos de atrofia

Malfertheiner P, Gut 2022 Online agosto 15

Management of epithelial precancerous conditions and lesions in the stomach (MAPS II): European Society of Gastrointestinal Endoscopy (ESGE)–European Society for Gastrointestinal Endoscopy (ESGE) Group (EHMSG)–Sociedade Portuguesa de Endoscopia Digestiva (SPEDE) update 2019



Authors
Pedro Pimentel-Nunes¹, Gianluca Esposito⁷, Monique Jansen⁴, Jean-Marc Dumonceau¹⁰, Ernst J. Kuipers¹⁶, Mario

OLGA
OLGIM

Guideline
65-88

Annibale⁷,
Hoofft¹⁵,

Guidelines

Chronic atrophic gastritis: Natural history, diagnosis and therapeutic management. A position paper by the Italian Society of Hospital Gastroenterologists and Digestive Endoscopists [AIGO], the Italian Society of Digestive Endoscopy [SIED], the Italian Society of Gastroenterology [SIGE], and the Italian Society of Internal Medicine [SIMI]

Edith Lahner^{a,*}, Rocco Maurizio Zagari^b, Angelo Zullo^c, Antonio Di Sabatino^d, Alberto Meggio^e, Paola Cesaro^f, Marco Vincenzo Lenti^d, Bruno Annibale^a, Gino Roberto Corazza^d

Lahner E, et al. Dig Liver Dis 2019;51:1621-32

British Society of Gastroenterology guidelines on the diagnosis and management of patients at risk of gastric adenocarcinoma

Matthew Banks,^{1,2} David Graham,^{1,3} Marnix Jansen,⁴ Takuji Gotoda,⁵ Sergio Coda,⁶ Massimiliano di Pietro,^{7,8} Noriya Uedo,⁹ Pradeep Bhandari,¹⁰ D Mark Pritchard,¹¹ Ernst J Kuipers,¹² Manuel Rodriguez-Justo,⁴ Marco R Novelli,⁴ Krish Ragunath,¹³ Neil Shepherd,¹⁴ Mario Dinis-Ribeiro¹⁵

Banks M, et al. Gut 2019;68:1545-75

Kyoto global consensus report on *Helicobacter pylori* gastritis

Sugano K, et al. Gut 2015;64:1353–1367

Kentaro Sugano,¹ Jan Tack,² Ernst J Kuipers,³ David Y Graham,⁴ Emad M El-Omar,⁵ Soichiro Miura,⁶ Ken Haruma,⁷ Masahiro Asaka,⁸ Naomi Uemura,⁹ Peter Malfertheiner,¹⁰ on behalf of faculty members of Kyoto Global Consensus

Management of *Helicobacter pylori* infection: the Maastricht VI/Florence consensus report

Peter Malfertheiner^{1,2}, Francis Megraud³, Theodore Rokkas^{4,5}, Javier P Gisbert^{6,7}, Jyh-Ming Liou⁸, Christian Schulz^{1,9}, Antonio Gasbarrini,¹⁰ Richard H Hunt,^{11,12} Marcis Leja^{13,14}, Colm O'Morain,¹⁵ Massimo Rugge^{16,17}, Sebastian Suerbaum,^{9,18} Herbert Tilg¹⁹, Kentaro Sugano²⁰, Emad M El-Omar^{21,22} On behalf of the European Helicobacter and Microbiota Study group

Malfertheiner P, Gut 2022 Online agosto 15

Management of epithelial precancerous conditions and lesions in the stomach (MAPS II): European Society of Gastrointestinal Endoscopy (ESGE), European *Helicobacter* and Microbiota Study Group (EHMSG), European Society of Pathology (ESP), and Sociedade Portuguesa de Endoscopia Digestiva (SPED) guideline update 2019













Authors

Pedro Pimentel-Nunes^{1,2,3}, Diogo Libânio^{1,2}, Ricardo Marcos-Pinto^{2,4}, Miguel Areia^{2,5}, Marcis Leja⁶, Gianluca Esposito⁷, Monica Garrido⁴, Ilze Kikuste⁶, Francis Megraud⁸, Tamara Matysiak-Budnik⁹, Bruno Annibale⁷, Jean-Marc Dumonceau¹⁰, Rita Barros^{11,12}, Jean-François Fléjou¹³, Fátima Carneiro^{11,12,14}, Jeanin E. van Hooft¹⁵, Ernst J. Kuipers¹⁶, Mario Dinis-Ribeiro^{1,2}

17 Patients with advanced stages of atrophic gastritis (severe atrophic changes or intestinal metaplasia in both antrum and corpus, OLGA/OLGIM III/IV) should be followed up with a high quality endoscopy every 3 years (low quality evidence, strong recommendation)

Management of *Helicobacter pylori* infection: the Maastricht VI/Florence consensus report

Peter Malfertheiner ,^{1,2} Francis Megraud ,³ Theodore Rokkas ,^{4,5}
Javier P Gisbert ,^{6,7} Jyh-Ming Liou ,⁸ Christian Schulz ,^{1,9}
Antonio Gasbarrini,¹⁰ Richard H Hunt,^{11,12} Marcis Leja ,^{13,14} Colm O'Morain,¹⁵
Massimo Rugge ,^{16,17} Sebastian Suerbaum,^{9,18} Herbert Tilg ,¹⁹
Kentaro Sugano ,²⁰ Emad M El-Omar ,^{21,22} On behalf of the European
Helicobacter and Microbiota Study group

Statement 20: Follow-up at regular intervals, and by use of endoscopic biopsy protocols, is mandatory in patients with severe atrophic gastritis (OLGA III/IV or OLGIM III/IV).

Agreement 97%

Grade B1

Malfertheiner P, et al. Gut 2022;71:1724-62

Metaplasia intestinal

RECOMMENDATION

15 Patients with IM at a single location have a higher risk of gastric cancer. However, this increased risk does not justify surveillance in most cases, particularly if a high quality endoscopy with biopsies has excluded advanced stages of atrophic gastritis.












Moderate quality evidence, strong recommendation (100% agree [82% strongly or moderately agree]).

Pimentel-Nunes P, Endoscopy 2019; 51: 365-88

16 In patients with IM at a single location but with a family history of gastric cancer, or with incomplete IM, or with persistent *H. pylori* gastritis, endoscopic surveillance with CE and guided biopsies in 3 years' time may be considered.

Low quality evidence, weak recommendation (82% agree [76% strongly or moderately agree]).

Management of *Helicobacter pylori* infection: the Maastricht VI/Florence consensus report

Peter Malfertheiner ,^{1,2} Francis Megraud ,³ Theodore Rokkas ,^{4,5}
Javier P Gisbert ,^{6,7} Jyh-Ming Liou ,⁸ Christian Schulz ,^{1,9}
Antonio Gasbarrini,¹⁰ Richard H Hunt,^{11,12} Marcis Leja ,^{13,14} Colm O'Morain,¹⁵
Massimo Rugge ,^{16,17} Sebastian Suerbaum,^{9,18} Herbert Tilg ,¹⁹
Kentaro Sugano ,²⁰ Emad M El-Omar ,²¹ On behalf of the European
Helicobacter and Microbiota Study group

Statement 13: The histological assessment of atrophy should result in a conclusive gastritis staging (OLGA/OLGIM), which consistently ranks the patient-specific cancer risk. **Histological staging makes IM subtyping clinically redundant.**

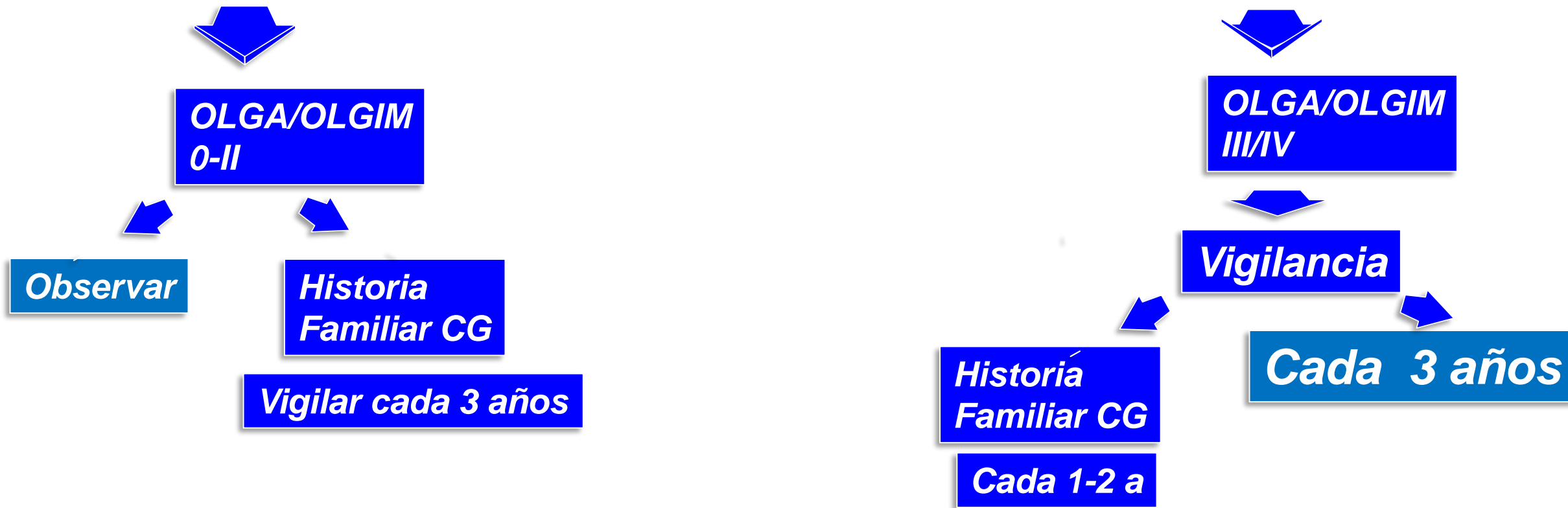
Agreement 97%

Grade A1

Malfertheiner P, et al. Gut 2022;71:1724–62

Vigilancia de Gastritis Crònica

5 Biopsias: cuerpo (2), Antro (2), Incisura (1)



Sugano K, Kyoto Consensus. Gut 2015; 64:1353-67

Zagari RM, Dig Liver Dis 2015;903-12

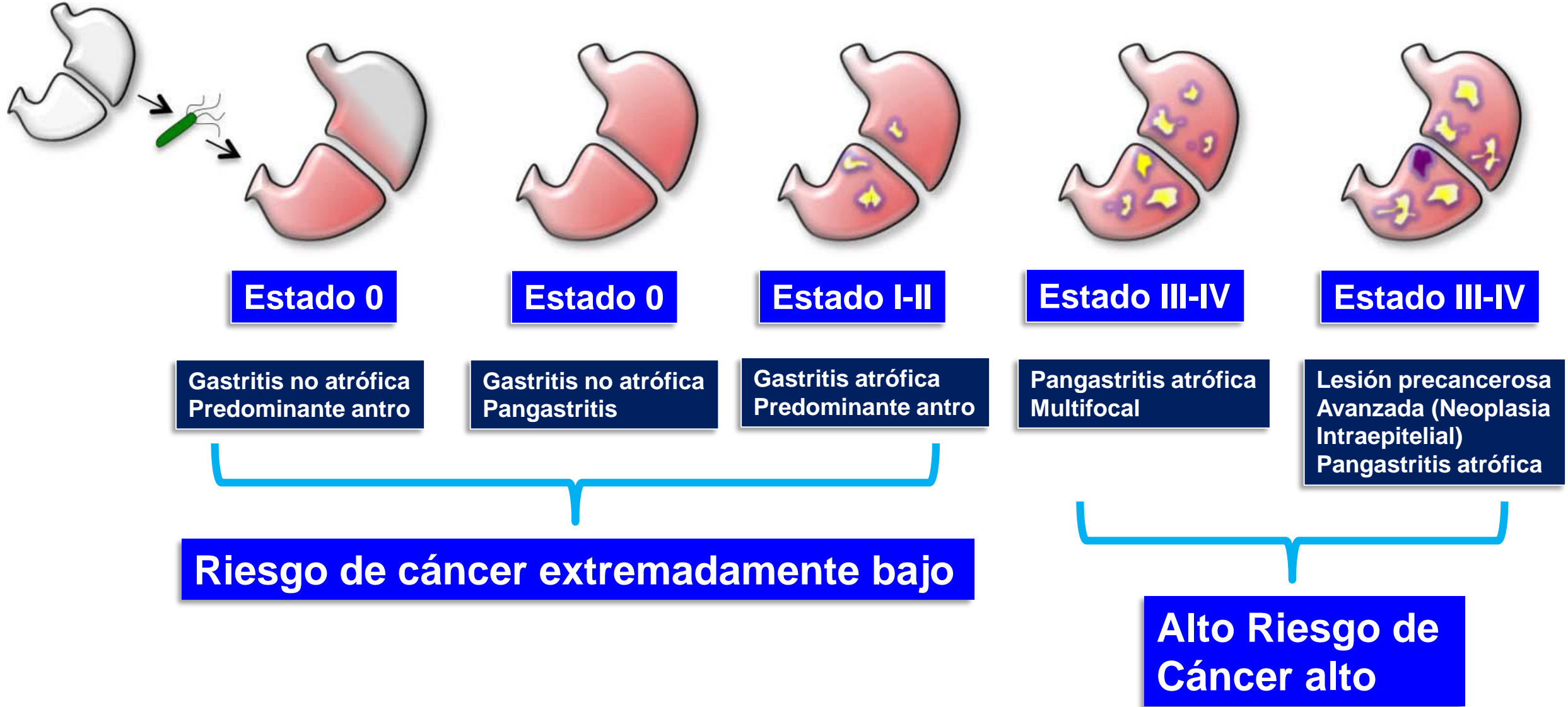
Rollán A, Rev Med Chile 2014;142:1181-92

Yue H, Gastric Cancer 2018;21:579-87

Shah SC Gastroenterology 2021;161:1325-32

Pimentel-Nunes P, Endoscopy 2019;51:365-88

Tiempo



Risk assessment of metachronous gastric cancer development using OLGA and OLGIM systems after endoscopic submucosal dissection for early gastric cancer: a long-term follow-up study

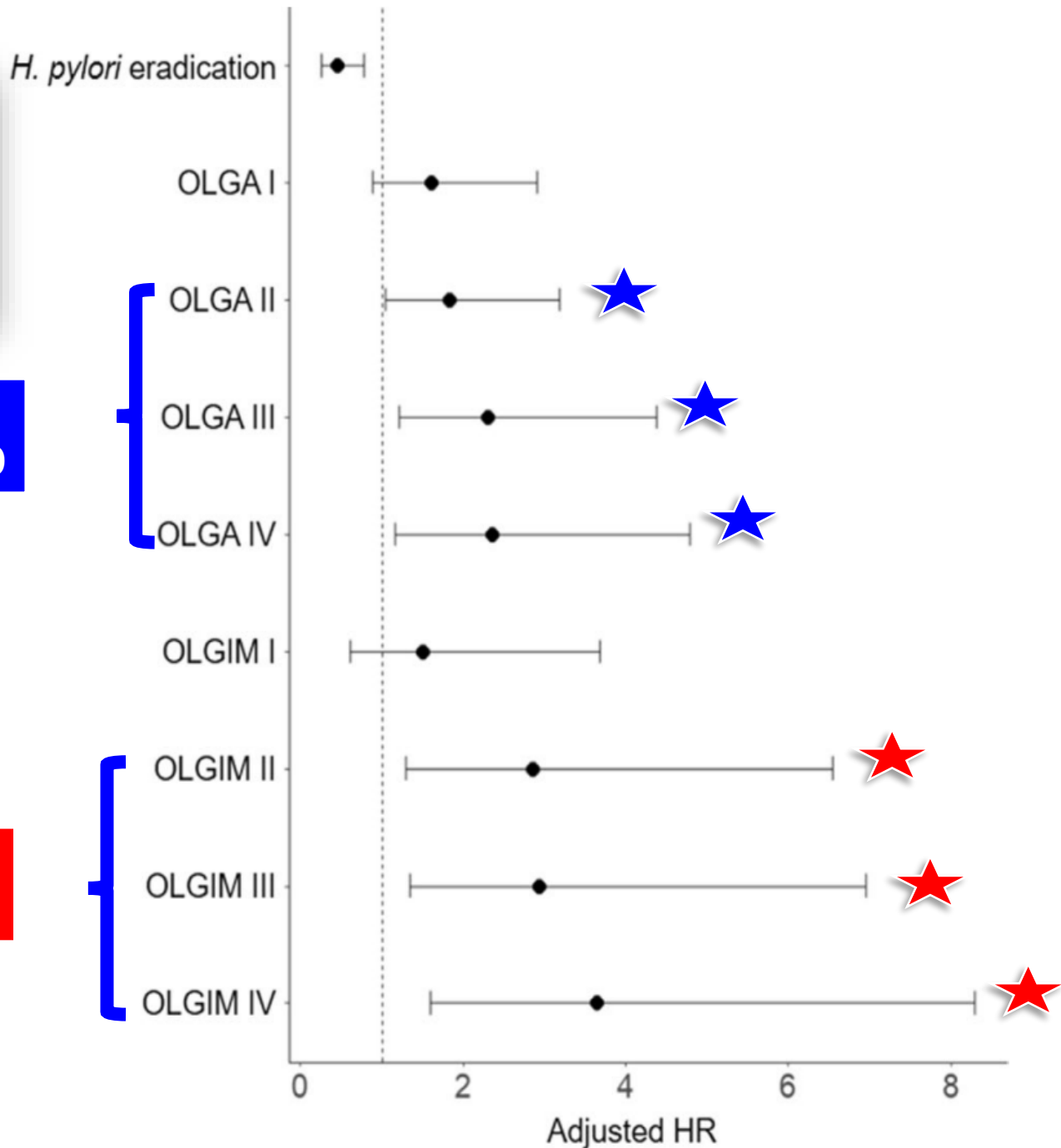
Yun Suk Na¹ · Sang Gyun Kim¹ · Soo-Jeong Cho¹ 

**916 pacientes seguidos
2005-2015-
Seguimiento 94 meses
120 CG metacrónico**



**OR 1.83
IC95% 1.05-3.19**

**0-II 4.5%
III-IV: 11.8%
P=0.02**

**OR 2.86
IC95%1.29-6.54**



Endoscopic grading of gastric intestinal metaplasia on risk assessment for early gastric neoplasia: can we replace histology assessment also in the West?

Pedro Marcos ,^{1,2} Gisela Brito-Gonçalves,³ Diogo Libânio,^{1,4} Inês Pita,¹ Rui Castro,¹ Inês Sá ,¹ Mário Dinis-Ribeiro,^{1,4} Pedro Pimentel-Nunes^{1,4,5}

OLGIM, OLGA

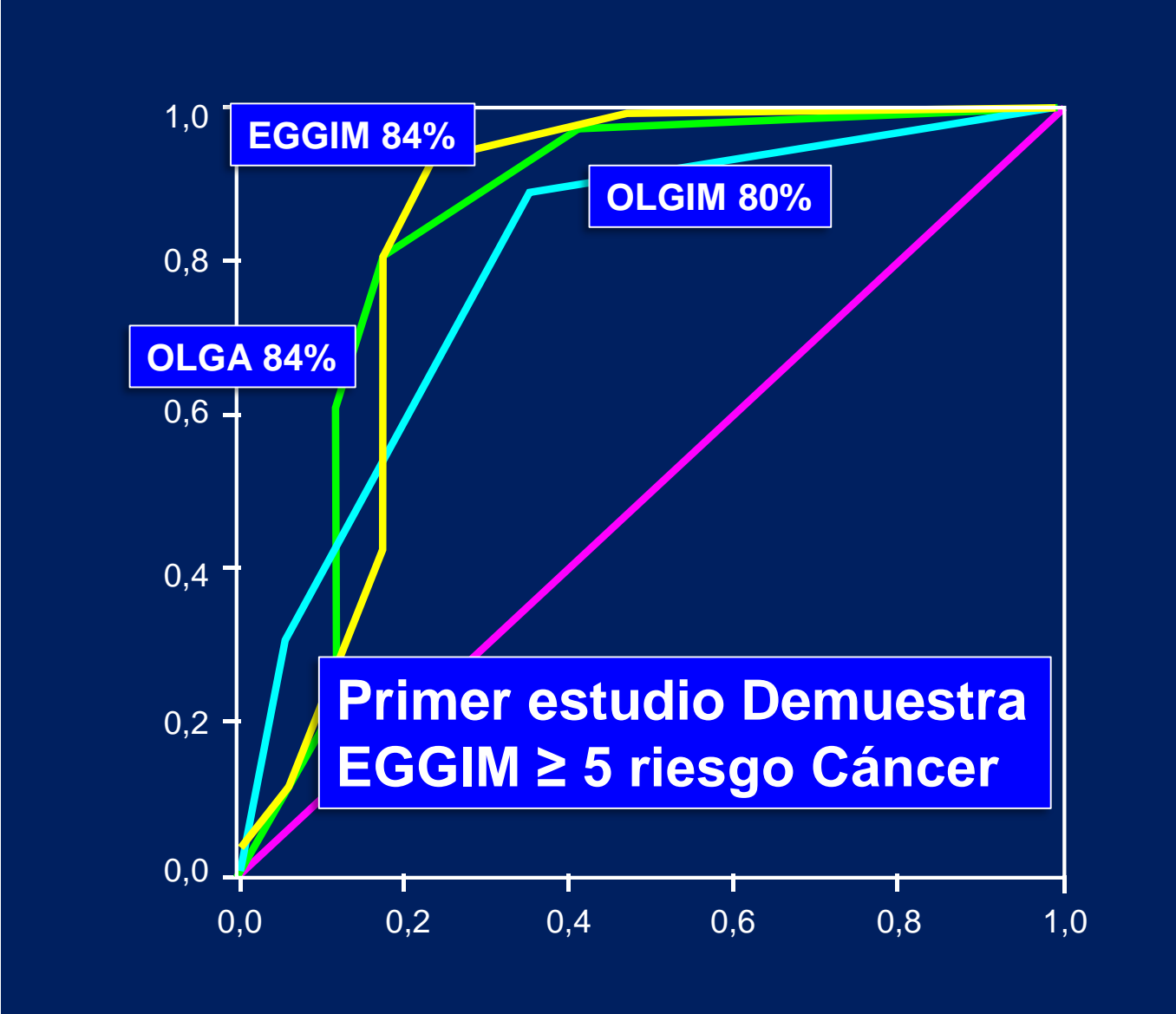
EKGIM: Graduación endoscópica Metaplasia intestinal

Antro C>, C<, Cuerpo C>, C<, Incisura: estaciones de Sídney

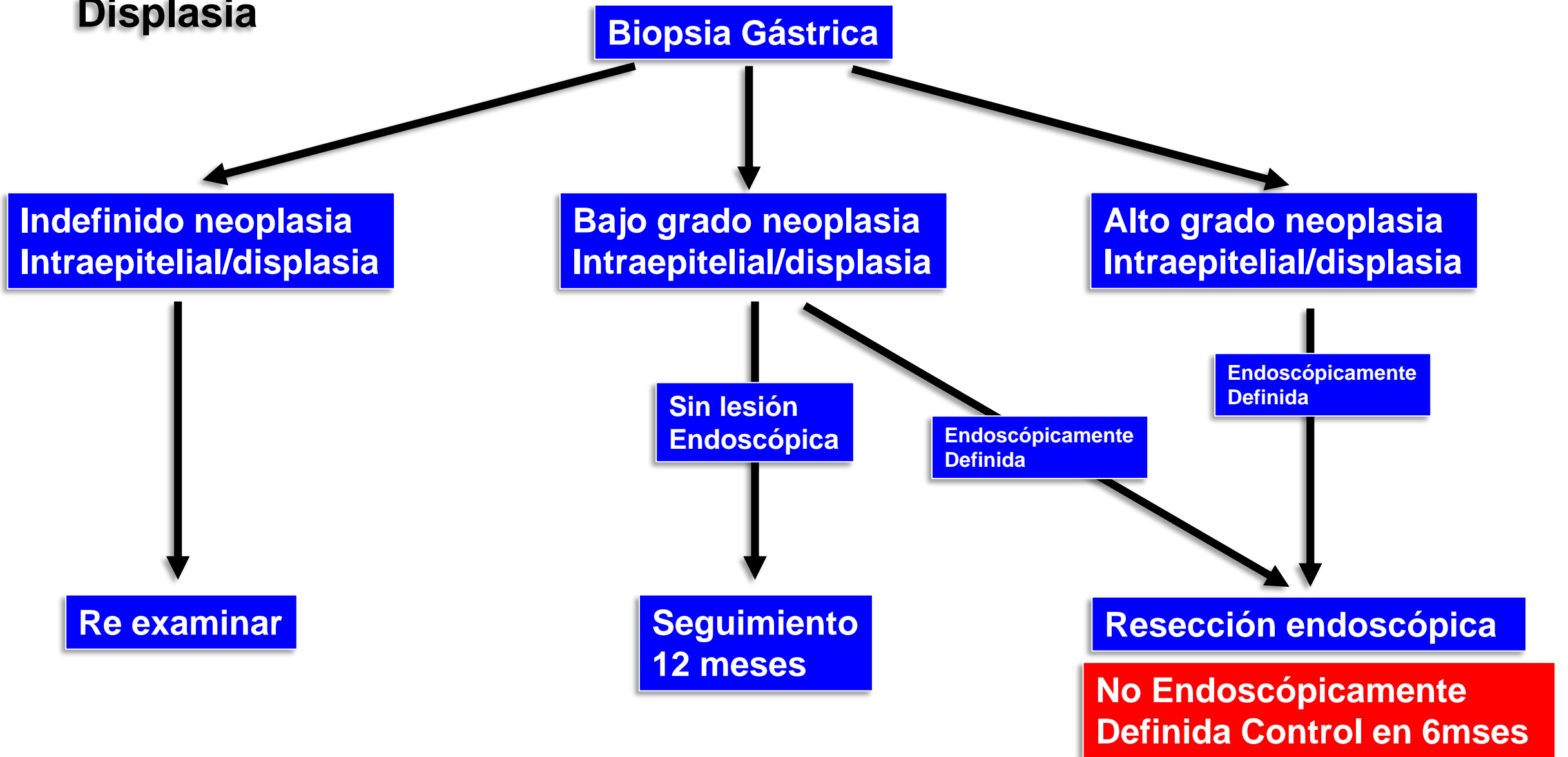
Cada sitio 0-2 puntos

0=no MI, 1: MI(focal) <30%, 2: MI Extensa ≥ 30%

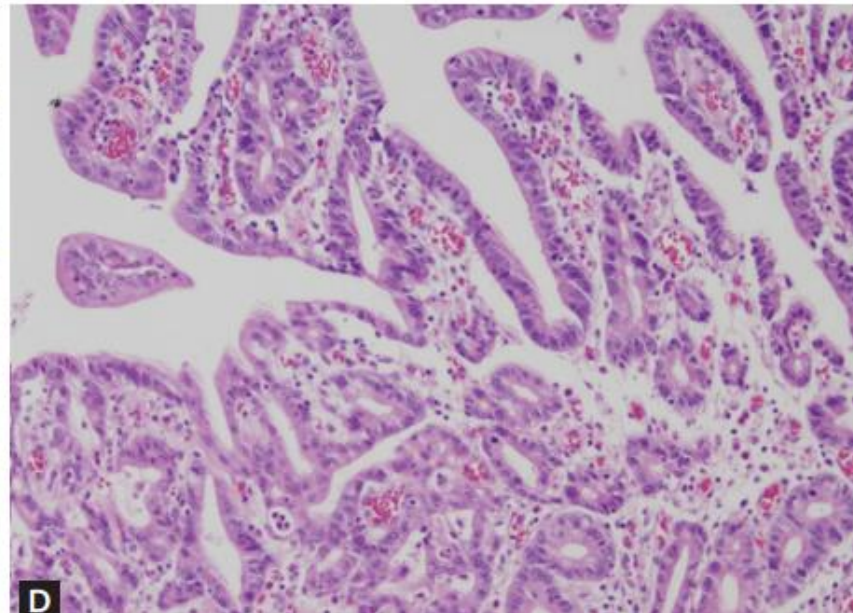
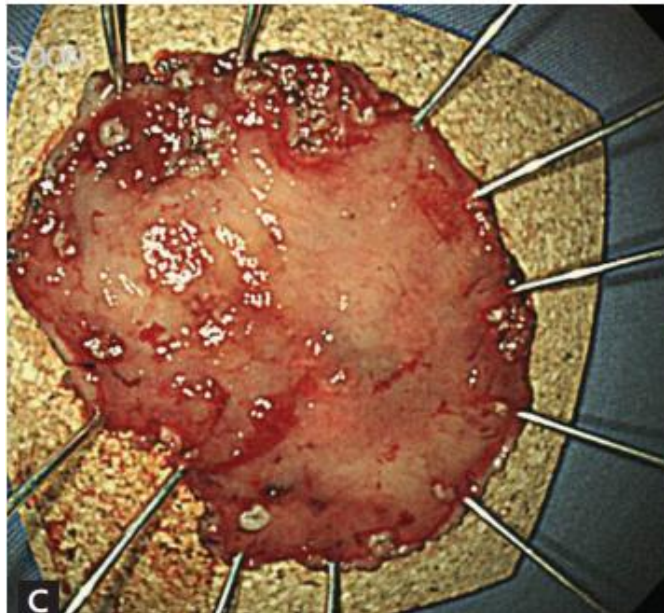
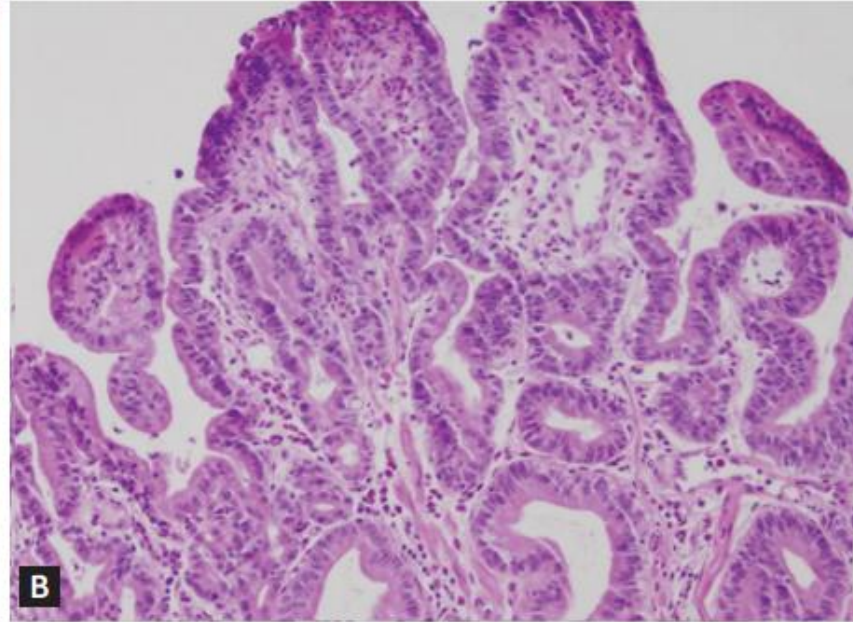
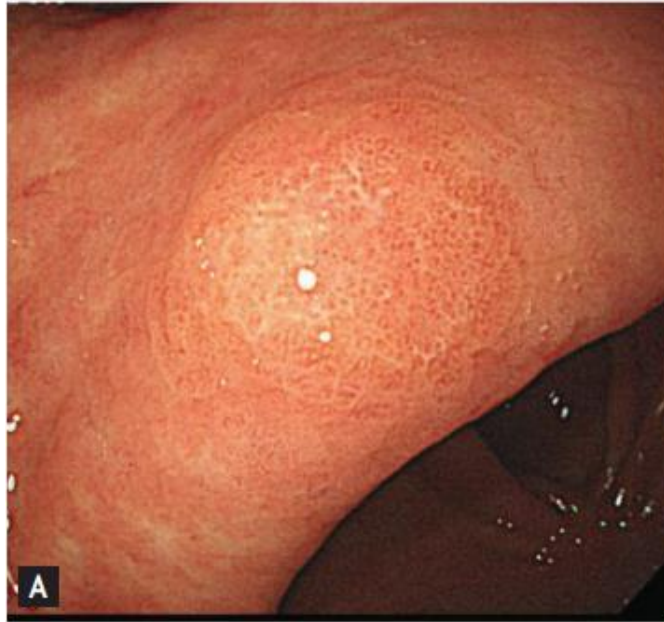
EGGIM Occidente



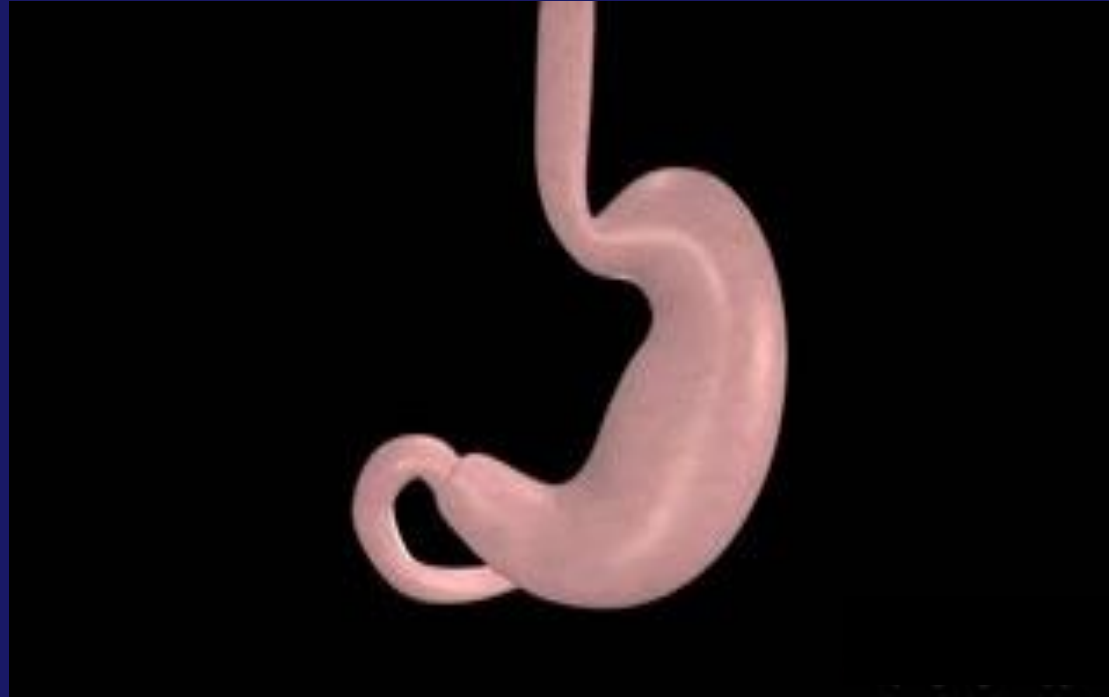Displasia



Displasia Gástrica



Gastritis autoinmune



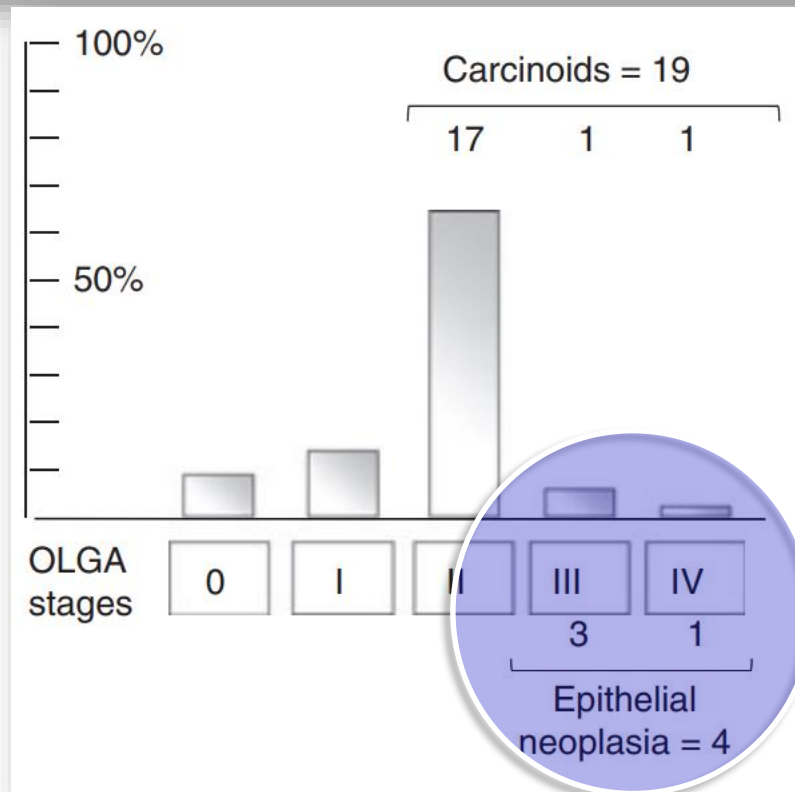
Vigilar c/3- 5años

Tumores neuroendocrinos




Pimentel-Nunes P, Endoscopy 2019; 51: 365-88
Shah SC, Gastroenterology 2021;161:1325-32

Autoimmune gastritis: histology phenotype and OLGA staging

M. Rugge^{*,†,1}, M. Fassan^{*,‡,1}, M. Pizzi[‡], V. Zorzetto[‡], G. Maddalo[‡], S. Realdon[†], M. DeBernard[§], C. Betterle^{*}, R. Cappellesso^{*}, G. Pennelli^{*}, M. de Boni[¶] & F. Farinati[‡]



Autoimmune gastritis: long-term natural history in naïve *Helicobacter pylori*-negative patients

Massimo Rugge ,^{1,2} Ludovica Bricca,¹ Stefano Guzzinati,² Diana Sacchi,³ Marco Pizzi,¹ Edoardo Savarino,³ Fabio Farinati,³ Manuel Zorzi ,² Matteo Fassan,^{1,4} Angelo Paolo Dei Tos,¹ Peter Malfertheiner,⁵ Robert M Genta,^{6,7} David Y Graham ⁷

WHAT ARE THE NEW FINDINGS?

⇒ When previous or current *H. pylori* infection is rigorously excluded, the long-term follow-up of AIG does not reveal any excess risk for malignancy, except for thyroid cancers. In the

HOW MIGHT IT IMPACT ON CLINICAL PRACTICE IN THE FORESEEABLE FUTURE?

⇒ In naïve *H. pylori*-negative patients, neuroendocrine neoplasia, not GC secondary prevention, prioritises the clinical, endoscopic and histopathological surveillance of AIG.



Management of upper gastrointestinal symptoms in patients with autoimmune gastritis

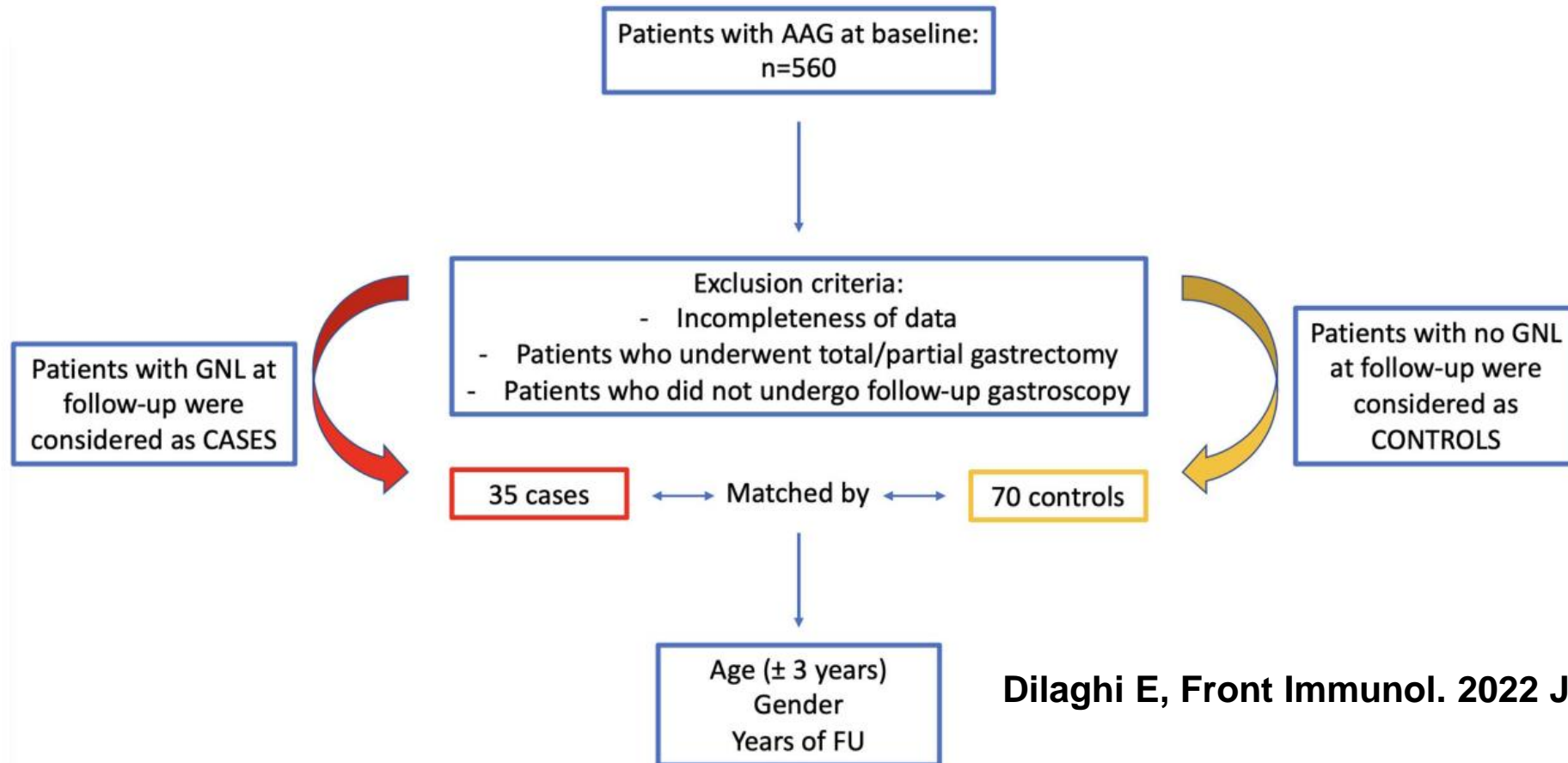
Juan D. Gomez Cifuentes^a, Jordan Sparkman^b and David Y. Graham^c

Tumores Neuroendocrinos Tipo I (Hipergastrinemia)

Gómez JD, Curr Opin Gastroenterol 2022;38:600-6

The Impact of Proton Pump Inhibitors on the Development of Gastric Neoplastic Lesions in Patients With Autoimmune Atrophic Gastritis

Emanuele Dilaghi[†], Mario Bellisario[†], Gianluca Esposito, Marilia Carabotti, Bruno Annibale[†] and Edith Lahner^{*†}



	Cases n=35	Controls n=70	p-value
Females	20 (57.1)	42 (60.0)	NS (matched)
Median age, years, median (range)	67.6 (44–84)	67.7 (42–86)	NS (matched)
Age >50 years	32 (91.4)	65 (92.9)	NS (matched)
Prior use of PPIs	19 (54.3)	13 (18.6)	<0.001
Body mass index ≥25	17 (48.6)	26 (37.1)	0.297
Smoking habit	4 (11.4)	34 (48.6)	<0.001
First-degree family history for gastric cancer	3 (8.6)	7 (10.0)	1.000
Dyspepsia	17 (48.6)	28 (40.0)	0.412
Use of antiplatelet or anticoagulant drugs	14 (40.0)	11 (15.7)	0.008
Iron deficiency anemia	4 (11.4)	13 (18.6)	0.412
Pernicious anemia	13 (37.1)	28 (40.0)	0.834
Severe corpus atrophy	13 (37.1)	27 (38.6)	1.000
Presence of corpus intestinal metaplasia	26 (74.3)	58 (82.9)	0.312

Management of upper gastrointestinal symptoms in patients with autoimmune gastritis

Juan D. Gomez Cifuentes^a, Jordan Sparkman^b and David Y. Graham^c

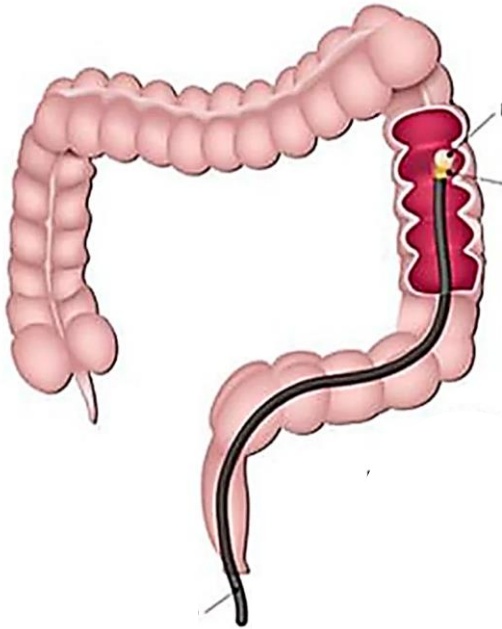
KEY POINTS

- The most common symptoms in autoimmune gastritis (AIG) are dyspepsia and typical gastroesophageal reflux (GERD) symptoms.
- Typical GERD symptoms are caused by weakly acid and alkaline reflux, the exact mechanism behind dyspepsia is unknown.
- Acid suppressant medications should be discontinued as their physiologic targets are absent in AIG patients.
- Therapy for AIG patients should be approached based on the predominant symptoms of GERD and dyspepsia.

Otras estrategias de prevención secundaria

Statement 18: Screening modalities for gastric cancer prevention (noninvasive or endoscopic) combined with colorectal cancer screening is an opportunity

Agreement 81%



A los 50 años

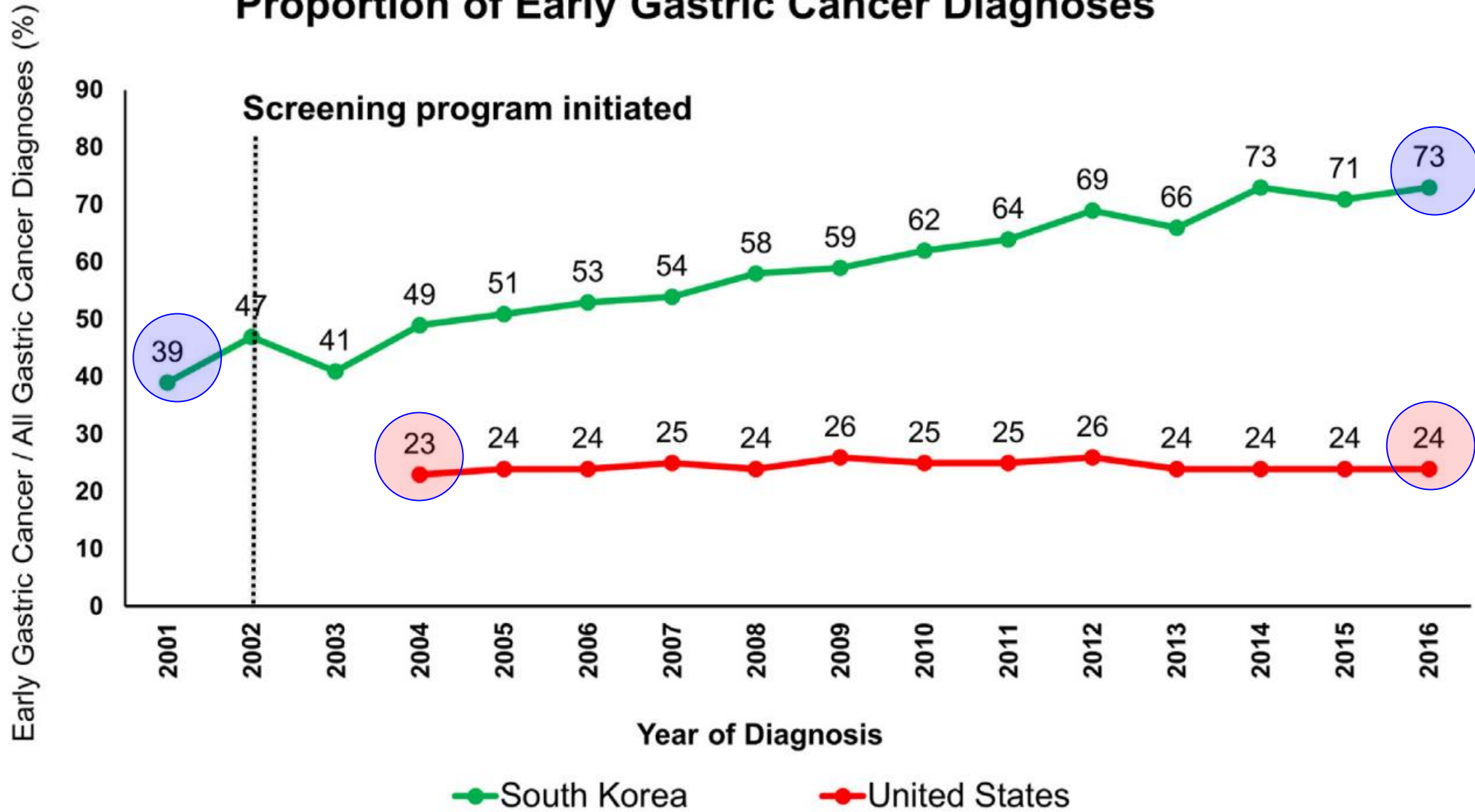
Atrofia, MI avanzada

**10% *H.pylori* +
19% Europa**

Grade C2



Proportion of Early Gastric Cancer Diagnoses



Maastricht VI

by these means.⁴⁰⁰ Eradication therapy should be offered to all *H. pylori* positive patients² combined with upper GI endoscopy for all patients with positive serologic biopsy (pepsinogen I/II < 3 and/or pepsinogen I < 30 µg/L). Regular endoscopic surveillance should be offered to those with OLGA/OLGIM II-IV stage as recommended by MAPPS II guidelines.⁸⁹

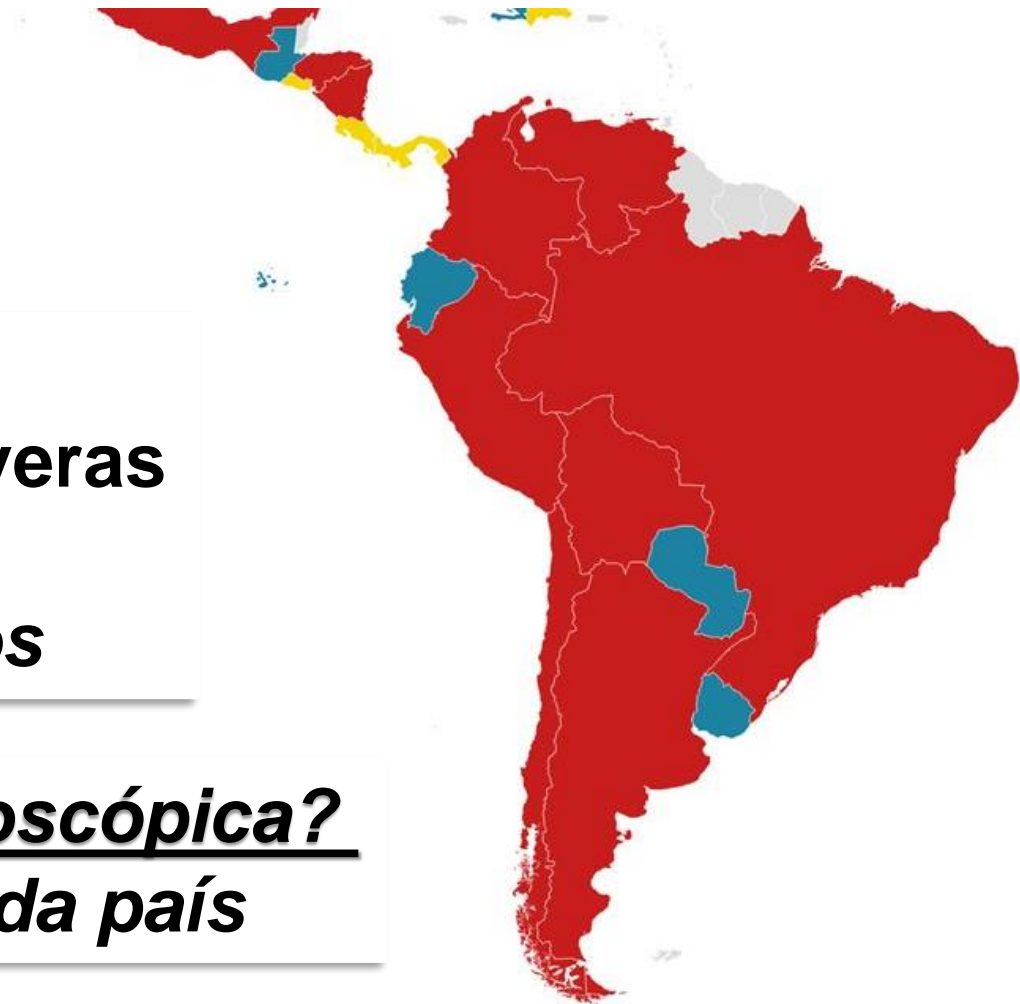Mensajes para la casa

Prevención Cáncer Gástrico LATAM?

Prevención primaria
Erradicando *H.pylori*

Prevención secundaria
Vigilando Atrofia/MI severas
OLGA/OLGIM
Endoscopios avanzados

Tamización endoscópica?
Estudiarlo en cada país



**Endoscopios
Avanzados**

**Inteligencia
Artificial**



**Biopsias
Sìdney**

Muchas gracias!

